

Infrarenal Abdominal Aorta Approach through Median Minilaparotomy

G.V. Pătruț¹, L.P. Jiga¹, G.P. Tăranu¹, A. Rata¹, C. Neamtu², M. Ionac¹

¹Department of Vascular Surgery and Reconstructive Microsurgery, Clinical Emergency County Hospital, Timișoara, Romania

²Department of Anesthesiology and Intensive Care, Clinical Emergency County Hospital, Timișoara, Romania

Rezumat

Abordul aortei abdominale infrarenale prin minilaparotomie mediană

În mod clasic, expunerea aortei infrarenale se realizează prin laparotomie xifo-pubiană sau xifo-subombilicală, în cazul abordului transperitoneal, sau prin incizie la nivelul hemi-abdomenului stâng, în cazul abordului retroperitoneal. Abordul transperitoneal este asociat imediat postoperator cu timp mai lung de reluare a tranzitului intestinal și la distanță cu eventrații, datorită exteriorizării intraoperatorii a anselor intestinale, respectiv a lungimii inciziei. Aceste dezavantaje dispar prin abordul laparoscopic, dar această metodă este extrem de laborioasă, comportă un timp de disecție prelungit și o dificultate sporită în realizarea anastomozelor pe aortă. Scopul studiului este de a evalua abordul aortei abdominale infrarenale prin minilaparotomie mediană, o metodă care combină expunerea excelentă din abordul xifo-pubian cu morbiditatea scăzută a abordului laparoscopic. În perioada 01.07.2010 – 01.07.2011, în clinica noastră, au fost realizate 37 intervenții de revascularizare la 36 de pacienți cu boală ocluzivă aorto-iliacă (un pacient a necesitat reintervenție datorită trombozei grefonului în evoluție) abordându-se aorta abdominală infrarenală prin minilaparotomie mediană. Repartiția pe sexe a fost de 35 bărbați și o femeie. Vârsta

medie a lotului a fost de 61,1 ani. S-au realizat 25 bypassuri aorto-bifemorale, 11 bypassuri aorto-unifemorale și un bypass aorto-biiliac. Timpul mediu de clampare a aortei a fost de 15 minute. Timpul operator mediu a fost de 150 minute. S-au folosit 26 proteze bifurcate Dacron și 11 proteze liniare ePTFE. Timpul mediu de reluare a tranzitului intestinal a fost de 32 ore. Toți pacienții incluși în studiu s-au mobilizat la 24 ore postoperator. Durata medie a spitalizării a fost de 7,7 zile. 5 pacienți au prezentat complicații pe perioada internării și 3 pacienți au suferit complicații la distanță. Abordul aortei abdominale infrarenale prin minilaparotomie mediană reprezintă o alternativă viabilă la tehnicile operatorii clasice folosite în boala ocluzivă aortoiliacă.

Cuvinte cheie: minilaparotomie mediană, aorta abdominală, bypass aorto-femural

Abstract

Classically, infrarenal aortic exposure is achieved by xypho-pubic or xypho-infraumbilical laparotomy, in transperitoneal approach, or through a left abdominal incision, in retroperitoneal approach. The transperitoneal approach is associated with longer intestinal activity resumption time and incisional hernias on long term, due to intestinal extracavitary mobilization and long incision. These disadvantages disappear in laparoscopic approach, but this method is extremely laborious, requires an extended period for dissection, and elicits increased difficulty in performing the anastomosis on the aorta. The purpose of the study is to evaluate the infrarenal abdominal aorta approach through median minilaparotomy, a method that combines the excellent exposure of xypho-pubic incision with the low morbidity of laparoscopic approach. Between

Corresponding author:

George V. Pătruț, PhD
Department of Vascular Surgery and
Reconstructive Microsurgery,
Clinical Emergency County Hospital
Timișoara, Romania
E-mail: georgepatrut@yahoo.com

07.01.2010 - 07.01.2011, we performed 37 revascularization surgeries in 36 patients with aorto-iliac occlusive disease (one patient required reintervention due to graft thrombosis), approaching the infrarenal aorta through median minilaparotomy. The sex distribution was 35 men and one woman. The average age was 61.1 years. There have been 25 aorto-bifemoral bypasses, 11 aorto-unifemoral bypasses, and one aorto-biiliac bypass. The mean aorta clamping time was 15 minutes. Average operating time was 150 minutes. We used 26 bifurcated Dacron prostheses and 11 linear ePTFE prostheses. The average intestinal activity resumption time was 32 hours. All patients included in the study were mobilized 24 hours after surgery. The average length of hospitalization was 7.7 days. 5 patients experienced complications during hospitalization and 3 patients suffered long term complications. Infrarenal abdominal aorta approach through median minilaparotomy is a viable alternative to conventional surgical techniques used in aortoiliac occlusive disease.

Key words: median minilaparotomy, abdominal aorta, bypass

Introduction

The classical approach to the infrarenal abdominal aorta consists of two methods: transperitoneal, involving a xypho-pubic skin incision, opening of the peritoneal cavity, extra-peritoneal bowel retraction and retroperitoneal dissection, and retroperitoneal, through an incision in the left abdominal wall. Despite the accurate anatomical exposure, these techniques have several disadvantages, including prolonged operative time, prolonged time for bowel movement recovery, dissection and anastomosis difficulties, prolonged hospital stay, long time complications (eventration) (1,2,3,4,5,6). On the other hand, the laparoscopic approach, although associated with low morbidity, involves specific difficulties in infrarenal aortic dissection and synthetic graft anastomosis at this level (6,7,8,9,10,11). Consequently, despite modern laparoscopic equipment and endoscopic techniques, most surgeons prefer the endovascular techniques, when indicated as minimally invasive approach, because of a shorter learning curve (6). On the other hand, endovascular techniques are associated with low patency rates and high rates of reintervention. The mini-laparotomy median approach was suggested for the open surgery, combining the advantages of classical approaches (fast exposure, fast dissection, safety) with those of laparoscopic and endovascular techniques (low morbidity, fast recovery, short hospital stay) (6). Our study aims at evaluating the safety, efficacy, complication rate and technical characteristics of this method.

Material and Method

Between 01.07.2010 and 01.07.2011, 37 median mini-

laparotomies were performed on 36 patients with aorto-iliac peripheral arterial disease in our clinic.

Preoperative prepping

Preoperative prepping consisted of blood work (cell blood count, CHEM 7, lipid profile and coagulation parameters), functional exams (ECG, chest X-Ray, cardiologic evaluation), 12 hours preoperative fasting and evacuation enema. Patients on long-term oral blood thinners had their medication replaced with low molecular weight heparin (Nadroparinum, 3800 UI anti-factor Xa/0,4 ml twice daily). Antiplatelet medication (other than acetylsalicylic acid), was stopped 7 days prior to surgery (12,13,14). All patients were administered preoperatively cyclooxygenase inhibitors, antiplatelet medication (12,13,14) (75 mg/day aspirin), statins (15), heart and anti-diabetic medication. Low molecular weight heparins were used for the prevention of deep vein thrombosis (Nadroparinum, 3800 UI anti-factor Xa/0,4 ml, one daily), stopped 12 hours preoperatively (16,17).

Anesthesia

Anesthesia was general with endo-tracheal intubation in all cases, associated with catheter continuous epidural. All patients had a Foley catheter, naso-gastric catheter, two venous and one arterial line (the last one for invasive blood pressure monitoring). Antibiotic prophylaxis was made with Cefazolinum 1 g, 30 minutes prior the first incision (18,19).

Operative technique

The patient was placed in supine position, on a thermal mattress (20), preset at 38 degrees, with a polyurethane foam pillow placed under the lumbar region for a slightly lumbar extension. The operating field was covered in Ioban® type sterile strip. A median abdominal 10 cm skin incision was performed, 1/3 infra-umbilical and 2/3 supra-umbilical. After white line incision one enters into the peritoneal cavity, covers the intestinal folds with gauzes placed intracavitary. 2 gauzes are placed initially – one in the right side and the other cranial for the coverage of the small bowel, caecum, ascending and transverse colon. Another gauze is placed on the left side, dressing the descending colon and another one placed caudally in order to cover the sigmoid colon. The intestinal folds and the surgical margins are retracted using a Kirshner or Thompson abdominal retractor, thus exposing the posterior parietal peritoneum (Fig. 1). The next step is represented by the dissection of the infrarenal aorta, with the retraction of the retroperitoneal fat tissue with and Adson autostatic retractor (Fig. 2). The pulsation of the inferior mesenteric artery is controlled by hand, and if chronically occluded it is ligated and cut. After the exposure of the femoral arteries, systemic heparinization is performed (70 UI/Kgc) and a retroperitoneal synthetic graft is placed. In all cases, the aorta was clamped distally from the left renal vein and 1 cm above the bifurcation with aortic clamps (Ochsner or Cooley). The aortic anastomosis was performed with taperpoint Surgipro® 4.0 wire, Johnsons & Johnson, SUA. After the performance of the distal

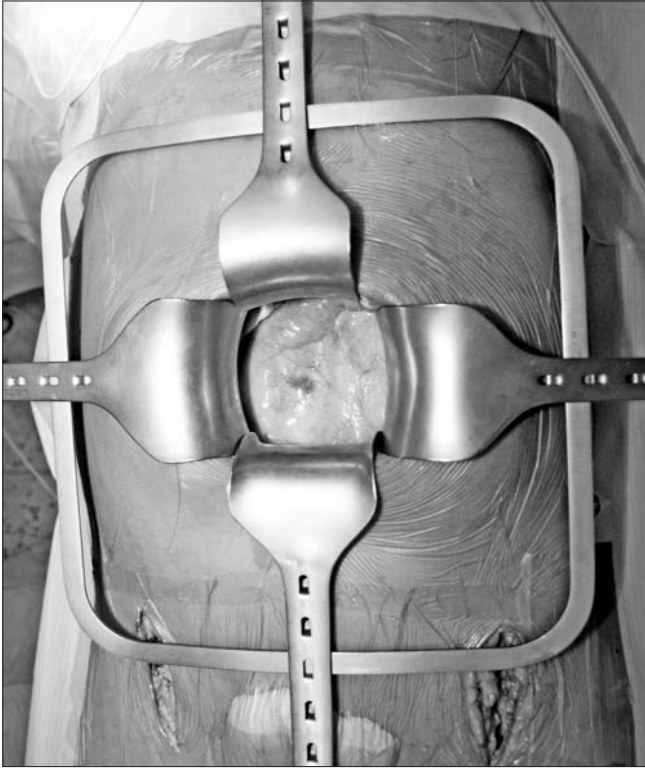


Figure 1. Retraction of intestinal folds and retroperitoneal exposure

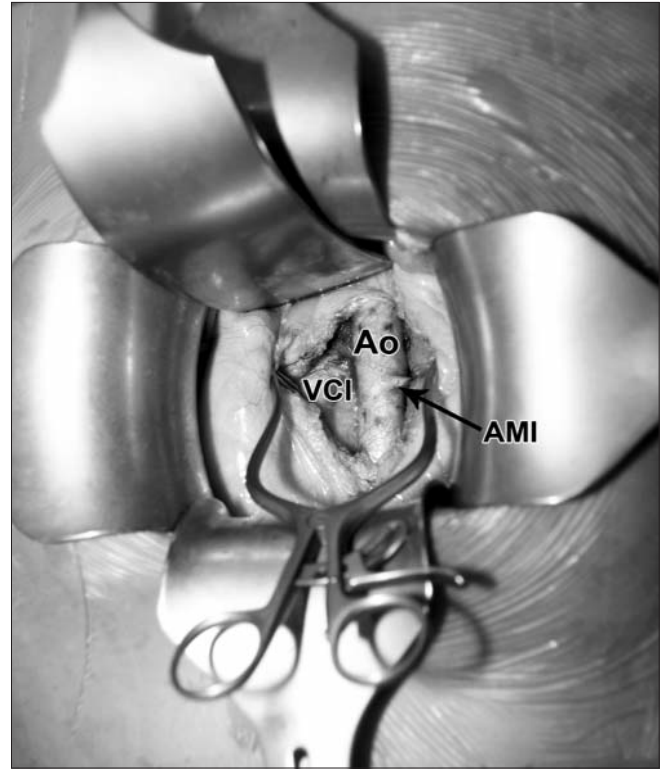


Figure 2. Infrarenal abdominal aorta exposure (Ao – aorta, AMI – inferior mesenteric artery, VCI – inferior vena cava)

anastomosis and the revascularization procedures, we practiced hemostasis, drainage and wound closure. We didn't place abdominal drainage.

Postoperative management

Immediately after surgery (after extubation), the nasogastric catheter is removed and the patients are transferred back to the surgical ward. For the first 24 hours, they are monitored invasively (blood pressure, heart rate, SO_2 , urine output). Prophylactic antibiotherapy was continued 24 hours postoperatively using 2nd generation cephalosporins (Cefazolin 1000 mg twice daily). Supportive medication was administered: antalgic (Metamizol 2x2 vials daily), anti-inflammatory (Dexketoprofen 50 mg 2x1/day), antispastic (Drotaverina 40 mg 2x2/day), antiemetic (Metoclopramid 10 mg 2x1/day), antacid (Ranitidinum 50 mg 2x2/day). This therapeutic protocol was continued 48 hours postoperatively. Anticoagulation was initially achieved through low molecular weight heparins (Nadroparinum, 3800 UI anti-factor Xa/0,4 ml, twice daily) and once the bowel movement was restored, with oral blood thinners (Acenocumarolum, 4 mg), under INR control (optimum value between 2 and 3). Antiplatelet therapy was also administered (Acetylsalicylic acid, 75 mg daily). For a rapid restoration of the bowel movement, the patients were advised to drink cold water and coffee the next morning after the surgery. Patients were mobilized the second day after surgery.

Results

Gender distribution was 35 males to one female. The median age was 61 years old, ranging between 43 and 80 years old. The patients presented the following risk factors: smoking – 82%, arterial hypertension – 65%, dyslipidemia – 73% and 41% diabetes mellitus. 26 bifurcated Dacron grafts, impregnated with collagen, InterGard® France (24 – 14/7 mm and 2 – 12/6 mm) and 11 ePTFE 7 mm linear graft heparin-bonded (Impra Carboflo®, Germany) were used.

Surgery

In 25 patients (69%) an aorto-bifemoral bypass was performed, in 10 patients (28%) – aorto-femoral and in 1 patient (3%) aorto-biiliac. Supplemental revascularization procedures in one or both limbs were performed in 47% of the patients; 10 patients (28%) needed an endarterectomy, 1 (3%) needed a superficial femoral angioplasty, 7 patients (19%) needed an infra-inguinal extension and 1 patient required an aorto-renal bypass. The detailed list of procedures is presented in *Table 1*. The median operative time for aorto-femoral/aorto-bifemoral bypass (not including revascularization procedures) was 150 minutes. Including supplemental procedures, the medium time was 280 minutes. The aorta was clamped for a median time of 15 minutes, ranging between 11 and 25 minutes.

2 intraoperative complications occurred – distal

Table 1. Supplemental revascularization interventions (IASG = inverted autologous saphenous graft, ePTFE = expanded polytetrafluoroethylene graft)

Intervention type	Patients no	Graft
Common femoral artery endarterectomy	8	-
Ring dissector endarterectomy superficial femoral artery	2	-
Angioplasty femoral superficial artery, medium thigh	1	IASG
Femoral-popliteal bypass	2	IASG
Femoral-peroneal bypass	1	IASG
Femoral-tibial posterior bypass	2	IASG
Femoral-popliteal-tibial posterior sequential bypass	1	IASG
Prosthetic graft – deep femoral artery bypass	1	ePTFE
Aorto-renal bypass	1	ePTFE

embolization, with atherosclerotic material, requiring a Fogarty catheter embolectomy.

Complications

Early postoperative complications during hospital stay were noted in 5 patients (16%). 4 patients (11%) presented tachycardia, hyperglycemias, atrial fibrillation with acute pulmonary edema and bowel incontinence (treated with Thiogamma 2x20 ml daily with restoration of sphincter control after 7 days). Only one patient developed necrotic skin lesions at the level of the abdominal incision, which was treated by applying povidone-iodine ointment.

Postoperative evolution

Postoperative evolution was generally favorable. In 6 patients (16%) the bowel movement was restored 12 hours postop, in 20 patients (56%) 24 hours postop. In 8 patients (22%) 36 hours postop and in 2 patients (6%) 48 hours postop. All patients were mobilized 24 hours postoperatively. The median hospital stay was 7.7 days, ranging from 4 to 20.

One patient who didn't comply with anticoagulant treatment developed aorto-femoral graft thrombosis 5 months postoperatively. This patient was retreated by performing a new aorto-femoral bypass. Two patients, diagnosed preoperatively with chronic obstructive pulmonary disease, developed eventration at 6 and 8 months postoperatively (treated surgically by abdominal wall reinforcement).

Perioperative mortality was 0. There was only one death, in a patient with myocardial infarction at 5 months postoperatively.

Discussions

Concerning intraoperative distal embolization, a ring dissector endarterectomy at the level of the superficial femoral artery was performed in both patients. In these cases it can be assumed that the source of emboli was represented by the atheroma plaque remnant in the superficial femoral artery after

endarterectomy, not of aortic origin. One patient developed cauda equina syndrome during hospital stay suffering from urinary and bowel incontinence. The CT-scan showed a retroperitoneal hematoma compressing the sacral plexus. He was treated with neurotrophic medication (Thiogamma) for 30 days, with restoration of sphincterian control 7 days later.

Although literature data indicate that preoperatively enema delays bowel movement restoration (21), it is our opinion that it is necessary in order to decrease bowel volume for an easier intestinal retraction. General anesthesia with endo-tracheal intubation, associated with epidural catheter maintains adequate cerebral perfusion, protects cardiac and pulmonary function, increases peripheral perfusion and ensures adequate pain control. The disadvantages of general anesthesia are: hypotension at clamp removal, increased liquid input and urinary retention (20,22).

The reduced size of the abdominal incision (Fig. 3) decreases healing time and minimizes the risk of wound infections. The median hospital stay was 7.7 days, which is similar to that from U. Alpagut's study from 2003 (1), but a little higher than that of U. Acikel from 1998 (23) (4.7 days) and T. Klokocovnik from 2001 (24) (6 days). Postoperative pain intensity is low and responds well to non-opioid analgesics. Reduced mobilization of intestinal folds and extraperitoneal retraction contribute to faster restoration of bowel movement, with minimal ileus. 72% of our patients return to normal feeding 24 hours postoperatively, which is similar to previously cited studies (1,23,24). Infrarenal abdominal aortic exposure is highly adequate and it provides excellent condition when performing the anastomosis within 150 minutes total operating time and 15 minutes of aortic clamping, similar to literature data (1,2,23,25,26). Due to the decreased length of

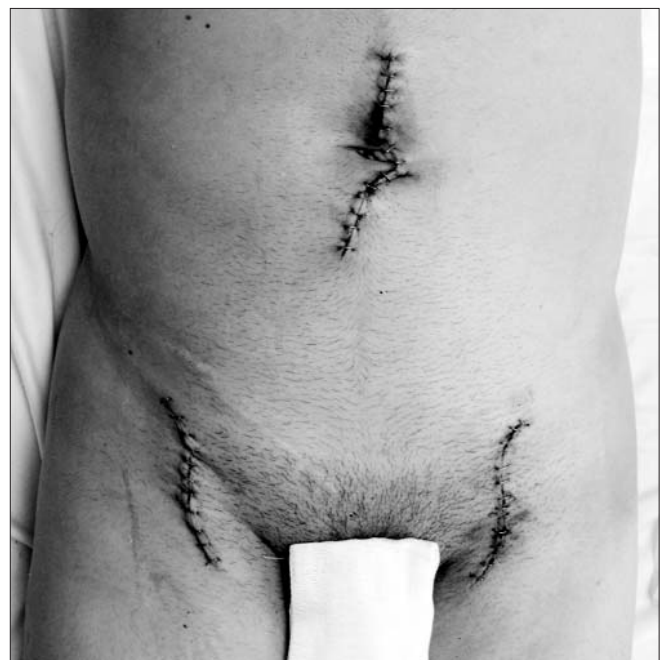

Figure 3. Postoperative image

the skin incision, especially in obese patients, graft placement may incur some difficulties. Early mobilization at 24-48 hours postoperatively and a median hospital stay of 7.7 days allow the patients to return to their usual activities sooner, thus decreasing the healthcare costs.

Conclusions

The minilaparotomy approach in infrarenal abdominal aortic surgery is a viable alternative to the classical xypho-pubian approach. This method combines the advantages of laparoscopic procedures, concerning recovery time and healthcare costs with the results of classic open surgery.

References

- Alpagut U, Kalko Y, Basaran M, Dayioglu E. A comparison between minilaparotomy and standard median laparotomy for reconstruction of aorto-iliac occlusive disease. *Acta Chir Belg.* 2003;103(2):208-11.
- Weber G, István M, Tóth GA, Horváth OP, Jakó GJ. A randomized comparison between minilaparotomy and conventional approach for aorto-iliac reconstructive surgery. *Acta Chir Hung.* 1997;36(1-4):391-2.
- Kalko Y, Ugurlucan M, Basaran M, Nargileci E, Kafa U, Kosker T, et al. Standard open repair versus minilaparotomy approach for abdominal aortic aneurysms: what is the best approach in patients with ischemic heart disease? *Minerva Chir.* 2008;63(4):269-76.
- Cambria RP, Brewster DC, Abbott WM, Freehan M, Megerman J, LaMuraglia G, et al. Transperitoneal versus retroperitoneal approach for aortic reconstruction: a randomized prospective study. *J Vasc Surg.* 1990;11(2):314-24; discussion 324-5.
- Nakajima T, Kawazoe K, Komoda K, Sasaki T, Ohsawa S, Kamada T. Midline retroperitoneal versus midline transperitoneal approach for abdominal aortic aneurysm repair. *J Vasc Surg.* 2000;32(2):219-23.
- Quiñones-Baldrich WJ, Garner C, Caswell D, Ahn SS, Gelabert HA, Machleder HI, et al. Endovascular, transperitoneal, and retroperitoneal abdominal aortic aneurysm repair: results and costs. *J Vasc Surg.* 1999;30(1):59-67.
- Dion YM, Gaillard F, Demalsy JC, Gracia CR. Experimental laparoscopic aortobifemoral bypass for occlusive aortoiliac disease. *Can J Surg.* 1996;39(6):451-5.
- Fabiani JN, Mercier F, Carpentier A, Le Bret E, Renaudin JM, Julia P. Video-assisted aortofemoral bypass: results in seven cases. *Ann Vasc Surg.* 1997;11(3):273-7.
- Berens ES, Herde JR. Laparoscopic vascular surgery: four case reports. *J Vasc Surg.* 1995;22(1):73-9.
- Ferrari M, Adami D, Del Corso A, Berchiolli R, Pietrabissa A, Romagnani F, et al. Laparoscopy-assisted abdominal aortic aneurysm repair: early and middle-term results of a consecutive series of 122 cases. *J Vasc Surg.* 2006;43(4):695-700.
- Chen MH, D'Angelo AJ, Murphy EA, Cohen JR. Laparoscopically assisted abdominal aortic aneurysm repair. A report of 10 cases. *Surg Endosc.* 1996;10(12):1136-9.
- Oscarsson A, Gupta A, Fredrikson M, Järhult J, Nyström M, Pettersson E, et al. To continue or discontinue aspirin in the perioperative period: a randomized, controlled clinical trial. *Br J Anaesth.* 2010;104(3):305-12.
- Sun JC, Whitlock R, Cheng J, Eikelboom JW, Thabane L, Crowther MA, et al. The effect of pre-operative aspirin on bleeding, transfusion, myocardial infarction, and mortality in coronary artery bypass surgery: a systematic review of randomized and observational studies. *Eur Heart J.* 2008;29(8):1057-71. Epub 2008 Mar 16.
- Neilipovitz DT, Bryson GL, Nichol G. The effect of perioperative aspirin therapy in peripheral vascular surgery: a decision analysis. *Anesth Analg.* 2001;93(3):573-80.
- Chan YC, Cheng SW, Irwin MG. Perioperative use of statins in noncardiac surgery. *Vasc Health Risk Manag.* 2008;4(1):75-81.
- Agnelli G. Prevention of venous thromboembolism in surgical patients. *Circulation.* 2004;110(24 Suppl 1):IV4-12.
- Geerts WH, Bergqvist D, Pineo GF, Heit JA, Samama CM, Lassen MR, et al. Prevention of venous thromboembolism: American College of Chest Physicians Evidence-Based Clinical Practice Guidelines (8th Edition). *Chest.* 2008;133(6 Suppl):381S-453S.
- Bratzler DW, Houck PM. Antimicrobial prophylaxis for surgery: an advisory statement from the National Surgical Infection Prevention Project. *Clin Infect Dis.* 2004;38(12):1706-15. Epub 2004 May 26.
- Kaiser AB, Clayson KR, Mulherin JL Jr, Roach AC, Allen TR, Edwards WH, et al. Antibiotic prophylaxis in vascular surgery. *Ann Surg.* 1978;188(3):283-9.
- Tovey G, Thompson JP. Anaesthesia for lower limb revascularization. *Contin Educ Anaesth Crit Care Pain.* 2005;5(3):89-92.
- Mosimann F, Cornu P. Are enemas given before abdominal operations useful? A prospective randomised trial. *Eur J Surg.* 1998;164(7):527-30; discussion 531-2.
- Gallinger Elu, Seleznev MN, Babalian GV. Use of combined lidocaine and bupivacaine spinal-epidural anesthesia in vascular surgery of lower limbs. *Anesteziol Reanimatol.* 1997;5(5):60-2. Russian
- Acikel U, Karabay O, Silistreli E, Turan A, Sariosmanoğlu N, Oto Ö. Aorto-bifemoral bypass surgery using minilaparotomy technique. *Asian Cardiovasc Thorac Ann.* 1999;7:128-31.
- Klokocovnik T. Minilaparotomy for abdominal aortic aneurysm repair: preliminary results. *Tex Heart Inst J.* 2001;28(3):183-5.
- Turnipseed WD, Carr SC, Tefera G, Acher CW, Hoch JR. Minimal incision aortic surgery. *J Vasc Surg.* 2001;34(1):47-53.
- Maloney JD, Hoch JR, Carr SC, Acher CW, Turnipseed WD. Preliminary experience with minilaparotomy aortic surgery. *Ann Vasc Surg.* 2000;14(1):6-12.
- Rascanu C, Jansen B, Giannakidis A, Bitlisli B, Klenk E. Considerations about the endovascular treatment of infrarenal aortic aneurysms. *Chirurgia (Bucur).* 2011;106(4):445-50. Romanian
- Ghidirim G, Mişin I, Gagauz I, Condrăţchi E. Iliac venous aneurysm: a case report and review of literature. *Chirurgia (Bucur).* 2011;106(2):269-72. Romanian
- Cerveira JJ, Halpern VJ, Faust G, Cohen JR. Minimal incision abdominal aortic aneurysm repair. *J Vasc Surg.* 1999;30(6):977-84.
- Kalko Y, Ugurlucan M, Basaran M, Aydin U, Kafa U, Kosker T, et al. Epidural anaesthesia and mini-laparotomy for the treatment of abdominal aortic aneurysms in patients with severe chronic obstructive pulmonary disease. *Acta Chir Belg.* 2007;107(3):307-12.
- Rob C. Extraperitoneal approach to the abdominal aorta. *Surgery.* 1963;53:87-9.