

## Hematochezia due to Caecal Angiodysplazia led to Diagnosis of a Transverse Colon Cancer in a Young Female Patient: Case Report and Literature Review

G. N. Andrei<sup>1</sup>, B. Popa<sup>2</sup>, M. Popiel<sup>2</sup>, B. I. Diaconescu<sup>3</sup>, B. V. Martian<sup>1</sup>, M. Beuran<sup>1,3</sup>

<sup>1</sup>Department of Surgery, Clinical Emergency Hospital Bucharest, Bucharest, Romania

<sup>2</sup>Department of Interventional Radiology, Clinical Emergency Hospital Bucharest, Romania

<sup>3</sup>University of Medicine and Pharmacy "Carol Davila", Bucharest, Romania

### Rezumat

***Hematochezie datorată unei angiodisplazii cecale determină diagnosticarea unei tumori de colon transvers la o pacientă tânără: raportare de caz și recenzie a literaturii***

Vă prezentăm cazul rar a unei angiodisplazii cecale, a cărei sângerare a determinat descoperirea unei tumori de colon transvers, la un pacient de sex feminin în vârstă de 26 de ani. După tratamentul inițial angiografic al leziunii cecale angiodisplazice, s-a efectuat colectomie segmentară de colon transvers asistată laparoscopic. Evoluția postoperatorie a fost favorabilă, fără reluarea episoadelor de sângerare și reintegrare socială rapidă. Examenul histopatologic a evidențiat adenocarcinom mucinos cu penetrarea seroasei, 7 limfoganglioni pozitivi din 18 examinați. Ca urmare a stadiului avansat, pT4aN2bM0 – STD IIIC, speranța de viață la 5 ani este între 30-50%.

**Cuvinte cheie:** angiodisplazie, hematochezie, embolizare angiografică

### Abstract

We present an unusual case of a caecal angiodysplasia whose bleeding determined the discovery of a mid – transverse colon cancer in a 26 years old female patient. After the initial

successful angiographic treatment of the caecal lesion the patient underwent laparoscopic - assisted transverse colectomy. The postoperative evolution was favorable, without resumption of bleeding episodes and rapid social reintegration. The histopathology revealed mucinous adenocarcinoma that penetrates the visceral serous with 7 lymph nodes invasion of 18 examined. As a result of the advanced stage, pT4aN2bM0 - stage IIIC, the life expectancy at 5 years is between 30 to 50%.

**Key words:** angiodysplazie, haematochezia, angiographic embolization

### Introduction

Angiodysplasia is a real cause of occult and acute lower gastrointestinal bleeding along with diverticulum, neoplasm or internal hemorrhoid. It's rarely highlighted in people under 50 years old. Frequently, lesions are found in the right colon due to increased wall tension of the caecum and ascending colon.

### Case report

*A 26-year old women was admitted to the department of the General Surgery of the Emergency Hospital Floreasca after several episodes of hematochezia. The onset of symptoms dates a week previous, with the appearance of blood in stool, subsequently progressive evolution with recurrence of episodes of hematochezia with the advent of bowel disorders and accompanying symptoms, physical fatigue and dizziness. The patient did not have any co-morbidities. The general clinical examination revealed an afebrile patient, with a bmi of 19 kg/m<sup>2</sup>,*

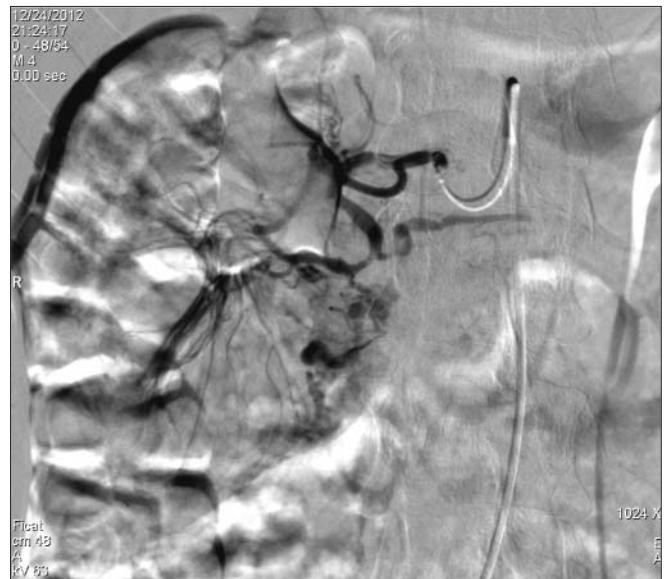---

Corresponding author: Gabriel Nicolae Andrei, MD, PhD student  
Department of Surgery  
Clinical Emergency Hospital Bucharest  
No 8, Floreasca Street, District 1  
014461, Bucharest, Romania  
E-mail: gabi\_and85@yahoo.com

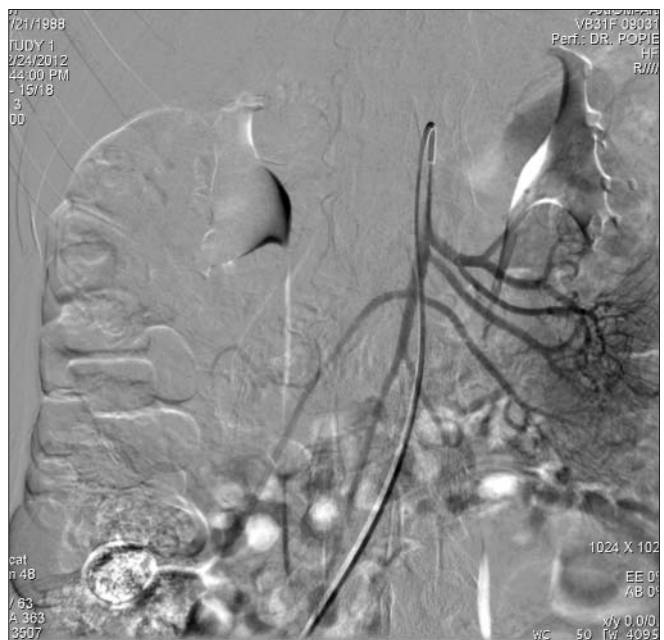
with skin and mucous membranes pale, dehydrated, hemodynamic stable with a blood pressure of 110/70 mmHg and the heart rate of 93 beats per minute. At the local examination the abdomen presents meteoroids but it is painless. The digital rectal examination revealed fresh blood. We initially performed laboratory tests that showed microcytic hypochromic severe posthaemorrhagic anemia with a hemoglobin of 7.6 g/dL. The remaining blood tests were normal. Preliminary laboratory investigations including chest X-ray, abdominal X-ray in standing position and abdominal ultrasound didn't show any particular distress. We conducted our first intention to perform a rigid colonoscopy which didn't uncover the bleeding source but highlighted fresh blood and blood clots in large quantity located in the rectum and sigmoid. We considered appropriate to perform an angiography which revealed active bleeding in the area of an ileo-colic branch (Fig. 1). Catheterization was performed super-selectively using microcatheter 2.8 Fr and the embolization was carried out using two fibrin sponges. The outcome was favorable and the bleeding stopped (Fig. 2). The diagnosis was of caecal angiodysplasia, a very rare one among people of this age. Subsequently we initiated conservative treatment: electrolyte and acid-base rebalancing and blood products administration. After this episode the evolution was progressively favorable with gradual resumption of food tolerance, with the stabilization of the hemoglobin level and devoided of subjective complaints.

In order to investigate the bowel disorders (constipation alternating diarrhea) that appeared suddenly and also to assess the entire colon, after a preliminary mechanical bowel preparation using 4 liters of Fortrans we performed a colonoscopy four days after the angiography. The colonoscopy found a tumor appearance formation suggestive of adenocarcinoma localized at 60 cm from the anal verge, that creates a partial stenosis of the colonic lumen. Biopsies were harvested. Otherwise normal appearance including at the ileo-caecal region. Considering the angiographic result and also that colon tumors located in this part of the colon, are tumors that cause stenosis of the lumen and do not usually bleed, we considered that there were two separate injuries. Pending the outcome of the biopsy with sparing diet, our patient had a good evolution. We also performed a thoracic – abdominal - pelvic CT – scan with contrast material administered orally and iv for preoperative staging, which located the tumor in the middle third of the transverse colon, tumor invading serosa, no lymph nodes detected and without distant metastases – T4aN0M0. Tumor markers harvested preoperatively (CEA, CA 19-9, AFP) were within normal limits. Three weeks after the biopsies, the result was ready: colorectal mucinous adenocarcinoma. Considering the fact that the patient was very young and also that the caecal lesion was treated successfully angiographically without the appearance of complications (rebleeding, ischaemia), within a period of 25 days, we decided to perform laparoscopic-assisted transverse colectomy with the descending of both colonic angles and mechanical anastomosis using CEEA 31 (surgical steps: Figs: 3, 4, 5, 6)

The postoperative course was uneventful patient being discharged 8 days after surgery. The histopathology revealed



**Figure 1.** Active bleeding in the area of an ileo-colic branch

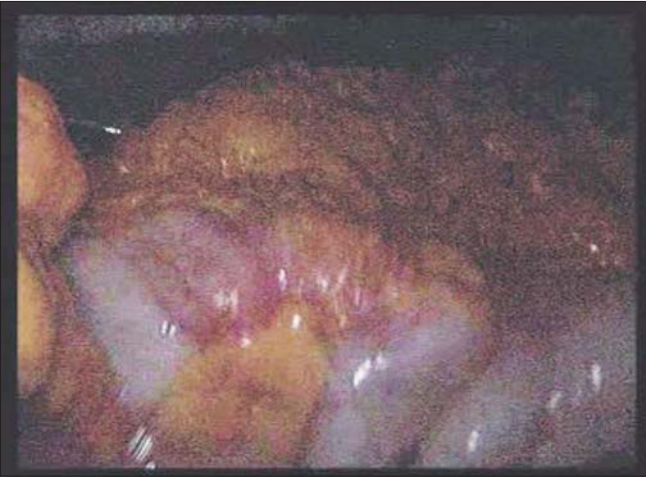

**Figure 2.** Post-embolization: bleeding stopped

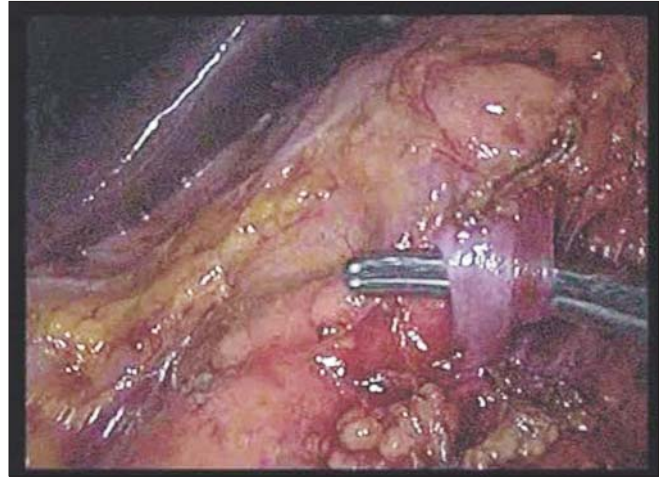
mucinous adenocarcinoma that penetrates the visceral serous with 7 lymph nodes invasion of 18 examined with free resection margins. The patient was referred to oncology for adjuvant therapy. As a result of the advanced stage, pT4aN2bM0 - stage IIIC, the life expectancy at 5 years is between 30 to 50%. At the moment the patient has 1 year and 10 months after surgery and she's doing fine.

## Discussion

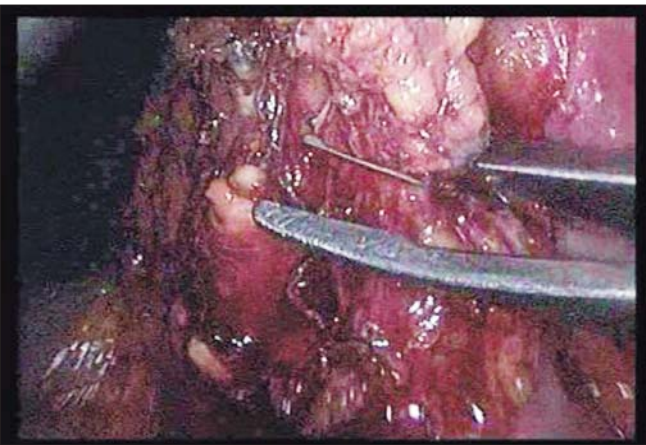
Angiodysplasia is a small vascular malformation, and is a real



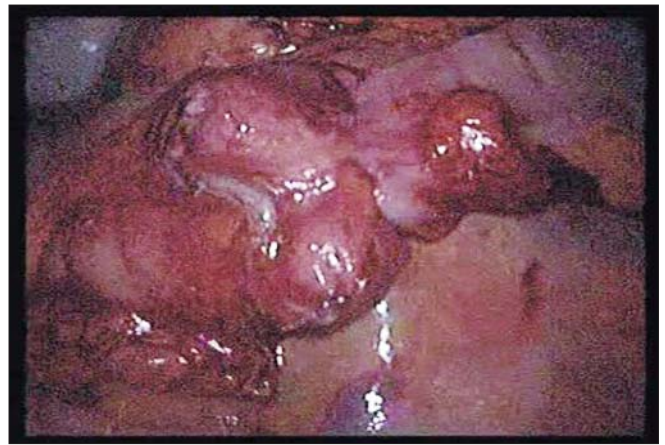
**Figure 3.** *The tumor is located in the middle third of the transverse colon*



**Figure 4.** *Middle colic vessels dissection*



**Figure 5.** *Clipping the vessels at their origin*



**Figure 6.** *Final appearance of the anastomosis*

cause of occult or acute lower gastrointestinal bleeding along with diverticulum, neoplasm or internal hemorrhoid. Lesions are often multiple, and involve more frequently the right colon due to increased wall tension in this area. It's development is related to age and strain on the bowel wall. It is a degenerative lesion, resulting from intermittent or chronic contraction of the colon obstructing the venous drainage of the colon. In time the veins become more and more tortuous and precapillary sphincter becomes incompetent, forming an arteriovenous malformation characterized by dilated vessels (1), (2). That's why it is more common in older people. In our case the patient didn't have any co-morbidities but the tumor was localized downstream and caused bowel disorders, explaining the increased wall tension at the level of the cecum. Lower gastrointestinal bleeding has an estimated annual incidence rate of 20/100.000 population (3). 10 – 15% of patients with lower gastrointestinal bleeding require intervention (4). In the recent years mesenteric angiography and embolization began to be accepted as a part in the management of the patients with acute lower gastrointestinal hemorrhage (5). Technology and equipment have enabled super selective angiographic

embolization to be safely performed with a decrease in the incidence of complications. That's why at the moment embolization is the preferred therapy in the treatment of acute lower gastrointestinal bleeding. When appropriate technique is used the success rate is around 98%. Super selective angiographic embolization targets the vasa recta or the terminal artery distal from the marginal arch. When compared to the upper gastrointestinal tract, the colon is thought to be at higher risk of ischemia due to the absence of significant collateral pathways. However there is a rich intramural vascular network that offers protection against ischemia. Embolization induced bowel ischemia is reported to be around 5% of cases (6). We considered appropriate to perform angiography which revealed active bleeding in the area of an ileo-colic branch. Catheterization was performed super selective using microcatheter 2,8 Fr and the embolization was carried out using two fibrin sponges. The outcome was favorable and the bleeding stopped. We think we fit in the success rate of 98%. Complications did not occur in the immediate evolution the patient having gradual resumption of food tolerance, without rebleeding and being devoided of any

subjective complaints. In order to investigate the bowel disorders (constipation alternating diarrhea) that appeared suddenly and also to assess the entire colon after a preliminary mechanical bowel preparation using 4 liters of Fortrans we performed a colonoscopy four days after the angiography. The colonoscopy found a tumor appearance formation suggestive of adenocarcinoma localized at 60 cm from the anal verge. Biopsies were harvested. Otherwise normal appearance including at the ileocecal region (the appearance of colonic angioectasia can be indistinguishable from normal vascular pattern of the colonic mucosa, especially after successfully angiographic supra selective embolization) (7). Considering the angiographic result and also that colon tumors located in this region are tumors that causes stenosis of the lumen and do not usually bleed, we considered that there were two separate injuries. Hence the particularity of the case.

Since its introduction in the current medical practice, fiberoptic colonoscopy represents a dramatic advance in colon surgery. Colonoscopy allows for diagnosis, harvesting biopsies and offers a wide range of therapeutic modalities. Its main indication is low gastrointestinal bleeding (8). Colonoscopy is a safe technique, complications during the colonoscopy are estimated to be 12.9/1000 exams and incidence of complications within 30 days is 2/1000 exams performed (9).

We also performed a thoracic – abdominal - pelvic CT – scan with contrast material administered orally and iv for preoperative staging, which located the tumor in the middle third of the transverse colon, tumor invading serosa, no lymph nodes detected and without distant metastases – T4aN0M0. CT has a significant role in the preoperative staging and postoperative period of colon cancer (10). The findings related with colon cancer include asymmetric bowel wall thickening or the presence of a soft – tissue mass that can lead to luminal narrowing.

Considering the fact that the patient was very young and also that the caecal lesion was treated successfully angiographically without the appearance of complications (rebleeding, ischemia), within a period of 25 days, we decided to perform laparoscopic assisted transverse colectomy with the descending of both colonic angles and mechanical anastomosis using CEEA 31, made outside. At the beginning of the laparoscopic approach for colorectal cancer studies showed high recurrence rates at port sites. Nowadays, laparoscopy still raises a great number of concerns with the complexity of the technique, learning curve and longer duration of the operation. Melanie Morneau et al, in a study published in October 2013 in the Canadian Journal of Surgery, after 16 randomized trials and 10 meta – analyses were analyzed concluded that for curative treatment of colorectal cancer, laparoscopy is not inferior to open surgery with respect to survival and recurrence rates. Besides that, laparoscopy provides short – term advantages: shorter hospital stay, reduced analgesic use and faster recovery of intestinal function (11). As for the advanced stage (IIIC), Jing Sun et al, in his study concluded that there is no difference in the overall survival and recurrence rate in patients with stage III colon cancer at 5 years. Laparoscopic – assisted surgery was a good option for this case, with better short – term outcomes and similar long – term oncological control, as it was demonstrated.

## Conclusion

Angiodysplasia is a rare but important cause of acute low gastrointestinal bleeding in young adults and should be kept in mind as a diagnostic possibility. Early diagnosis is crucial to avoid a possible fatal outcome. The use of super-selective angiographic embolization is safe and effective and can be considered as a definitive procedure.

The caecal lesion subsequently led to the diagnosis of the mid – third transverse colon cancer. Exceeding the acute episode thanks to angiography, the case could be approached in an elective manner by laparoscopic – assisted surgery. Considering the young age of our patient and the advanced stage (stage IIIC) the long – term prognosis is not great, life expectancy at 5 years being between 30 to 50%.

## Acknowledgement

This paper is supported by the Sectoral Operational Programme Human Resources Development (SOP HRD), financed from the European Social Fund and by the Romanian Government under the contract number POSDRU/187/1.5/ S/155631.

## References

1. R. Jovino, C. Pontecorvo, G. Pesce, P. Jovino. Angiodysplasia of the colon. *Minerva Chir.* 1989. 44(4): 633–5.
2. V. Festa, C. Garrone, P. Simone, M. Morino, M. Toppino, C. Miglietta, et al. Angiodysplasia of the colon. *Minerva Chir.* 1989. 44(9): 138993.
3. G.F. Longstreth. Epidemiology and outcome of patients hospitalized with acute lower gastrointestinal hemorrhage: a population-based study. *Am J Gastroenterol.* 1997. 92: 419–424.
4. R.P. Billingham. The conundrum of lower gastrointestinal bleeding. *Surg Clin North Am.* 1997. 77:241–252.
5. J. DeBarros, L. Rosas, J. Cohen, P. Vignati, W. Sardella, M. Hallisey. The changing paradigm for the treatment of colonic hemorrhage: superselective angiographic embolization. *Dis Colon Rectum.* 2002. 45:802–808.
6. G. Maleux, F. Roeflaer, S. Heye, J. Vandersmissen, A.S. Vliegen, I. Demedts, et al. Long-term outcome of transcatheter embolotherapy for acute lower gastrointestinal hemorrhage. *Am J Gastroenterol.* 2009. 104:2042–2046.
7. J. Bonnes, D.O. Laczek, J. Laczek. Colonic Angioectasia Related Hemorrhage: The Importance of Evaluation During Active Bleeding. *Hawaii J Med Public Health.* 2013. 72(9 Suppl 4): 47.
8. C. A. Onyekwere, J. N. Odiagah, O. A. Lesi. Colonoscopy Practice in Lagos, Nigeria: A Report of an Audit Diagnostic and Therapeutic Endoscopy. 2013.
9. W. Cynthia, S. Riffle, D. Lieberman. Serious complications within 30 days of screening and surveillance colonoscopy are uncommon. *Clin Gastroenterol Hepatol.* 2010. 8(2): 166.
10. K.M. Horton, R.A. Abrams, E.K. Fishman. Spiral CT of colon cancer: imaging features and role in management. *Radiographics.* 2000. 20:419–430.
11. M. Morneau, J. Boulanger, P. Charlebois, J.F. Latulippe, R. Lougnarath, C. Thibault, et al. Laparoscopic versus open surgery for the treatment of colorectal cancer: a literature review and recommendations from the Comité de l'évolution des pratiques en oncologie. *Can J Surg.* 2013. 56(5): 297–310.