

Laparoscopic Mobilization of an Omental Flap for a Chronic Scarpa Triangle Suppuration after Vascular Graft Infection

P.V.H. Boțianu¹, A.M. Boțianu¹, R. Chirtes², A. Bacarea³

¹University of Medicine and Pharmacy from Tirgu-Mures, Romania, Surgery IV Discipline, M5 Department

²Surgical Clinic II, Mures Clinical County Hospital, Romania

³University of Medicine and Pharmacy from Tirgu-Mures, Romania, Department of Physiopathology

Rezumat

Mobilizare laparoscopică a unui lambou de epiploon pentru o supurație de triunghi Scarpa după infecție de proteză vasculară

Prezentăm un caz de mobilizare laparoscopică a unui lambou de epiploon (vase epiploice stângi) care a fost folosit pentru rezolvarea unei infecții cronice la nivelul triunghiului Scarpa după o infecție de proteză vasculară (acoperire petec de pericard bovin – angioplastie pentru închiderea defectului rezultat după excizia protezei). Intervenția a durat 90 de minute și a fost efectuată folosind 3 trocare și instrumente laparoscopice standard. Evoluția postoperatorie imediată a fost favorabilă, cu reluarea tranzitului la 12 ore postoperator și vindecarea plăgii; pacientul a decedat după 9 luni datorită unor complicații la membrul contralateral. În cazurile cu anatomie favorabilă, mobilizarea laparoscopică a epiploonului este extrem de ușoară, fiind asociată cu o recuperare rapidă și reducerea morbidității.

Cuvinte-cheie: epiploon, mobilizare laparoscopică, proteză vasculară, infecție

Abstract

We report a case of laparoscopic mobilization of an omental flap (left epiploic vessels) which was used to solve a Scarpa

triangle chronic suppuration after a vascular prosthesis infection (coverage of bovine pericardium patch – angioplasty for closure of the defect resulting after the excision of the vascular graft). The procedure lasted 90 minutes and was performed using 3 trocars and standard laparoscopy instruments. The immediate postoperative course was favourable, with regain of transit after 12 hours and healing of the wound; the patient died 9 months later due to some complications that occurred on the contralateral leg. In cases with a favourable anatomy, the laparoscopic mobilization of the omentum is extremely easy, being associated with a quick recovery and a reduction of the morbidity.

Key words: omentum, laparoscopic mobilization, vascular graft, infection

Introduction

The omentum flap has been used in a great variety of clinical situations due to its excellent blood supply and adaptability (1-6). During recent years, the use of a laparoscopic approach for its mobilization has become popular, having the main advantage of decreasing the morbidity associated with laparotomy (7, 8). We report the use of laparoscopic mobilization of an omental flap which was used to solve a chronic Scarpa triangle suppuration after a vascular prosthesis infection.

Case report

We present a 63 years old male patient who was initially

Corresponding author:

Prof. Dr. Alexandru-Mihail Botianu
540139 Gheorghe Marinescu 66/1
Tirgu-Mures, Jud. Mures, Romania
E-mail: botianu.alexandru@yahoo.com

diagnosed with critical limb ischemia due to an aorto-iliac occlusive disease. During the last 18 months the patient underwent the following 5 procedures, all of them being performed in another unit:

- aorto-bifemoral by-pass with Dacron prosthesis;
- desobstruction of the left arm of the prosthesis;
- left femoro-popliteal by-pass with Gore-Tex prosthesis;
- desobstruction of the left arm of the aorto-bifemoral prosthesis + distal by-pass using autologous vein;
- wound infection – removal of the femoro-popliteal Gore-tex prosthesis.

The patient remained with a chronic wound suppuration in the upper part of the thigh, corresponding to the incision made in the Scarpa triangle for the exposure of the femoral artery. At 18 months after the initial procedure, the patient was referred to our unit with a dehiscent wound with purulent secretions and a visible prosthesis at the bottom of the wound, local inflammation and general signs of sepsis. The aorto-bifemoral by-pass was functional but the left femoro-popliteal one was obstructed. Bacteriologic examination has shown the presence of MRSA and *Acinetobacter*. We started iv antibiotherapy and local lavages and dressings but at 72 hours after admission the patient presented a massive pulsatile hemorrhage through the groin wound with hemorrhagic shock that required emergency surgery consisting of:

- clamping of the left arm of the aorto-bifemoral by-pass;
- complete opening of the dehiscent anastomosis and endoluminal clamping of the profunda femoris and common femoral artery;
- removal of the distal part of the left arm of the aorto-bifemoral prosthesis;
- reconstruction of the femoral bifurcation using autologous bovine pericardium. This procedure was chosen instead of simple vessel ligation due to the presence of an acceptable retrograde flow from the profunda femoris and common femoral artery in order to avoid acute left leg ischemia and amputation.
- wound debridement, lavages, drainage and wound closure.

The patient recovered from the hemorrhagic shock and remained with an ischemic but viable leg. There were moderate secretions at the level of the groin wound which persisted despite daily lavages and antibiotherapy for 3 weeks (Fig. 1). Considering the high risk for a new episode of bleeding we have chosen to cover the pericardial flap with a well vascularised tissue and decided to use the omentum for this purpose.

The procedure was performed under general anesthesia with the patient in dorsal decubitus. Due to the previous laparotomy, we started with an open laparoscopy in the right iliac fossa using a 2 cm incision similar with the McBurney incision used for classic appendectomy. Other two trocars were placed in a paraumbilical and suprapubic position. After adhesiolysis, we inspected the omentum and created a flap based on the left epiploic vessels. With a minimum dissection, the flap reached the left inguinal ligament and

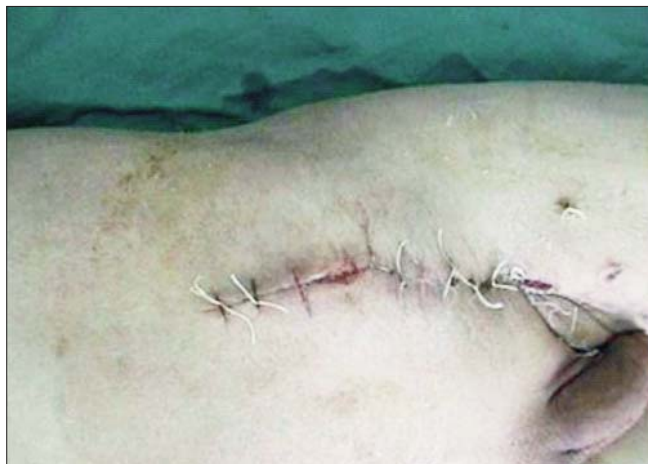

Figure 1. Chronic wound suppuration in the Scarpa triangle

was brought outside the peritoneal cavity. The groin wound was re-opened and debrided, followed by the fixation of the omental flap with complete filling of the wound and coverage of the the bovine pericardium flap. After drainage, the skin and subcutis were closed over the pericardium patch (Fig. 2).

The procedure lasted 90 minutes and was performed using 3 trocars and basic laparoscopic instruments (hook-monopolar electrocautery, scissors and dissector). The immediate postoperative course was favourable, with regain of transit after 12 hrs, primary wound healing and no recurrence of the groin suppuration (Fig. 3). The patient died 9 months later after an emergency axillo-femoral by-pass performed for acute ischemia of the right leg after complete removal of the intraabdominal prosthesis.

Discussions

The treatment of chronic wounds associated with vascular prosthesis infection remains a challenge, involving a high rate of failure in terms of mortality and/or leg loss. There are many possible solutions, each of them with advantages and disadvantages (9, 10). In our case, we preferred to use the omentum instead of local groin flaps because of the complicated history of the patient with 6 previous procedures that involved dissection in the upper part of the thigh.

Micheau (1995) considers the omentum to be an “extreme flap for extreme situations” (11). Its use was popularized by many authors, including the Romanian Ion Chiricuta – Professor of Surgery and founder of the Oncology Institute from Cluj-Napoca (12). It may be an elegant solution in a very wide range of defects and clinical situations. However, its use has some disadvantages, mainly related to the variable anatomy and the morbidity associated with laparotomy (13).

The endoscopic approach for the mobilization of different flaps is suggested by some authors as a possible solution to reduce the donor-site morbidity (14, 15). In the particular case of the omentum, the laparoscopic approach solves two main problems related to this flap:

- it allows a quick evaluation of the anatomy, thus

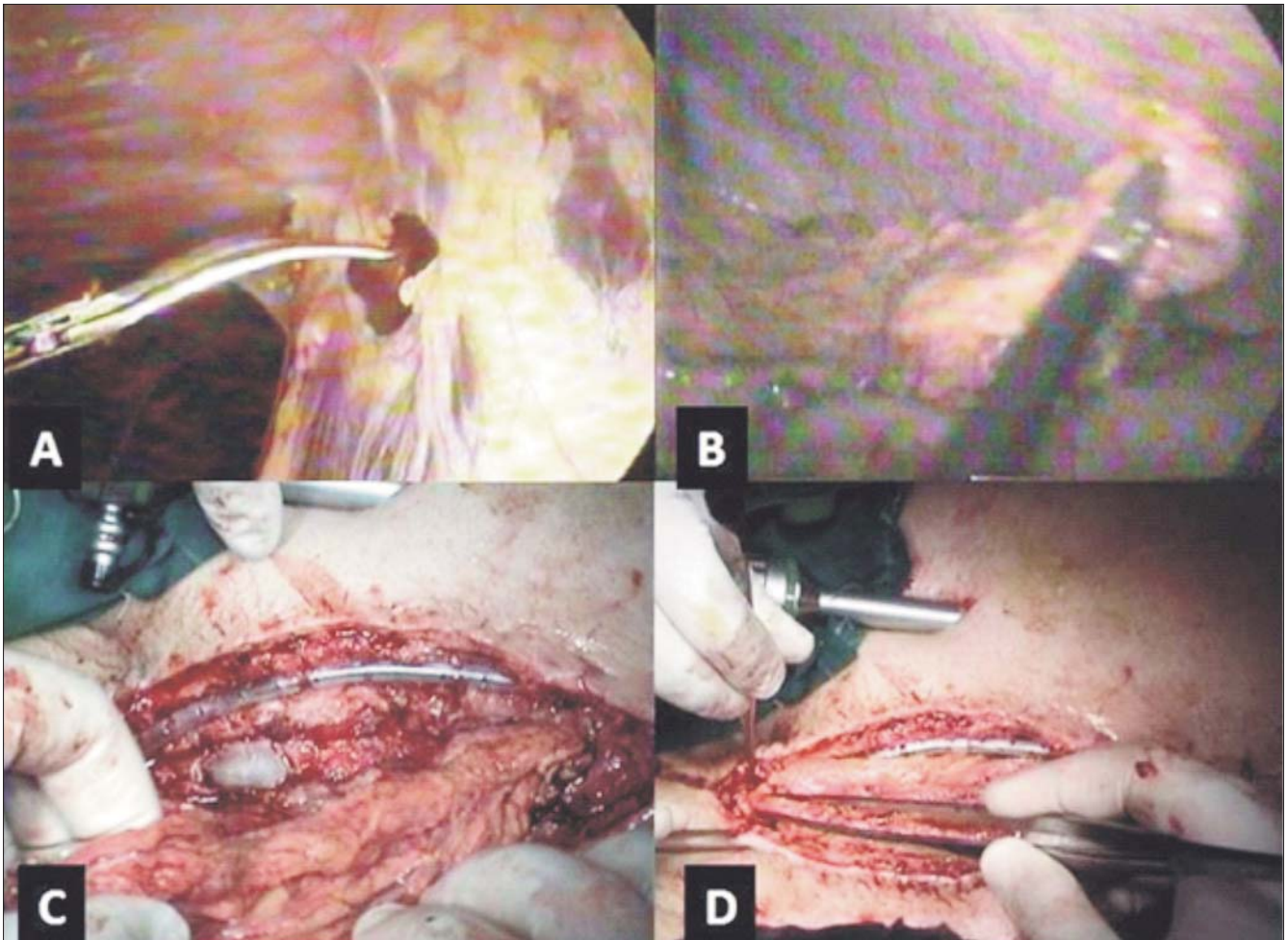


Figure 2. Intraoperative images. Laparoscopic dissection of the adhesions between the omentum and the anterior abdominal wall (A) and mobilization of the omental flap using the left epiploic vessels (B). Coverage of the femoral vessels and the bovine pericardium patch with the omentum (C, D)

avoiding an useless laparotomy in case of an unfavourable anatomy;

- it reduces the early and late morbidity associated with laparotomy.

There is now enough experience showing that the laparoscopic mobilization of the omentum is a safe procedure in terms of both overall morbidity and quality of the flap (7, 8, 16-18). The possibility of performing its mobilization using a laparoscopic approach has increased the indications for its use in certain situations such as breast reconstruction (7, 19) and sterno-mediastinis / sternal dehiscence (8, 20, 21). Some authors recommend the routine use of a laparoscopically harvested omental flap to fill the dead pelvic space that remains after laparoscopic abdomino-perineal resection for rectal cancer (22).

Our patient had a favourable anatomy which allowed a very easy mobilization without the need of a delicate dissection or special instruments. Compared to a classic laparotomy approach, the advantages were obvious in terms of early recovery.

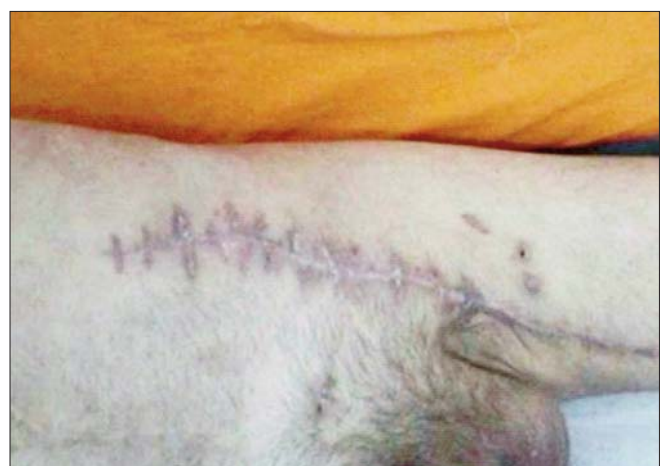

Figure 3. Aspect of the wound at 2 months after surgery.

Conclusions

The laparoscopic mobilization of the omentum is a safe procedure, allowing an early recovery and the avoidance of some of the laparotomy-related complications. In patients with a favourable anatomy the laparoscopic mobilization of the omentum may be performed very easy with basic laparoscopic instruments.

Conflict of interests and source of funding: none.

References

1. Xu L, Zhang S, Li J, Liu J, Liu H, Huang W, Shang X. Human tracheal allotransplant with greater omentum for revascularization. *Exp Clin Transplant*. 2014;12(5):448-53.
2. Sorour MA. Interposition of the omentum and/or the peritoneum in the emergency repair of large ventral hernias with polypropylene mesh. *Int J Surg*. 2014;12(6):578-86.
3. Khater A. Evaluation of pedicled omental flap delivered through a minilaparotomy for immediate breast reconstruction in obese patients. *Aesthetic Plast Surg*. 2013;37(6):1140-5.
4. Horch RE, Horbach T, Lang W. The nutrient omentum free flap: revascularization with vein bypasses and greater omentum flap in severe arterial ulcers. *J Vasc Surg*. 2007;45(4):837-40.
5. Antohi N, Tibirna G, Suharski I, Huian C, Nae S, Stan V, Bodog F. Gastro-omental free flap in oro/hypopharyngeal reconstruction after enlarged ablative surgery for advanced stage cancer. *Chirurgia (Bucur)*. 2013;108(4):503-8.
6. Botianu PV, Damian V, Ionică S, Lucaciu OR, Botianu AM, Botianu AM. Extraperitoneal mobilization of the omentum—analysis of a personal series of 12 patients. *Chirurgia (Bucur)*. 2012;107(5):611-5.
7. Zaha H, Inamine S. Laparoscopically harvested omental flap: results for 96 patients. *Surg Endosc* 2010;24(1):103-7.
8. van Wingerden JJ, Coret ME, van Nieuwenhoven CA, Totté ER. The laparoscopically harvested omental flap for deep sternal wound infection. *Eur J Cardiothorac Surg*. 2010;37(1):87-92.
9. de Donato G, Setacci F, Galzerano G, Ruzzi U, Borrelli MP, Mazzitelli G, Setacci C. Prosthesis infection: prevention and treatment. *J Cardiovasc Surg (Torino)*. 2014;55(6):779-92.
10. Diener H, Hellwinkler O, Carpenter S, Larena-Avellaneda A, Debus ES. Homografts and extra-anatomical reconstructions for infected vascular grafts. *J Cardiovasc Surg (Torino)*. 2014;55(2 Suppl 1):217-23.
11. Micheau P. The greater omentum. Its role in reconstructive plastic surgery. *Ann Chir Plast Esthet*. 1995;40(2):192-207.
12. Kiricuță I. Use of the omentum in plastic surgery. Ed. Medicală / Medical Publishing House, București; 1980.
13. Hultman CS, Carlson GW, Losken A, Jones G, Culbertson J, Mackay G, Bostwick J 3rd, Jurkiewicz MJ. Utility of the omentum in the reconstruction of complex extraperitoneal wounds and defects: donor-site complications in 135 patients from 1975 to 2000. *Ann Surg*. 2002;235(6):782-95.
14. Blidișel A, Măciuceanu B, Jiga L, Păpurică M, Ionac M. Endoscopy-assisted harvesting and free latissimus dorsi muscle flap transfer in reconstructive microsurgery. *Chirurgia (Bucur)*. 2008;103(1):67-72.
15. Shipkov C, Mojallal A, Uchikov A, Stefanova P, Braye F. The endoscopic latissimus dorsi flap harvest: advantages and technical drawbacks. *J Laparoendosc Adv Surg Tech A*. 2011;21(6):541-2.
16. Urek W, Makarewicz W, Bobowicz M, Sawicka W, Rzyman W. The treatment of chronic pleural empyema with laparoscopic omentoplasty. Initial report. *Wideochir Inne Tech Maloinwazyjne*. 2014;9(4):548-53.
17. Navarro R, Chao K, Gooderham PA, Bruzoni M, Dutta S, Steinberg GK. Less invasive pedicled omental-cranial transposition in pediatric patients with moyamoya disease and failed prior revascularization. *Neurosurgery*. 2014;10 Suppl 1:1-14.
18. Acarturk TO, Swartz WM, Luketich J, Quinlin RF, Edington H. Laparoscopically harvested omental flap for chest wall and intrathoracic reconstruction. *Ann Plast Surg*. 2004;53(3):210-6.
19. Cothier-Savey I, Tamtawi B, Dohnt F, Raulo Y, Baruch J. Immediate breast reconstruction using a laparoscopically harvested omental flap. *Plast Reconstr Surg*. 2001;107(5):1156-63.
20. Reade CC, Meadows WM Jr, Bower CE, Lalikos JF, Zeri RS, Wooden WA. Laparoscopic omental harvest for flap coverage in complex mediastinitis. *Am Surg* 2003;69(12):1072-6.
21. Salameh JR, Chock DA, Gonzalez JJ, Koneru S, Glass JL, Franklin ME Jr. Laparoscopic harvest of omental flaps for reconstruction of complex mediastinal wounds. *JSLs* 2003;7(4):317-22.
22. Killeen S, Mannion M, Devaney A, Winter DC. Omentoplasty to assist perineal defect closure following laparoscopic abdominoperineal resection. *Colorectal Dis*. 2013;15(10):e623-6.