

Isolated tuberculous tenosynovitis of the forearm in an immunocompetent patient

A. Hristea¹, A. I. Luka¹, I. Oancea², F. Bica³, F. Stăniceanu⁴, V. Arama¹, A. Streinu-Cercel¹, R. Moroti¹

¹“Prof. Dr. Matei Balș” National Institute for Infectious Diseases, Department of Infectious Diseases, UMF Carol Davila, Bucharest

²“Phoenix” Diagnostic Clinics

³“Bagdasar-Arseni” Emergency Clinical Hospital, Department of Orthopedics, UMF Carol Davila, Bucharest

⁴“Colentina” Clinical Hospital, Department of Pathology, University of Medicine and Pharmacy Carol Davila, Bucharest

Rezumat

Tenosinovita tuberculoasă primară la nivelul antebrăului unui pacient imunocompetent

Tenosinovita tuberculoasă primară este o manifestare rară a tuberculozei musculoscheletale extraspinale. Diagnosticul poate fi întârziat cu ușurință datorită semnelor clinice nespecifice. Comunicăm un caz documentat bacteriologic de tenosinovită tuberculoasă a tendonului extensor carpi ulnaris și a tendonului comun al extensorilor la o pacientă de 68 de ani fără tuberculoză pulmonară concomitentă sau deficite imune documentate. Diagnosticul a fost inițial trecut cu vederea, deoarece după prima intervenție chirurgicală nu s-au realizat examene microbiologice și histopatologice adecvate. RMN reprezintă metoda de diagnostic cea mai potrivită, însă nu are specificitate pentru tuberculoză, iar biopsia chirurgicală este recomandată în vederea confirmării diagnosticului. Pacienta a răspuns favorabil din punct de vedere clinic la tratamentul antituberculos (*Mycobacterium tuberculosis* sensibil) combinat cu excizia chirurgicală. Subliniem necesitatea includerii tuberculozei în diagnosticul diferențial al tuturor cazurilor de abcese cronice sau recurente ale extremităților, nu numai la pacienții care trăiesc în zone cu endemie de tuberculoză, ci și la pacienții care au emigrat din regiuni cu prevalență crescută a tuberculozei.

Cuvinte cheie: tenosinovită antebră, tuberculoză

Abstract

Primary tuberculous tenosynovitis is a rare manifestation of extraspinal musculoskeletal tuberculosis. The diagnosis may be easily delayed because of its nonspecific clinical signs. We report a case of culture-proven tuberculous tenosynovitis of the extensor carpi ulnaris tendon and common extensor tendon in a 68-year-old female without concomitant pulmonary tuberculosis, nor documented immunodeficiency. The diagnosis was initially overlooked due to the lack of appropriate histological and bacteriological analyses and the lesion recurred after surgery. MR imaging represents the most accurate method in making the diagnosis, but has no diagnostic specificity in regard to tuberculosis, therefore surgical biopsy is strongly recommended. The patient had a favorable clinical response after a combination of excision and appropriate antituberculous therapy for sensitive *Mycobacterium tuberculosis*. We emphasize the need for an increased awareness and high index of suspicion of tuberculosis in all cases of a chronic or recurrent abscess in the extremities, not only in patients living in endemic areas but also in those who have emigrated from regions with a high prevalence of tuberculosis.

Key words: forearm tenosynovitis, tuberculosis

Corresponding author:

Adriana Hristea
Department of Infectious Diseases
“Prof. Dr. Matei Balș” Național Institute
for Infectious Diseases
Str. Calistrat Grozovici, nr. 1, sector 2,
021105, Bucharest
E-mail: adriana_hristea@yahoo.com

Introduction

Tuberculous tenosynovitis (TTS) is the least frequent location of extraspinal musculoskeletal tuberculosis (TB), even in countries where TB is a relatively common disease. (1,2)

According to WHO data, Romania is among the six countries from the European Region with the highest TB notification rate. We report a case of culture-proven tuberculous abscess involving the forearm, in a patient without concomitant pulmonary TB, nor documented immunodeficiency. The aim is to emphasize the need for an increased awareness and high index of suspicion of extrapulmonary TB in making an early diagnosis, not only in patients living in endemic areas but also in those who have emigrated from regions with a high prevalence of TB.

Case Report

A 68-year-old female was admitted with a non-traumatic soft tissue lesion of the antero-medial region of the right forearm. The lesion had been present for the previous three months and surgery was initially performed but no microbiological or pathological diagnosis was made at the time. The patient was treated with cephalexin but the lesion persisted with discharge and minimal signs of local inflammation. Two months after surgery, an ultrasound was performed which revealed a hypoechoic area of 5 cm diameter in the soft tissue of the distal third of the antero-medial region of the right forearm suggesting an abscess. There was no history of fever, night sweats, weight loss or previous trauma to the site. The patient had no significant past medical history, including pulmonary or extrapulmonary TB.

On physical examination an irregular, slightly erythematous area with drainage of sero-purulent material was seen on the distal third of the antero-medial region of the right forearm. The area was slightly tender to palpation. The remainder of the physical examination was normal.

Routine blood tests revealed no significant abnormalities and the chest X-ray was normal. HIV antibodies were negative. MRI examination of the forearm revealed a large inhomogeneous mass in the postero-medial compartment, measuring 8x4 cm, located deep in the antebrachialis fascia, involving the extensor carpi ulnaris tendon and extensor digitorum tendon. The mass was situated near the ulnar cortex, but there was no muscular or bone involvement. Based on MR images, the diagnosis of tenosynovitis with abscess formation and a sub-cutaneous fistula was made (Fig. 1-4).

A second surgical intervention was performed with excision and debridement of the lesion. The histopathological report revealed chronic granulomatous inflammation with multi-nucleated giant cells but no microorganisms were seen on Gram, PAS or Ziehl Nielsen smears. Polymerase chain reaction (PCR) in situ was positive for specific sequences for *M. tuberculosis*. Cultures grew sensitive *M. tuberculosis*. Other investigations, for pulmonary or extrapulmonary TB were negative. The patient received isoniazid, rifampin, pyrazinamide and ethambutol for two months, followed by isoniazid and rifampin for nine months with a favorable clinical response.

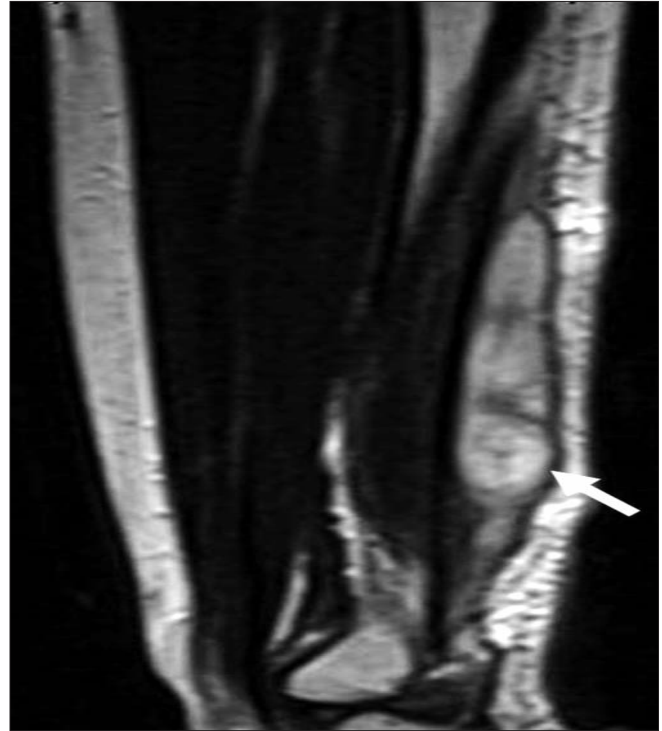

Figure 1. MRI of the right forearm. T2-TSE sagittal sequence shows well defined, inhomogeneous hyperintense mass in the posterior compartment, deep to the antebrachial fascia, along the extensor tendon (→), corresponding to an abscess

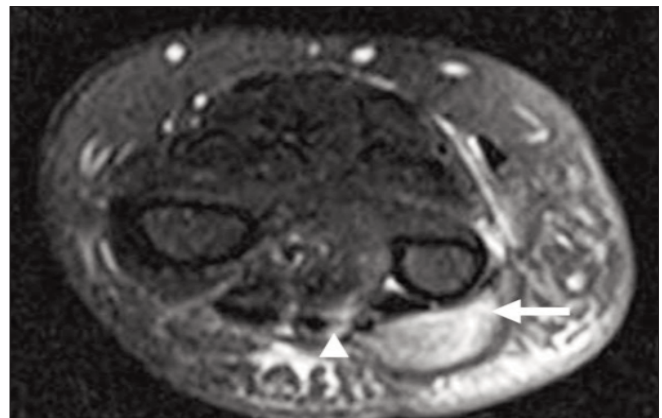


Figure 2. MRI of the right forearm. STIR axial sequence showed diffuse thickening of the common extensor tendon (→) and an abscess along the extensor carpi ulnaris tendon (→)

Discussion

Musculoskeletal TB accounts for a minority of all tuberculous infections and TTS is a rare condition. There have been few reports of primary TTS in the English literature without the involvement of bone. (3-8)

Almost any long tendon may be affected, but TTS most commonly affects the upper extremity (hand and wrist),

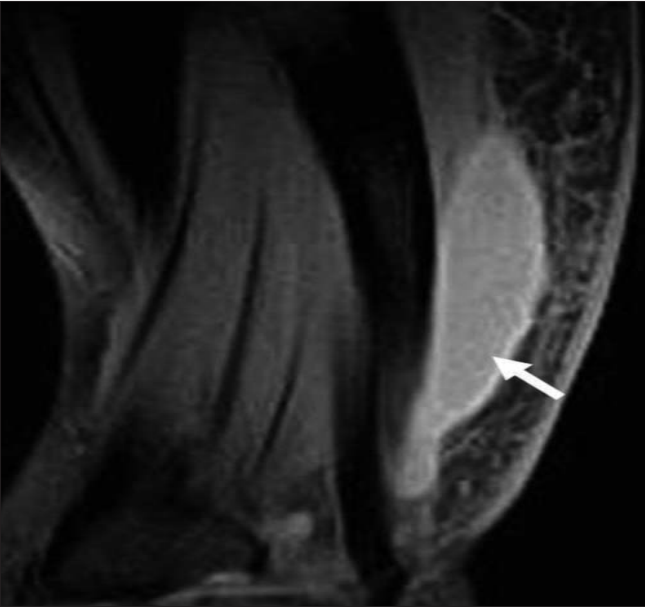


Figure 3. MRI of the right forearm. T1-TSE with fat suppression coronal images reveal predominantly peripheral enhancement of the mass (→)

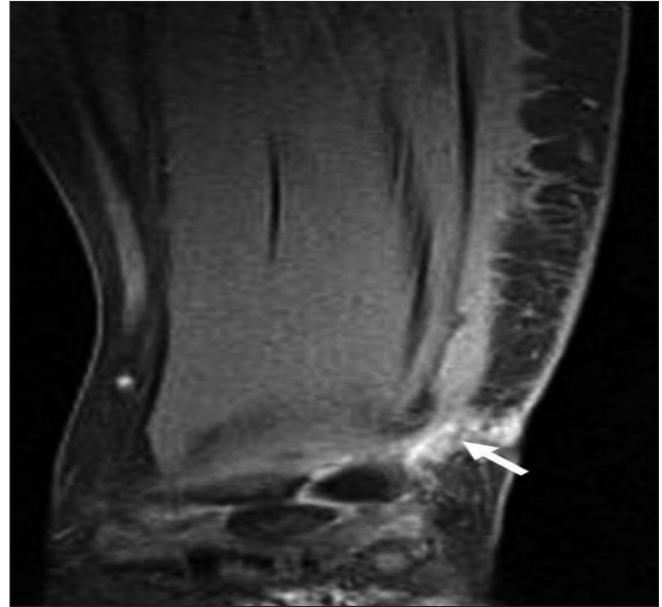


Figure 4. MRI of the right forearm. T1-TSE with fat suppression coronal images reveal fistula formation towards the surface of the skin, communicating with the ulnar bursa (→)

especially the flexor tendon sheath, the radioulnar bursae and the digital flexor sheaths. (7,8)

TTS results from hematogenous dissemination from a primary pulmonary lesion, or from direct inoculation from adjacent bone or joint infection. (7,9) Most authors describe concomitant active pulmonary disease in about 50% of patients. (1,7,8) Risk factors associated with TTS are age greater than 60 years, low socioeconomic status, malnutrition, ethanol abuse, history of or exposure to TB, immunosuppression, and previous local injection of corticosteroids, or local trauma prior to infection. (3,9)

The clinical course is gradual and chronic, with an insidious onset, and patients present with swelling, pain and decreased range of motion. In the late stages of the disease sinus tracts and the formation of cold abscesses can be observed with discharge of purulent material with little inflammation. Due to the non-specific clinical presentation and to the less awareness, there usually is a delay in establishing the diagnosis, (1,3,6) as was the case in our patient. TTS is frequently misdiagnosed as rheumatoid arthritis, non-specific tenosynovitis, soft tissue tumors, chronic wounds or carpal tunnel syndrome.

From a histopathological point of view, the disease presents in three stages (1,2) that can overlap so that more than one stage can be seen in the same patient. The first or hygro-matous stage presents with a serous exudate within the tendon sheath that is usually normal in appearance, but can also be thin or thickened by granulation tissue. In the second stage (serofibrinous) the sheath becomes partially obliterated by fibrous and caseous tissue and possible spontaneous rupture of the involved tendon is seen. The final or fungoid stage presents with extensive caseation and granulation, sinus tract and cold

abscess formation, with possible joint or bone involvement.

Imaging studies are helpful in making the diagnosis and are essential in evaluating the extent of the disease. Plain radiographs demonstrate soft tissue swelling and osteopenia, and in chronic cases narrowing of the joint space and bone erosions. MR imaging, owing to its superior soft-tissue contrast, represents the most accurate method in making a diagnosis of an abscess with synovial involvement and identifying the exact location and extension of the process. In the serofibrinous stage, a thickened synovium with low signal intensity material within the synovial fluid on T2 weighted images is visible, as well as tendon involvement (thinning or disruption). The fungoid stage is characterized by extension of the lesion beyond the tendon sheath with enhancing soft tissue mass formation. (2) The MRI aspects of lesions in the fungoid stage can be confused with tumors. Based on imagistic aspect, the differential diagnosis of TTS includes: rheumatoid arthritis, pyogenic infection, fungal tenosynovitis, giant cell tumor of the tendon sheath and tumors originated from the synovium such synovial chondromatosis. (2) In our patient, MR imaging were consistent with the fungoid stage.

An important aspect in the diagnosis is open surgical biopsy, which is considered by some authors as being the most important diagnostic procedure. (1) It usually reveals granulomatous inflammation but has low specificity due to the fact that several other diseases can cause similar microscopic lesions, such as atypical mycobacterial infections, certain fungi, Brucella species, and other infectious agents. In addition, inflammatory disorders, such as sarcoidosis, crystal-associated arthritis, or foreign body reactions also are considered when granulomatous changes are seen on histological examination of

a tissue specimen. (5,6)

Microbiological analyses are required to confirm the diagnosis and distinguish *M. tuberculosis* from atypical mycobacteria. Direct microscopic examination of the biopsy specimen for acid fast bacilli is usually negative, so cultures on selective media and specific biochemical tests are essential for identification of mycobacteria, as well as for susceptibility testing. In our patient, due to the in situ PCR the appropriate therapy has been instituted promptly.

Treatment of TTS relies on a combination of surgery and antituberculous chemotherapy. Recurrences are common in patients treated with debridement alone, more than 50% of cases recurring within one year after the surgical procedure, as in our patient. Long term follow up of patients is necessary, since some authors have described recurrences even with appropriate therapy. (10)

Conclusion

TTS should be considered in all cases of chronic or recurrent abscess in extremities. This entity may appear even in immunocompetent patients and in the absence of osseous involvement, especially in those currently or previously living in endemic areas of TB.

The authors have no financial disclosures to declare and no conflicts of interest to report

Acknowledgement

The authors would like to thank Professor Emeritus Richard B. Roberts from the Weill Medical College of Cornell University, NY for his assistance with manuscript preparation.

References

1. Abdelwahab IF, Bianchi S, Martinoli C, Klein M, Hermann G. Atypical extraspinal musculoskeletal tuberculosis in immunocompetent patients: part II, tuberculous myositis, tuberculous bursitis, and tuberculous tenosynovitis. *Can Assoc Radiol J.* 2006;57(5):278-86.
2. Jaovisidha S, Chen C, Ryu KN, Siriwongpairat P, Pekan P, Sartoris DJ, Resnick D. Tuberculous tenosynovitis and bursitis: imaging findings in 21 cases. *Radiology.* 1996;201(2):507-13.
3. Jackson RH, King JW. Tenosynovitis of the hand: a forgotten manifestation of tuberculosis. *Rev Infect Dis.* 1989;11(4):616-8.
4. Regnard PJ, Barry P, Isselin J. Mycobacterial tenosynovitis of the flexor tendons of the hand. A report of five cases. *J Hand Surg Br.* 1996;21(3):351-4.
5. Walker UA, Gutfleisch J, Peter HH. Case Number 23: Tuberculous tenosynovitis. *Ann Rheum Dis.* 2002; 61(5):384.
6. Kriegs-Au G, Ganger R, Petje G. The sequelae of late diagnosis in tuberculous flexor tenosynovitis of the hand - a report of 2 cases. *Acta Orthop Scand.* 2003;74(2):221-4.
7. Aboudola S, Sienko A, Carey RB, Johnson S. Tuberculous tenosynovitis. *Hum Pathol.* 2004;35(8):1044-6.
8. Higuchi S, Ishihara S, Kobayashi H, Arai T. A mass lesion of the wrist: a rare manifestation of tuberculosis. *Intern Med.* 2008;47(4):313-6. Epub 2008 Feb 15.
9. Uthman I, Bizri AR, Hajj Ali R, Haraoui B. Miliary tuberculosis presenting as tenosynovitis in a case of rheumatoid arthritis. *J Infect.* 1998;37(2):196-8.
10. Cramer K, Seiler JG 3rd, Milek MA. Tuberculous tenosynovitis of the wrist. Two case reports. *Clin Orthop Relat Res.* 1991; 262:137-40.