

## Clinical measurement technique of clear margin for excision of oral squamous cell carcinoma (SCC)

R. Dragomir<sup>1</sup>, J. Herold<sup>2</sup>

<sup>1</sup>SHO in Oral and Maxillofacial Surgery, Brighton and Sussex University Hospital, U.K.

<sup>2</sup>Consultant Oral & Maxillofacial Surgeon, Brighton and Sussex University Hospital, U.K.

Having a clear resection margin when excising a SCC of the mouth is essential in reducing the incidence of local recurrences.

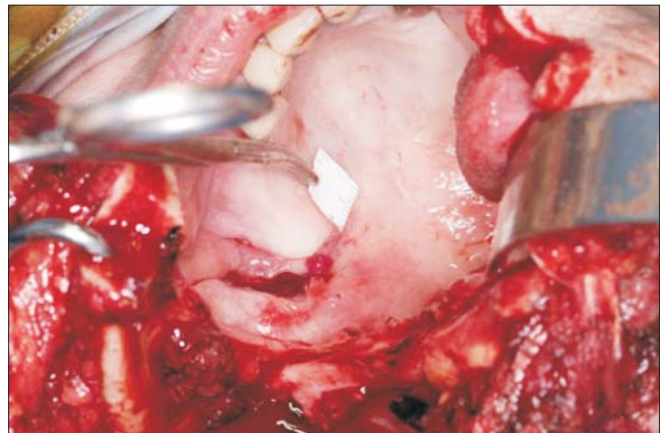
The currently accepted standard is resection of the primary lesion with 1 cm of normal tissue margins surrounding the tumor.

This technique describes how to measure 1 cm around the tumor into what appears to be healthy tissue to the naked eye.

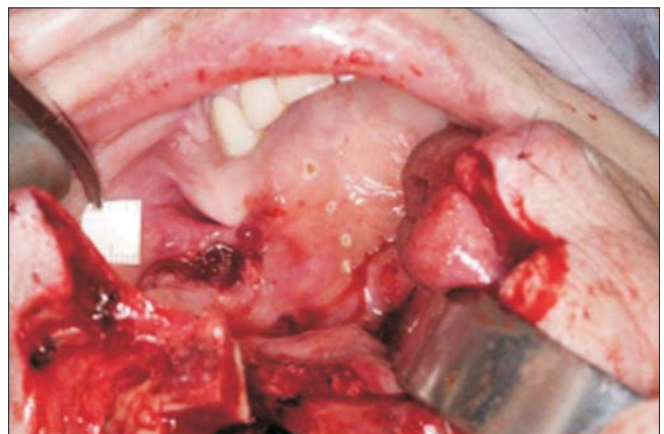
To our knowledge, this technique has not been reported.

We use a 1 cm length strip previously cut from a standard sterile paper ruler. Attaching an artery clip to the strip, we easily place the paper all the way surrounding the clinically visible outer limit circumference of the lesion (Fig. 1). The resection margins are appropriately demarcated by marking dots (Fig. 2) using a monopolar electrode with an ultra-sharp tip. The dots are joined together with the same tip in order to complete marking the margins. The resection is then successfully performed along the demarcated line (Fig. 3).

This technique allows measurement without stretching which is vital to avoid errors. Stretching of the tissue can reduce the margins, thus not fulfilling the currently accepted standard. This technique attempts to ensure the correct excision of the tumor mass, however only allows demarcation in a 2-dimensional plane.



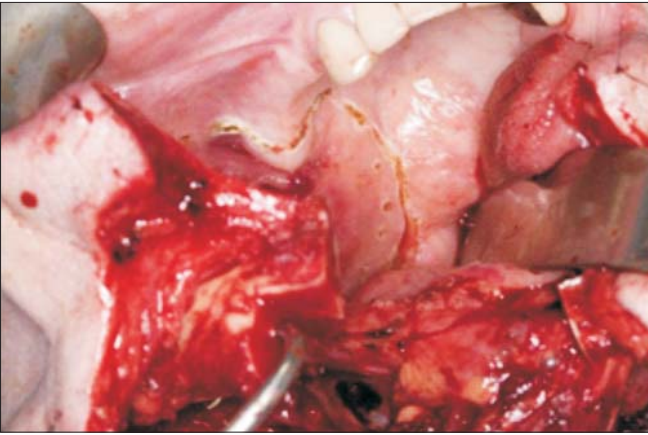
**Figure 1.** Measuring 1 cm outer limit circumference of the tumor



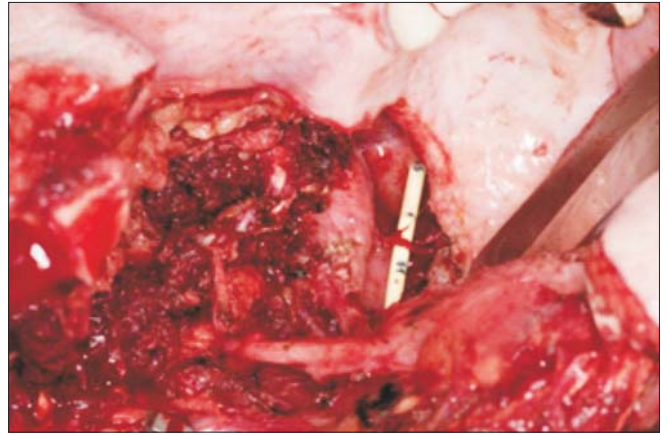
**Figure 2.** Demarcation of the resection margins

Corresponding author:

Raluca Dragomir, M.D., D.M.D.  
SHO in Oral and Maxillofacial Surgery  
Brighton and Sussex University Hospitals  
E-mail: draluca@yahoo.com



*Figure 3. Demarcation complete*



*Figure 4. Resection completed*