

Acute diverticulitis – an unusual cause of liver abscesses in a young man: a case report

N. Al Hajjar¹, D. Crișan², M. Grigorescu², P. Boruah³

¹“Iuliu Hatieganu” University of Medicine and Pharmacy, Regional Institute of Gastroenterology and Hepatology, 3rd Surgical Clinic

²“Iuliu Hatieganu” University of Medicine and Pharmacy, Regional Institute of Gastroenterology and Hepatology, 3rd Medical Clinic

³Regional Institute of Gastroenterology and Hepatology, 3rd Surgical Clinic

Cluj-Napoca, Romania

Rezumat

Diverticulita acută - un caz neobișnuit de abces hepatic la un individ tânăr - prezentare de caz

Abcesele hepatice reprezintă o complicație rară a bolii diverticulare sigmoidiene și pun uneori probleme semnificative de diagnostic diferențial al formațiunilor focale hepatice. Prezentăm cazul unui pacient de sex masculin în vârstă de 42 de ani, internat pentru durere în hipocondrul drept, febră, astenie, diaree și scădere în greutate, simptome debutate cu 3 săptămâni înaintea prezentării la medic. Examenul obiectiv a relevat sensibilitate la palpare la nivelul hipocondrului drept și fosei iliace stângi și febră (39 grade C). Examinările de laborator au evidențiat sindrom inflamator marcat, leucocitoză, trombocitoză, modificare a funcției hepatice. Ecografia abdominală a relevat formațiuni focale inomogene și îngroșarea peretelui sigmoidian. Examinările de tip tomografie computerizată și prin rezonanță magnetică au descris leziunile ca fiind abcese hepatice și au relevat de asemenea tromboza de venă portă dreaptă. Aspectul modificărilor sigmoidiene a fost sugestiv pentru diverticulita acută cu perisigmoidită, stenoză și abces.

S-a intervenit chirurgical, s-a practicat rezecție sigmoidiană și puncta abceselor hepatice, dar în contextul absenței aspiratului purulent, nu s-a considerat oportună rezecția leziunilor hepatice. Postoperator, în contextul tratamentului antibiotic, pacientul a prezentat colită pseudomembranoasă, care a impus modificarea schemei de tratament. Evoluția a fost pozitivă sub noua schemă de tratament, cu ameliorarea netă a aspectului leziunilor hepatice.

Cuvinte cheie: diverticulită acută, abcese hepatice, rezecție sigmoidiană, colită pseudomembranoasă

Abstract

Liver abscess is a rare complication of sigmoid diverticulitis and must be considered within the differential diagnosis. We report a case of a male patient, age 42, admitted to our hospital with chief complaints of a dull pain in upper right abdominal quadrant, fever, weakness, diarrhoea and weight loss of approximately 3 weeks duration. Physical examination on initial work-up revealed tenderness on palpation in upper right abdomen, and left iliac fossa and a 39 degrees C fever. Biochemistry showed marked inflammatory syndrome, leukocytosis, increased level of platelets, altered liver function. Ultrasound examination revealed inhomogeneous liver nodules and the thickening of the sigmoid wall. Further CT scan examination and MRI confirmed the lesions as being abscesses and also revealed thrombosis of right portal vein. The sigmoid wall lesions proved to be an acute diverticulitis with

Corresponding author:

Dana Crișan, MD
Regional Institute of Gastroenterology and
Hepatology - 3rd Medical Clinic
19-21 Croitorilor Street, 400162
Cluj-Napoca, Romania
E-mail: danacrisan1@yahoo.com

perisigmoiditis, stenosis and abscess. Patient underwent a surgical treatment of sigmoid resection, but the puncture of the abscesses revealed no pus at aspiration, making the surgical excision of the lesions unnecessary. After the surgery, during the antibiotic treatment, the patient developed pseudomembranous colitis treated with specific antibiotics. The evolution under this treatment was positive and the aspect of the liver lesions was improved.

Key words: acute diverticulitis, liver abscess, sigmoid resection, pseudomembranous colitis

Introduction

Bacterial abscess of the liver is relatively rare. In the United States, the incidence of pyogenic liver abscess is estimated to be 8-15 cases per 100,000 persons.

Regarding the age, with the development of better diagnostic techniques, early antibiotic administration and the improved survival of the general population, the demographic has shifted toward the sixth and seventh decades of life, while prior to the antibiotic era, liver abscess was most common in the fourth and fifth decades of life.

Etiology is dominated by biliary disease. Extrahepatic biliary obstruction leading to ascending cholangitis and abscess formation is the most common cause. There is also the possibility of infection via the portal system (portal pyemia). The infectious process originates within the abdomen and reaches the liver by embolization or seeding of the portal vein. Any source of intra-abdominal abscess, such as acute diverticulitis, inflammatory bowel disease, appendicitis can lead to portal pyemia and hepatic abscesses. In this context, diverticulitis of the sigmoid colon as the source of hepatic abscess, is even more uncommon.

Diagnostic and treatment approach of this pathologic chain involves interdisciplinarity. Clinical data correlated with biochemical data and imagery methods as ultrasonography, CT and MRI are usually needed for the diagnosis. Treatment implies the involvement of a surgeon, a gastroenterologist, an interventional radiologist and an infectious disease specialist.

Case presentation

A 42 years old patient was admitted to our hospital in the department of internal medicine for pain in the right upper quadrant, diarrhoea, asthenia, fever (39gr C), chills, weight loss.

Physical examination revealed an overweight patient, altered general status, pale, sweaty skin, tender left iliac fossa and right hypocondrium, hepatomegaly, normal consistency. The blood tests revealed increased white blood cells with neutrophiles (8400/mm³), mildly increased level of platelets, a marked inflammatory syndrome: accelerated ESR and CRP, and altered liver function with hepatocytolysis and

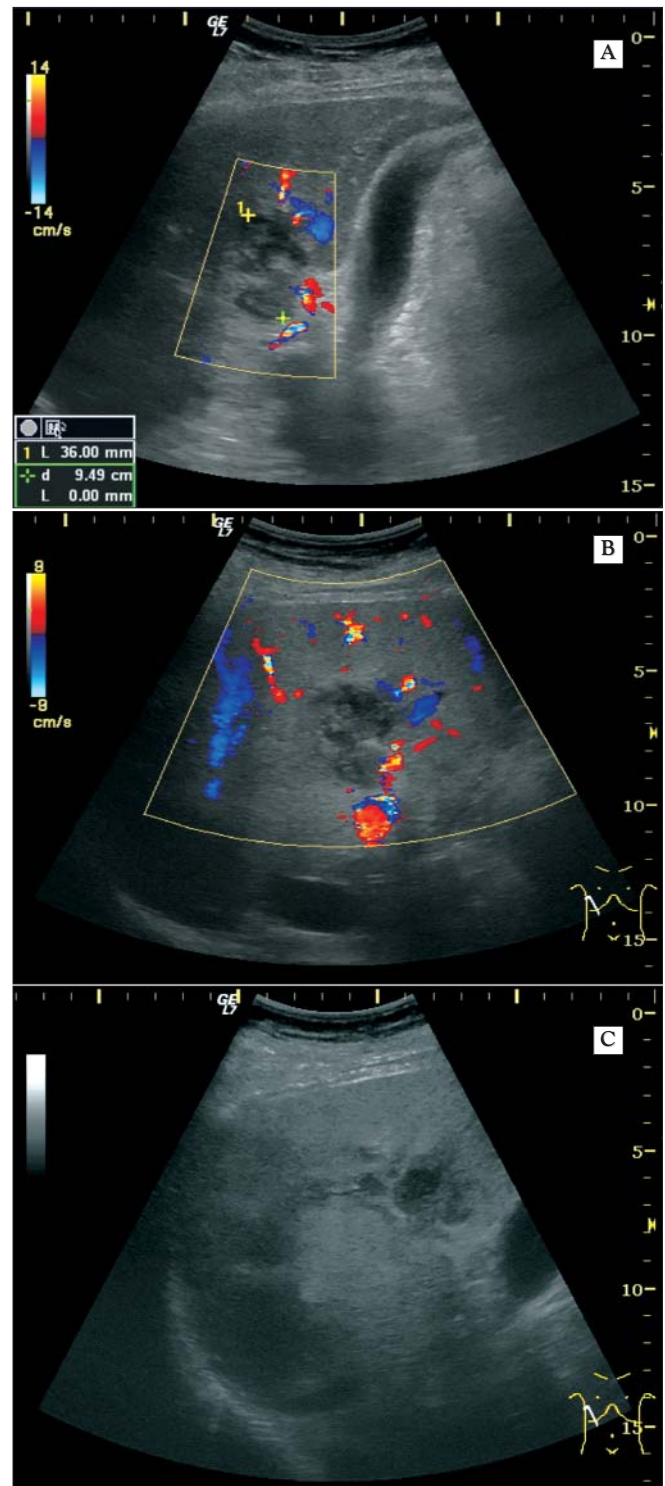


Figure 1. (A,B,C) Ultrasound aspects

colestasis. Urinalysis revealed leukocytes and erythrocytes.

Abdominal ultrasound revealed nodular, inhomogeneous liver structure with multiple lesions in the V, VII, VIIIth segments, dimensions ranging between 20 and 50 mm with possible signification of liver abscesses or metastases. In the left iliac fossa, the imagist described thickening of sigmoid walls, positive Doppler signal (diverticulitis?). (Fig. 1)

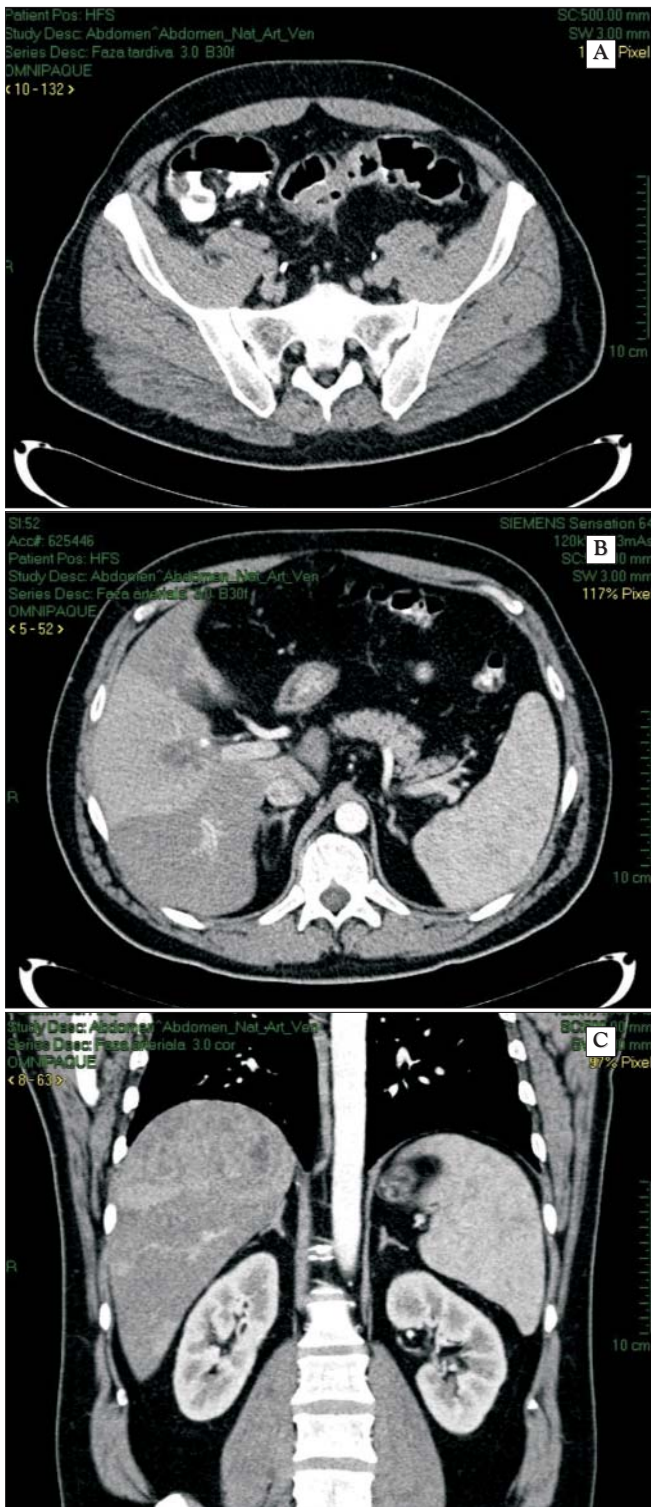


Figure 2. (A,B,C) Abdominal CT aspects

In order to elucidate the diagnosis, contrast-enhanced abdominal CT was performed: inhomogeneous hepatic structure, especially in the Vth and VIIth segments, with nodular images, plus segmental parietal thickening along 3 cm of the proximal end of the sigmoid colon. The aspect was suggestive for multiple liver abscesses in the Vth and VIIIth segments, without completely ruling out another etiology. (Fig. 2)

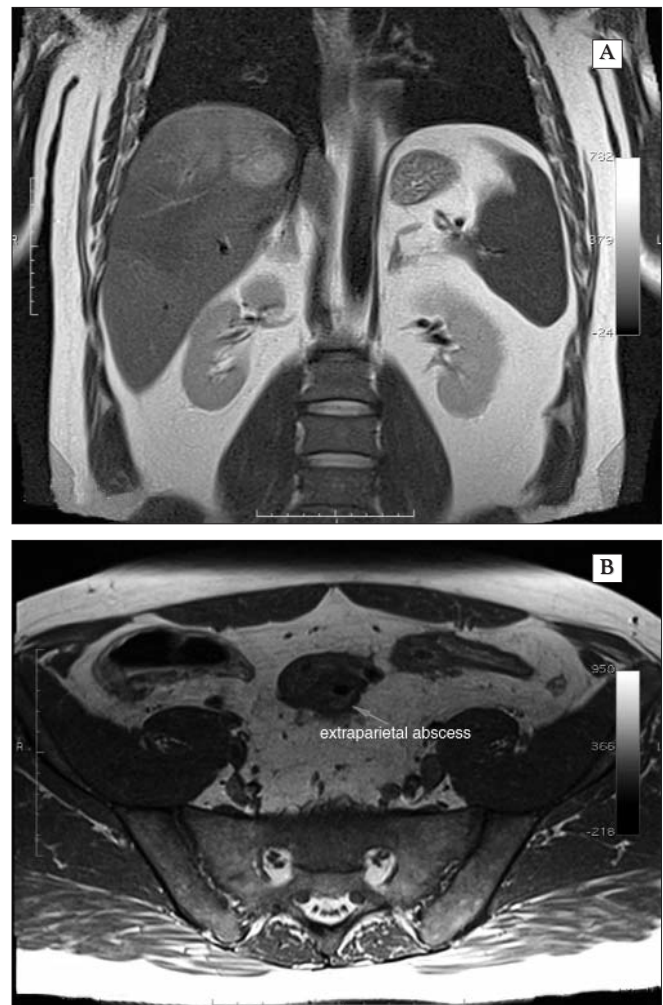


Figure 3. (A,B) MRI aspects

We completed the investigations with MRI because of the uncertain aspect at the CT scan, which showed multiple lesions with peripheral halo and intermediate signal in the liver: a 5 cm lesion in the Vth segment, near the liver hilum, no thrombosis of right portal vein; the lesion is in contact with the hepatic artery; VIIth and VIIIth segments: 4 lesions of 8 to 32 mm and multiple lesions of less than 5 mm in diameter. In pelvis: sigmoid wall thickening along 16 cm of its length, with diverticula, sigmoid stenosis, of probably inflammatory cause, 18 cm from the anal orifice, where a 15 mm abscessed diverticulum is located; diffuse infiltrative changes of the perisigmoidal area; perisigmoidal adenopathies (measuring 5-11 mm in diameter); sigmoid wall adherent to an ileal loop. Conclusion: intra-hepatic abscesses in the VIIth, VIIIth, Vth segments, with periportal inflammatory infiltrate and diverticulitis with abscesses and stenosis of the sigma. (Fig. 3)

A complex antibiotic treatment was initiated. As the patient had acute diverticulitis with abscess and stenosis of the sigma, he had indications of surgical treatment. He was addressed to the surgery department for the appropriate treatment.

Surgery started with a median subxifoid-suprapubic incision. At the level of sigmoid colon multiple abscessed

diverticula, retraction of the mesosigmoid, perisigmoiditis and adherences to an ileal loop, urinary bladder and pelvic peritoneum were observed. In the liver: 5 cm abscess in the Vth segment, several smaller abscesses in the right lobe. The Vth segment lesion was punctured – no pus on aspiration. Pelvic adhesiolysis with removal of the peritoneum covering the above mentioned ileal loop was performed followed by segmentary sigmoid resection with termino-terminal colo-rectal anastomosis and finally, hemostasis, drainage, laparo-suture. (Fig. 4)

In evolution, abdominal ultrasound repeated showed the same aspect of the liver lesions but with right portal vein thrombosis added. Antibiotic treatment was continued associated with anticoagulant treatment. Patient was recommended for percutaneous drainage of the liver lesions, but he refused.

Three weeks after surgery, patient started diarrhoea with mucus associated with tenesmuses. He was suspected of pseudomembranous colitis. Infectious disease consult tested positive for *Clostridium Difficile* enterotoxin A confirming the suspicion. A new antibiotic treatment adressed to pseudomembranous colitis was initiated with positive evolution.

MRI check-up at one month: Vth liver abscess had similar size - 4,5cm, but better defined necrosis area, with irregular wall; the VIIth segment abscess had smaller size and lower intensity.

Evolution of patient was positive regarding the clinical aspect and the biochemical status: normal values of inflammatory tests, normal liver function. Ultrasound revealed after two months, the decreased dimensions of the Vth segment abscess (16 mm) and no abscesses in the VII th segment.

Discussions

The peculiarities of this case were the presence of:

- a diverticular disease in a young patient
- the appearance of the liver abscesses in a young patient
- a rare etiology of liver abscesses (infection via portal pyemia)
- right portal vein thrombosis which implies therapeutical controversies
- pseudomembranous colitis that require careful therapeutic decisions

Sigmoid diverticulitis is common in the western countries; its incidence is increasing as the average age of the population increases. A study developed in USA (1), observed 322 patients admitted with a diagnosis of colonic diverticulosis. Of these patients, only 6 % were 40 years of age or younger. The criteria for acute diverticulitis were met by 86 patients, 17 of whom were 40 years of age or younger. The younger group had disproportionately more men.

Another study recently developed in Germany (2) studied 1019 patients with sigmoid diverticulitis, 89 (8,73%) being under the age of 40. Regarding the outcome of the disease, acute sigmoid diverticulitis in younger patients is not more aggressive and has no higher risk of perforation or need for emergency surgery compared to older patients was

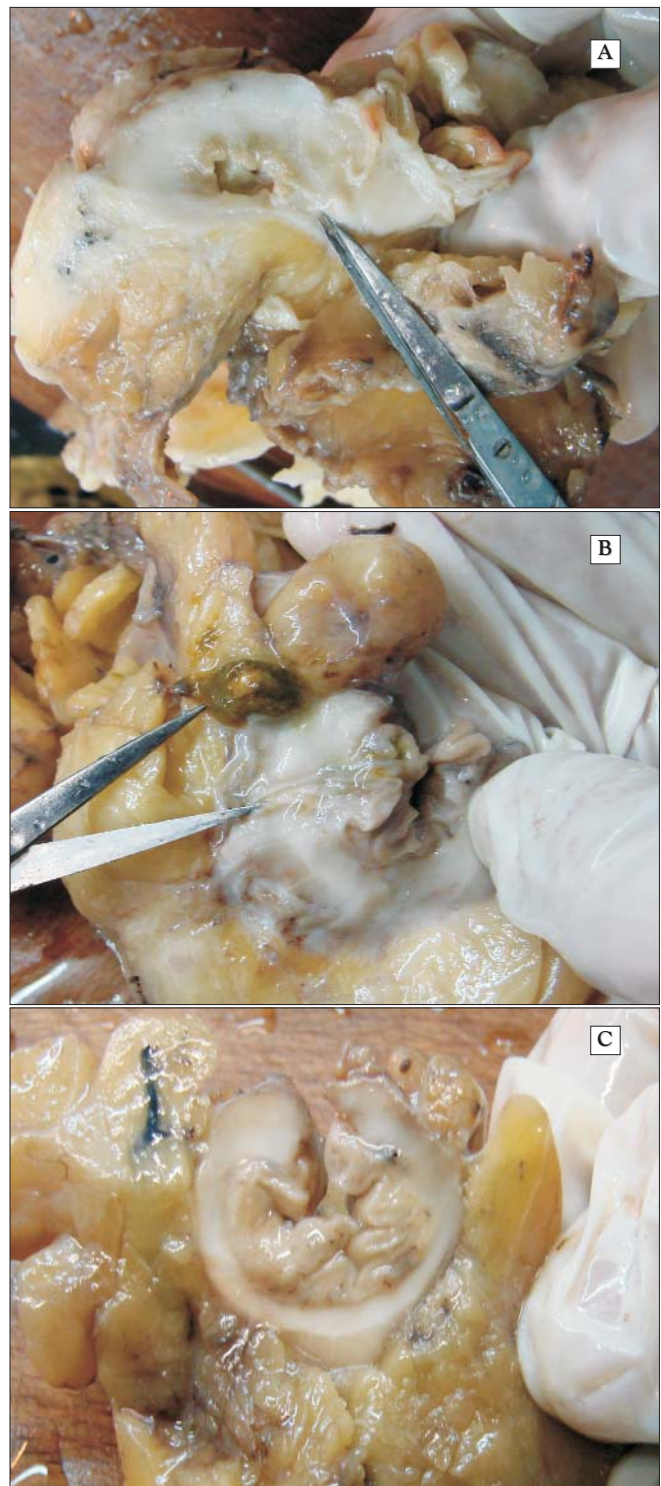


Figure 4. (A,B,C) Intraoperative aspects

the conclusion of these resechers.

These data are similar to the results of a study from Finland (3) developed on 1081 patients with diverticulitis, which proved that only 19% of the patients under 50 years were admitted to the hospital with complications, while 36% from the patients having more than 50 years had complications and the course of the disease in patients aged less than 50 years is

not more aggressive than in older patients.

There are also some controversial results, like those revealed by Pautrat and colab (4) on 284 patients who proved that diverticulitis in patients younger than 40 years seems to have a particularly aggressive and fulminant course and requires early surgical procedures for complications in 40 % of cases.

Data related to the outcome of acute diverticulitis depending on the age and sex of patients were also provided by a research team from Switzerland (5) who enrolled 226 patients urgently hospitalized for acute left colonic diverticulitis, 21% younger than 50 years of age. Twenty nine percent were operated on during their first hospitalization, of whom 15% were under 50; 28% younger than 50 years of age experienced recurrences or complications after their first discharge, compared with only 13% of patients older than 50 years of age.

Acute diverticulitis is an uncommon cause of liver abscesses in general population. Hepatic abscesses is also a relatively rare condition with an incidence rate of 0,008% to 0,016% in hospital admissions. (6) Liver abscesses are found in 90 % of cases associated with older patients (more than 50 years old) (6, 7). In this context, the age of our patient makes him unusual for the demographical data of the disease.

Correlation between the older ages and the presence of liver abscesses is also mentioned in other studies developed (8, 9).

The etiology of liver abscesses is not all the time easy to specify. A quite similar case to ours regarding the pathology was described in the literature, but the differential diagnosis of the liver nodules etiology imposed in that case the need for liver biopsy (10).

Pathogenesis of hepatic abscesses often involves biliary obstruction (31,6%) and portal vein pylephlebitis secondary to an intraabdominal source (21,8%) (11). Less frequent etiologies include hematogenous dissemination through hepatic artery (14,5%), direct extension (5.1%), primary hepatic disease (5.1%) and cryptogenic causes (22%).

The case we described developed the infection of the liver through the portal pyemia, taking part to the uncommon causes of the liver abscesses. He also developed associated to abscesses a pylephlebitis. Thrombophlebitis of the portal vein and its branches is referred to as pylephlebitis, and it is frequently associated with an intra-abdominal inflammatory process (12, 13). The most common intra-abdominal etiologic factors are diverticulitis, appendicitis, regional enteritis, ulcerative colitis, omphalitis, necrotizing pancreatitis, cholangitis, and foreign body perforation. Surprisingly, liver abscesses may also have extraabdominal etiology, as it is the case of septic metastazation from odontogenic suppurations (14).

The treatment for pylephlebitis includes broad spectrum antibiotics, anticoagulation, and surgical treatment of the source of infection, if needed. The use of anticoagulation has been controversial (15). The role of anticoagulation is controversial. Baril et al. reported that better outcomes are achieved in patients who receive anticoagulation therapy (16). Another point of view is that anticoagulation in patients with thrombus isolated to the portal vein and normal clotting function

may be unnecessary, as reported in a retrospective study of 44 cases (17). Anticoagulation is not performed without risk, especially in the immediate postoperative period, and thus the benefits are all speculative (18). Many authors consider now that heparin treatment is essential for stopping the progression of the thrombosis and eliminating the source of septic emboli (19,20,21,22). Prompt surgical intervention is required only if there is evidence for synchronous liver abscesses, a complication of diverticulitis (as it was in our case), intestinal, or mesenteric ischemia, or when medical conservative therapy fails).

Related to the presence of pylephlebitis, a case report from literature describes of a rare association of septic thrombosis within the portal, inferior mesenteric and superior mesenteric veins during acute sigmoid diverticulitis with abdominal abscesses (12).

The treatment of acute diverticulitis and of liver abscesses needs a complex antibiotherapy, which sometimes implies risks of adverse reactions and complications. Our patient developed a pseudomembranous colitis during the antibiotic treatment which is not a rare pathology per se, but in our case determined a difficult therapeutical approach in a patient with septic collections. The first type of therapy was replaced by a treatment proper for the newly appeared disease, recommended for a longer period of time, with a positive evolution for the patient.

Conclusion

Acute diverticulitis and liver abscesses are not characteristic for the old patients. It is a pathology with complex mechanism, sometimes difficult to diagnose and treat, but with good results when being managed by a team formed by a gastroenterologist, an interventional radiologist, an infectious disease specialist and a surgeon.

References

1. Acosta JA, Grebenc ML, Doberneck RC, McCarthy JD, Fry DE. Colonic diverticular disease in patients 40 years old or younger. *Am Surg.* 1992;58(10):605-7.
2. Ritz JP, Lehmann KS, Stroux A, Buhr HJ, Holmer C. Sigmoid Diverticulitis in Young Patients-A More Aggressive Disease than in Older Patients? *J Gastrointest Surg.* 2011 Feb 12. [Epub ahead of print]
3. Mäkelä JT, Kiviniemi HO, Laitinen ST. Acute sigmoid diverticulitis in young patients. *Hepatogastroenterology.* 2009;56(94-95):1382-7
4. Pautrat K, Bretagnol F, Hutten N, de Calan L. Acute diverticulitis in very young patients: a frequent surgical management. *Dis Colon Rectum.* 2007;50(4):472-7
5. Ambrosetti P, Robert JH, Witzig JA, Mirescu D, Mathey P, Borst F, et al. Acute left colonic diverticulitis: a prospective analysis of 226 consecutive cases. *Surgery.* 1994;115(5):546-50.
6. Rubin RH, Swartz MN, Malt R. Hepatic abscesses: Changes in clinical bacteriologic and therapeutic aspects. *Am J Med* 1974;75:601-609.
7. Conter RL, Pitt HA. Differentiation of pyogenic from amebic hepatic abscesses. *Surg Gynecol. Obstet* 1986;162:114-120.

8. Lodhi S, Sarwari AR, Muzammil M, Salam A, Smego RA. Features distinguishing amoebic from pyogenic liver abscess: a review of 577 adult cases. *Trop Med Int Health*. 2004;9(6):718-23.
9. Conter RL, Pitt HA, Tompkins RK, Longmire WP Jr. Differentiation of pyogenic from amoebic hepatic abscesses. *Surg Gynecol Obstet*. 1986;162(2):114-20.
10. Suna C, Grünenberger F, Schlienger JL, Roedlich MN, Stanciu S, Blaj S. Complicated sigmoid diverticulitis. *Rom J Intern Med*. 2007;45(1):93-6.
11. Brodine WN, Schwartz SI. Pyogenic hepatic abscess. *N Y State J Med*. 1973;73(12):1657-61.
12. Nobili C, Uggeri F, Romano F, Degrate L, Caprotti R, Perego P, et al. Pylephlebitis and mesenteric thrombophlebitis in sigmoid diverticulitis: medical approach, delayed surgery. *Dig Liver Dis*. 2007;39(12):1088-90. Epub 2007 Jul 23.
13. Triantopoulou C, Komitopoulos N, Polyzou, Maniatis P, Varsamis E, et al. Pylephlebitis associated with intrauterine device: CT evaluation *Eur J Radiol Extra*. 2005;55(3):93-96
14. Juncar M, Popa AR, Lung T, Onişor F. Septic metastases of suppuration of odontogenic origin. *Chirurgia (Bucur)*. 2011; 106(3):359-64. [Article in Romanian]
15. Nishimori H, Ezoe E, Ura H et al. Septic thrombophlebitis of the portal and superior mesenteric veins as a complication of appendicitis: report of a case. *Surg Today*. 2004;34(2):173-6.
16. Baril N, Wren S, Radin R, Ralls P, Stain S. The role of anticoagulation in pylephlebitis. *Am J Surg*. 1996;172(5):449-52
17. Chang TN, Tang L, Keller K, Harrison MR, Farmer DL, Albanese CT. Pylephlebitis, portal-mesenteric thrombosis, and multiple liver abscesses owing to perforated appendicitis. *J Pediatr Surg*. 2001;36(9):E19.
18. Duffy FJ Jr, Millan MT, Schoetz DJ Jr, Larsen CR. Suppurative pylephlebitis and pylethrombosis: the role of anticoagulation. *Am Surg*. 1995;61(12):1041-4.
19. Kumar S, Sarr MG, Kamath PS. Mesenteric venous thrombosis. *N Engl J Med*. 2001;345(23):1683-8.
20. Duffy FJ Jr, Millan MT, Schoetz DJ Jr, Larsen CR. Suppurative pylephlebitis and pylethrombosis: the role of anticoagulation. *Am Surg*. 1995;61(12):1041-4.
21. Condat B, Pessione F, Helene Denninger M, Hillaire S, Valla D. Recent portal or mesenteric venous thrombosis: increased recognition and frequent recanalization on anticoagulant therapy. *Hepatology*. 2000;32(3):466-70.
22. Grisham A, Lohr J, Guenther JM, Engel AM. Deciphering mesenteric venous thrombosis: imaging and treatment. *Vasc Endovascular Surg*. 2005;39(6):473-9.