

A Rare Cause of Acute Massive Lower Gastrointestinal Bleeding

G. Constantinescu, I. Grințescu, L. Stanciulescu, M. Ilie, M. Beuran, A. Chiotoroiu

Clinical Emergency Hospital Bucharest, Romania

Rezumat

Cauză rară de hemoragie digestivă inferioară masivă

Chiar dacă, hemoragia digestivă inferioară (HDI) se poate manifesta ca o hematochezie banală, hemoragia masivă și șocul hemoragic pot să apară. HDI acută, masivă este definită ca o sângerare de durată recentă care are sursa sub ligamentul lui Treitz și cuprinde: pasaj de sânge roșu/hematochezic în volum crescut prin rect, instabilitate hemodinamică și șoc cu o scădere inițială a hemoglobinei sub 6 g/dl sau mai puțin, transfuzie de cel puțin 2 U de masă eritrocitară și continuarea sângerării mai mult de 3 zile, cu resângerare semnificativă în mai puțin de o săptămână. Localizarea leziunii Dieulafoy în colon este foarte rară, dar ar trebui considerată în diagnosticul diferențial al HDI. Această lucrare prezintă cazul unui pacient în vârstă de 58 ani cu HDI masivă. Colonoscopia a fost efectuată în urgență, cu o pregătire precară a colonului. Depistarea leziunii Dieulafoy, într-un colon plin cu sânge a fost salutară și a prevenit apariția șocului hemoragic. Hemostaza s-a efectuat eficient prin injectarea de agent sclerozant în leziunea angiodisplazică. Am preferat colonoscopia ca primă alegere datorită disponibilității și oportunității de hemostază în caz de identificare a sursei. Angiografia urma să fie efectuată în caz de eșec al primei metode. Definiția, prezentarea clinică și tratamentul leziunii Dieulafoy sunt discutate în continuare.

Cuvinte cheie: hemoragia digestivă inferioară, colonoscopie, leziunea Dieulafoy

Abstract

Even if lower gastrointestinal bleeding (LGIB) can present as trivial haematochezia, massive hemorrhage with shock may occur. Acute massive LGIB is defined as bleeding of recent duration that originates beyond the ligament of Treitz and encompasses: passage of a large volume of red or maroon blood through the rectum, haemodynamic instability and shock, initial decrease in haematocrit level of 6 g/dL or less, transfusion of at least 2 U of packed red blood cells, bleeding that continues for 3 days or significant rebleeding in 1 week. This report presents the case of a 58-year-old man with massive LGI bleeding. Colonoscopy was performed in emergency with a poor colonic preparation, but the examiner fortunately and with difficulty managed to identify the source of the haemorrhage - a Dieulafoy's lesion of the right colon. The bleeding was successfully stopped permanently by injecting sclerosing agents into the spurting vessel. We have preferred colonoscopy as our first choice of investigation due to the facile availability and the opportunity of endoscopic haemostasis in case of finding the source of bleeding. Angiography was planned in case of failure of the first method. The definition, clinical presentation, and treatment of Dieulafoy's lesion are further discussed.

Key words: lower gastrointestinal bleeding, colonoscopy, Dieulafoy's lesion

Corresponding author: Alexandru Chiotoroiu, MD
Department of Surgery, Emergency Hospital
Bucharest, Romania
E-mail: chiotoroiu@yahoo.com

Case report

The most common causes of acute LGIB are diverticulosis and angiodysplasia.

We present the case of a 58-year-old man that came to the emergency hospital because of rectal bleeding starting two days prior to admission. His medical history was significant only for high blood pressure. The patient had some medical knowledge and was firmly convinced the bleeding had a haemorrhoidal cause. He demanded us to shorten the investigation and therapy time, preferring to be treated as outpatient. He had no history of surgery, use of medications, allergy, or recent travel; his family history was similarly unremarkable. He smoked and drank alcohol occasionally but didn't use recreational drugs. Examination showed a haemodynamically stable patient, tight pale skin and a value of 11 g/dl of haemoglobin. His abdomen was soft, lax, non-tender, and non-distended; bowel sounds were normal. Rectal examination showed a red-coloured stool in the rectum - haematochezia suggesting the gravity of the situation.

We admitted the patient in a private ward according to his express desire; he underwent upper GI endoscopy with a normal result and we scheduled him to start colonoscopy preparation in the afternoon, aiming to perform the examination the next day.

A few hours later, at the time he was supposed to start the colonoscopy preparation, the bleeding became intensive, minor signs of haemodynamic instability occurred. He hardly accepted to be transferred from his private ward in an intensive care unit. He received 2 units of packed erythrocytes and saline solution but he vomited at the trial of Macrogol ingestion as colonoscopy preparation. An urgent rectosigmoidoscopy exam was performed but no source of bleeding was found.

The next day, the haemorrhage was continuous, severe and was definitely not coming from the upper GI tract; the haemoglobin value dropped to 7 g/dl after 4 units of packed erythrocytes and we had to decide between two further examination methods: urgent angiography and total colonoscopy. We decided for a rapid colonoscopy preparation with 2 litres of enema with 5 % glycerine on a patient with signs of haemodynamic instability (pale skin, BP of 80/40 mm Hg, HR 130 bpm).

The colonic mucosa was covered with fresh blood coming from the upper segments; every centimetre was washed with water and examined. Small diverticula were seen on sigmoid colon but without signs of bleeding. Fortunately in the ascending colon, at the hepatic flexure, was hardly seen an abnormal visible vessel eroding from the submucosa - Dieulafoy's lesion, with oozing haemorrhage. (Fig. 1, 2)

Epinephrine 1:10000 was injected around the lesion and pure Alcohol 33% 2 ml central in the vessel with the ceasing of the bleed. (Fig. 3, 4, 5)

Theoretically we had to add a method of stable haemostasis. We chose only sclerotherapy due to the fact that we had a 160 cm length colonoscope and for the moment we didn't possess haemoclips for this dimension. We also feared that withdrawing the colonoscope and replacing it with a shorter one- fit for the

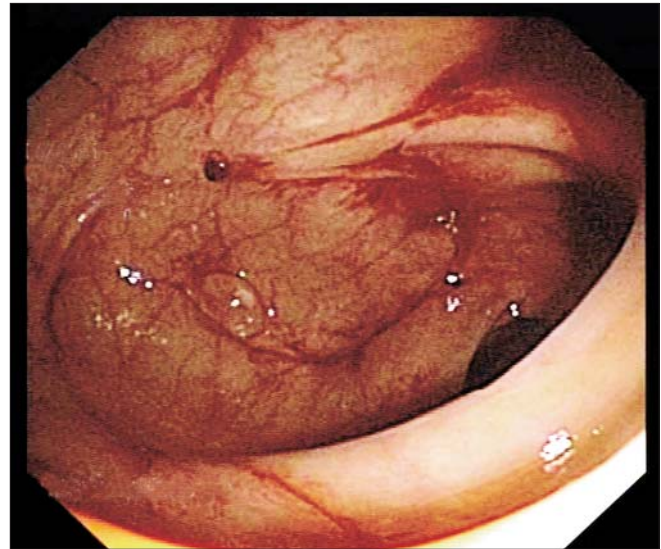


Figure 1. Difficult identification of Dieulafoy's lesion after washing

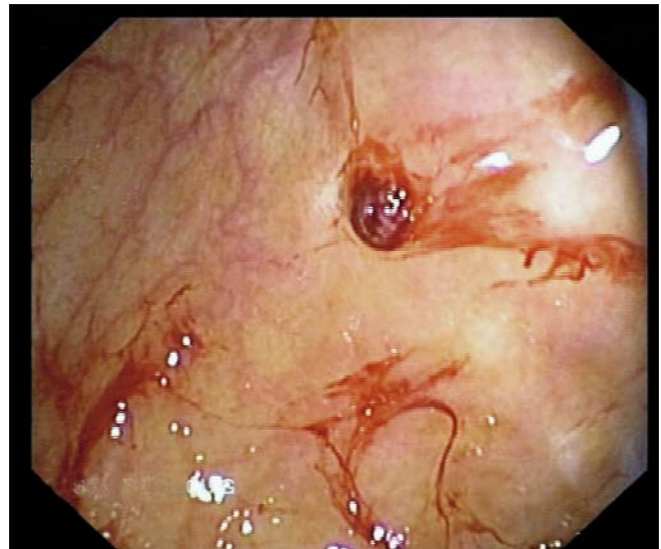


Figure 2. Bleeding Dieulafoy's colonic lesion

haemoclips, might cause us to miss the lesion, in an unstable patient with a poor preparation.

The patient became haemodynamically stable and his haemoglobin increased to 8 g/dl. The next day, the clinical state was significantly improved. He didn't realize the severe situation that jeopardized his life, requesting urgently the discharge note. He was discharged with haemoglobin of 10.5 g/dl. Six months after admission he was asymptomatic without any episode of repeated LGIB.

Dieulafoy's lesion (exulceratio simplex Dieulafoy) consists of a protuberant, tortuous, serpiginous, and abnormally wide artery located in the submucosa of the gastrointestinal tract that erodes and bleeds (1,3). Approximately 75% of Dieulafoy's lesions occur in the upper part of the stomach within 6 cm of the gastro-oesophageal junction, most commonly in the lesser

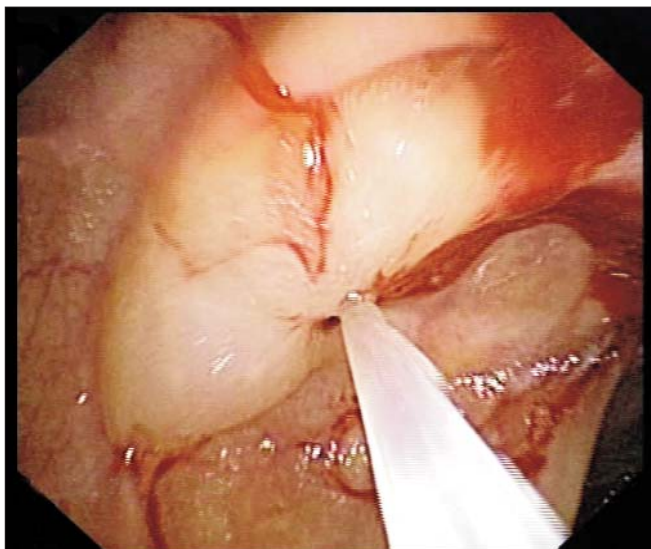


Figure 3. Efficient haemostasis

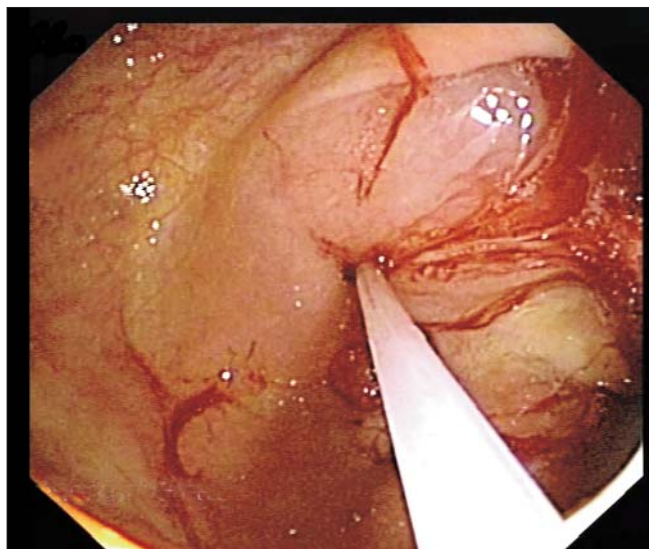


Figure 4. Alcohol injection

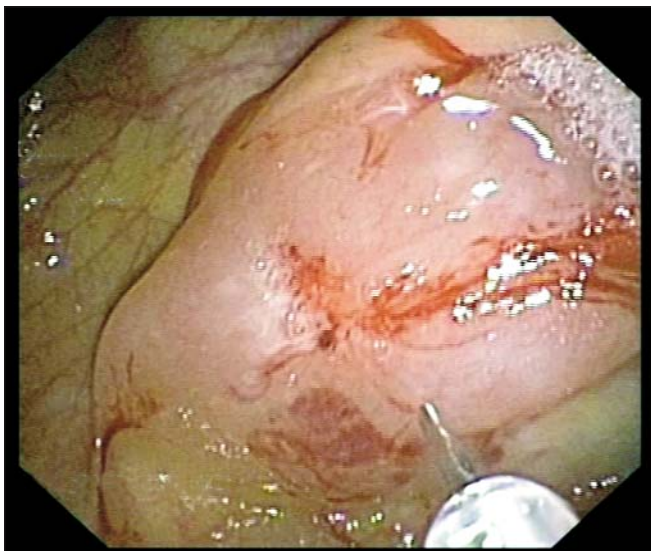


Figure 5. Final appearance after injection

curvature. Extragastric lesions have historically been thought to be uncommon, but have been identified more frequently in recent years, likely due to increased awareness of the condition. The duodenum is the most common location (14%) followed by the colon (5%), surgical anastomoses (5%), the jejunum (1%) and the oesophagus (9,10). The characteristic clinical presentation of a Dieulafoy's lesion involves recurrent, painless, and massive gastrointestinal bleeding in a hypotensive patient (8). Even if it is rare, Dieulafoy's lesion should always be considered in the differential diagnosis of LGI bleeding. Endoscopically, it is not easy to recognize, especially in acute bleeding, therefore sometimes multiple views have to be performed (2,4,5). Angiography may be helpful during haemorrhage. Treatment involves epinephrine injection associated with alcohol, bipolar/monopolar electro-

coagulation, heater probe, laser photocoagulation or haemoclipping (6,7). In case these methods fail, surgery remains the only option (11).

In our case, colonoscopy was decided in a patient with severe haematochezia without cause, as primarily a colonic cause must be searched while angiography remained in standby. The alternative in case of negative colonoscopy and angiography was surgery, even with total colectomy.

Another favourable condition was the localization of the lesion in the colon, allowing endoscopic haemostasis. If the small bowel had been the source of the bleeding, the immediate unavailability of enteroscopy with a negative angiography result would have made the treatment very challenging.

Technically at colonoscopy, the chance of finding a millimetre-wide lesion in a colon filled with blood was beneficent and rapidly solved the patient's problems.

Conclusion

Dieulafoy's lesion is a rare cause of LGIB demanding rapid identification during acute haemorrhage. It accounts for massive digestive tract haemorrhages with a high mortality rate and it may occur in any segment of the digestive tract. Endoscopy specialists should actually suspect this diagnosis and therefore carry out a very persistent examination in patients who present no definite bleeding site.

In our case beginning with colonoscopy over angiography was effective and salutary.

Lesion localization in the colon and the detailed, meticulous and fortunate colonoscopy are the key issues that saved the patient's life.

References

1. Baettig B, Haecki W, Lammer F, Jost R. Dieulafoy's disease: endoscopic treatment and follow up. *Gut*. 1993;34(10):1418-21.

2. Brown GR, Harford WV, Jones WF. Endoscopic band ligation of an actively bleeding Dieulafoy lesion. *Gastrointest Endosc.* 1994;40(4):501-3.
3. Chen JJ, Changchien CS, Lin CC. Dieulafoy's lesion of the jejunum. *Hepatogastroenterology.* 1999;46(27):1699-701.
4. Gayer C, Chino A, Lucas C, Tokioka S, Yamasaki T, Edelman DA, et al. Acute lower gastrointestinal bleeding in 1,112 patients admitted to an urban emergency medical center. *Surgery.* 2009;146(4):600-6; discussion 606-7. doi: 10.1016/j.surg.2009.06.055.
5. Lin HJ, Lee FY, Tsai YT, Lee SD, Lee CH, Kang WM. Therapeutic endoscopy for Dieulafoy disease. *J Clin Gastroenterol.* 1989;11(5):507-10.
6. Loperfido S. Endoscopic hemostasis of gastric bleeding from Dieulafoy's ulcer with histoacryl. *Endoscopy.* 1989;21(4):199-200.
7. Park CH, Sohn YH, Lee WS, Joo YE, Choi SK, Rew JS, et al. The usefulness of endoscopic hemoclippping for bleeding Dieulafoy lesions. *Endoscopy.* 2003;35(5):388-92.
8. Romãozinho JM, Pontes JM, Lérias C, Ferreira M, Freitas D. Dieulafoy's lesion: management and long-term outcome. *Endoscopy.* 2004;36(5):416-20.
9. Strong RW. Dieulafoy's disease--a distinct clinical entity. *Aust N Z J Surg.* 1984;54(4):337-9.
10. Tonea A, Andrei S, Andronesi D, Ionescu M, Gheorghe C, Herlea V, et al. Difficulties in diagnosis and surgical treatment of the angiodysplasia of the gastrointestinal tract. *Chirurgia (Bucur).* 2008;103(5):513-28. Romanian
11. Veldhuyzen van Zanten SJ, Bartelsman JF, Schipper ME, Tytgat GN. Recurrent massive haematemesis from Dieulafoy vascular malformation-a review of 101 cases. *Gut.* 1986;27(2):213-22.