

## Laparoscopic Cholecystectomy for Treating Acute Cholecystitis – Possibilities and Limitations

E. Suliman, R. Palade

Surgical Department I, Emergency University Hospital, Bucharest, Romania

### Rezumat

#### *Colecistectomia laparoscopică în tratamentul colecistitei acute – posibilități și limite*

Studiul a analizat un lot de 1402 C.A., operate în Clinica I Chirurgie S.U.U.B., în perioada 1993-2010. C.L. a fost posibilă în 90% din cazuri, iar conversia la chirurgia deschisă a fost de 10%. Sunt precizate cauzele care au determinat conversia (plastronul pericolecistic – 49%, orientarea anatomică neclară – 46,5%, hemoragia – 9,7%, leziunea iatrogenă a C.B.P. – 0,23%, etc.). Analiza statistică a evidențiat că sexul masculin, grupele de vârstă peste 50 ani, C.A. gangrenoasă și plastronul fibros au reprezentat factori de risc în finalizarea C.L. Reintervensiunile s-au realizat la 20 de bolnavi (1,4%). Mortalitatea postoperatorie a fost zero.

**Cuvinte cheie:** colecistita acută, colecistectomia laparoscopică, conversia la chirurgia deschisă

### Abstract

Our study analysed a batch of 1402 A.C., operated on within the S.U.U.B. First Surgical Clinic between 1993-2010. L.C. was possible in 90% of the cases, and conversion to open surgery was required in 10% of the cases. The causes that

determined the necessity for this conversion were pericholecystic plastron – 49%, unclear anatomical orientation – 46.5%, haemorrhage – 9.7%, iatrogenic injury of the main bile duct – 0.23% etc. Statistical analysis has shown that male gender, over 50 yrs. age groups, gangrenous A. C. and fibrous plastron represent risk factors for the conclusion of L.C. Reinterventions were performed on 20 patients (1.4%). Postoperative mortality was not encountered.

**Key words:** acute cholecystitis, laparoscopic cholecystectomy, conversion to open surgery

### Introduction

Acute cholecystitis (A.C.) is the most frequent complication arising from gallstones. (1,2,3) Laparoscopic cholecystectomy (L.C) has proved to be a “revolutionary” transformation in gallbladder surgery, introducing a new concept, that of “respect for bodily integrity” (4). Given the numerous advantages presented by it, L.C. is considered the “gold standard” in treating gallstones. (1,5,6,7)

However, inflammatory remoulding in A.C. often makes mini-invasive surgery extremely difficult from a technical point of view, or even impossible. That is why, in A.C. the efficiency of L.C. must be judge in comparison to the technical possibilities and to the rational limitations of the method, which mustn't bring further impairment to the life and activity of the patient. (4,8,9)

### Materials and Methods

Our study followed the possibility of treating A.C. patients

Corresponding author:

Emel Suliman, MD  
Surgical Department I  
Emergency University Hospital, Bucharest  
Romania  
E-mail: emel\_suliman@yahoo.com

through L.C., regardless of the anatomical-clinical form, of the pathological context and/or the complications arising during the evolution of the affliction. (10)

For this purpose a batch of 1402 A.C., operated on within the S.U.U.B. First Surgical Clinic between 1993-2010 was observed, following to highlight the pathological aspects, the technical and tactical difficulties regarding the development and evolution of the gallbladder pathological process and the appropriate therapeutic solution for each patient. Thusly, the important aspects related to the possibilities and limitations of L.C. in A.C. could be mentioned.

The study was a retrospective longitudinal one, of the descriptive type.

The data was statistically analysed with the help of Microsoft Office Excel 2010, SPSS 17.0 and MedCalc version 12.3.0. The statistical analysis of the data was performed by applying the  $\chi^2$  test (with various degrees of freedom).

Variable implication (gender, age, anatomical-clinical form of acute cholecystitis, pericholecystic plastron type) as risk factors for converting to open surgery was determined by calculating the odds ratio, with a trust interval of 95%.

## Results

Between 20.10.1993 – 31.12.2010 1402 patients suffering from A.C. were admitted in our clinic, and were operated on through a mini-invasive procedure. L.C. was concluded in 1258 patients (90%), which proves that a laparoscopic approach is possible, with good results. Conversion to open surgery was necessary in 144 patients (10%), in which it was proven intraoperatively that a mini-invasive solution is not appropriate. (Fig. 1)

The diagnosis of acute cholecystitis was established based on the correlation between the intraoperative data and the results of the histopathological exam of the operative sample. The following forms of A.C. were determined:

- "cold" A.C. – 542 cases (39%);
- phlegmonous A.C. – 396 cases (28%);
- gangrenous A.C. – 248 cases (18%);
- hydropathic A.C. – 132 cases (9%);
- heightened scleroatrophic A.C. – 82 cases (6%);
- "porcelain gallbladder" A.C. – 2 cases (both women) (Fig. 2).

The high percentage of "cold" A.C. patients (39%) which received exclusive medical treatment for it is to be highlighted, in which surgical intervention was necessary as a last resort method when the acute inflammatory process reappeared or became more complicated. The same aspects are applicable for patients with scleroatrophic gallbladder, meaning which had a long-term, recurring suffering, which in the end heightened.

In terms of gender distribution of A.C. cases, it is to be noticed that 1029 were females (73%) and only 373 males (27%). The incidence of A.C. was 2.7 times higher in women. (Fig. 3)

Age group distribution of patients showed that most cases appeared in the fourth-eight decades of life, with a

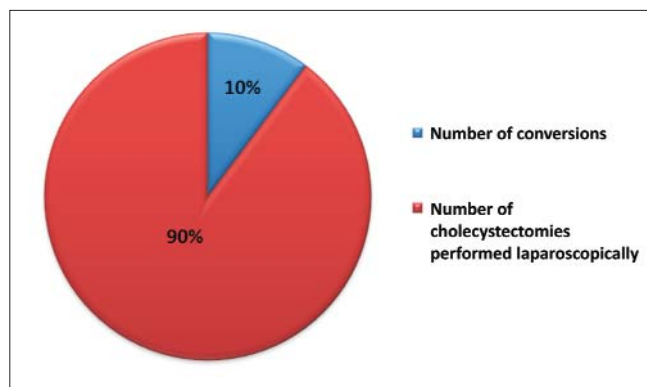


Figure 1. Laparoscopic cholecystectomies and conversions distribution

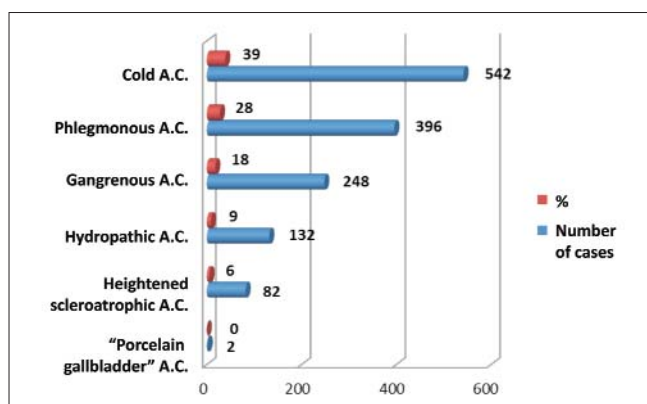


Figure 2. Anatomical-clinical types of acute cholecystitis

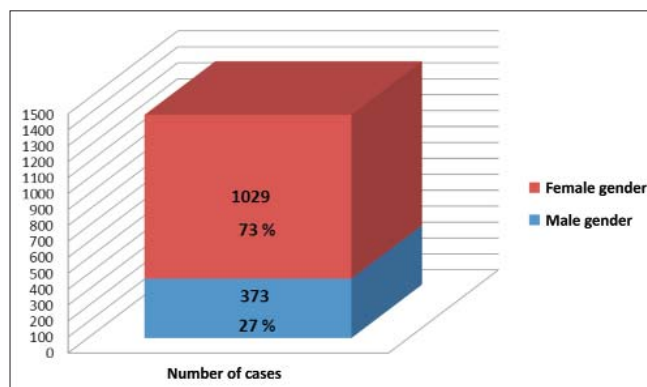
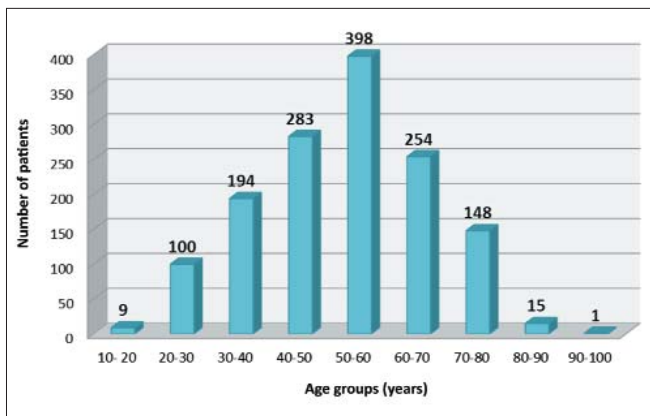


Figure 3. Patient distribution according to gender

maximum of incidence in the sixth life decade (398 cases – 28%). Age minimum and maximum limits were 16 and 98 years respectively. (Fig. 4)

An "open" introduction of the optical trocar was necessary in 88 patients (6%), due to:

- umbilical hernia – 43 cases;
- obesity – 22 cases;
- scarred adherent abdomen – 18 cases;
- postop eventration – 4 cases;



**Figure 4.** Patient distribution according to age groups

- epigastric hernia – 1 case.

A series of afflictions associated with A.C., which in some cases determined technical difficulties in performing the surgical act or surprises in the postoperative evolution of the patient were diagnosed intraoperatively:

- hepatic steatosis or steatofibrosis – 327 cases (23%);
- Fitz – Hugh – Curtis syndrome – 63 cases (4.5%);
- hepatic cirrhosis – 27 cases (2%);
- hepatic haemangioma – 9 cases (0.7%).

Besides L.C., other associated interventions were performed, imposed by pathologies diagnosed especially intraoperatively. The most frequent were:

- viscerolysis – 542 cases (43%);
- adhesiolysis – 120 cases (9.5%);
- the surgical cure of an umbilical hernia – 36 cases (2.8%);
- partial omentectomy – 2 cases.

Out of the numerous anatomical variants and extensive acute inflammatory remodelings of the gallbladder, which created tactical and technical difficulties in performing the surgical act, we mention:

- difficult prehension of the gallbladder – 521 cases (41%);
- pericholecystitis – 380 cases (30%);
- Hartmann pouch – 230 cases (18%);
- difficult handling of the gallbladder – 177 cases (14%);
- topographic peculiarities of the gallbladder – 76 cases (6%);
- peculiar anatomical conformation of the gallbladder – 37 cases (3%).

Anatomical variants, of surgical importance, of the cystic duct and pathological remodelings of the duct created technical difficulties during the L.C. Out of these, worth mentioning are:

- pericystitis – 163 cases (13%);
- infundibulo-cystic lipomatosis – 107 cases (8.5%);
- “accordion” cystic duct – 92 cases (7.3%);
- short cystic duct – 47 cases (3.7%);
- cystic duct lithiasis – 27 cases (2.1%);
- “passageway” cystic duct – 22 cases (1.7%);
- tortuous cystic duct – 21 cases (1.7%);

- abnormal swirling of the cystic duct – 6 cases (0.5%);
- cystic duct gangrene – 3 cases (0.2%);
- cystic duct angled by an arterial chord – 1 case.

Specific problems generated by the cystic artery in L.C. were represented by:

- cystic artery located anterior to the cystic duct – 44 cases (3.5%);
- additional arterial sources on the edges of the cystic fossa – 21 cases (1.7%);
- difficult dissection of the cystic artery, due to fibrosis in the Calot triangle – 9 cases (0.7%);
- voluminous cystic artery, easy mistakable for the right branch of the hepatic artery – 8 cases (0.6%);
- accessory cystic artery – 7 cases (0.5%);
- small calibre, easy negligible cystic artery– 3 cases (0.2%);
- short trunk of the cystic artery (approximately 1 cm), in which situation we suggest haemostasis by clamping the bifurcation branches – 2 cases (0.16%).

In order to prevent haemorrhagic accidents or accidental clipping of the vessels or ducts located near the cystic artery, we performed the dissection of the artery in the immediate proximity of the gallbladder, along a distance long enough to correctly identify the vessel and clipped when we were sure that the identified formation is distributed to the wall of the gallbladder.

In 29 cases, trans-cystic exploration of the main bile duct was required, through cholangiography and/or choledochoscopy, and the following were the determined:

- passageway common bile duct – 12 cases;
- microlithiasis of the main bile duct – 10 cases;
- edematous acute pancreatitis and microlithiasis in the main bile duct – 5 cases;
- edematous acute pancreatitis – 2 cases.

Technical difficulties presented during the dissection of the gallbladder in the cystic fossa were due to:

- lack of a cleavage plane – 541 cases (43%);
- haemorrhage – 105 cases (8%);
- difficult prehensions and handling of the gallbladder – 70 cases (5.6%).

The extraction of the operative probe was performed through:

- the epigastric port – 1226 cases (97%);
- the umbilical orifice – 29 cases (2.8%);
- mini-laparotomy – 3 cases (0.2%).

Draining of the right subhepatic space was performed as a rule, and allowed follow-up and early observation of postop complications (such as haemorrhage, bile leakage).

Acute cholecystopancreatitis was diagnosed in 121 patients (8.6%). In 98 patients (81%), L.C. was performed after clinical and laboratory proved remission of the pancreatic reaction. In 23 cases (19%) a combined endoscopic and laparoscopic intervention (“Rendez-vous” technique) was necessary. Immediate or late complications of the pancreatic pathological process in patient treated through a mini-invasive “Rendez-vous” technique were not registered. (11,12)

In mixt cholecysto-choledochal lithiasis in patients with

A.C. a combined laparoscopic and endoscopic approach was needed in 73 cases, 46 women (63%) and 27 men (37%).

In the majority of cases the endoscopic approach of the main bile duct was followed by L.C. In patients in which the main bile duct lithiasis was diagnosed through transcystic intraoperative cholangiography the endoscopic approach was initiated immediately after the L.C. (11)

Correlated affliction of the main bile duct in the evolution of A.C. created difficulties in performing L.C. The following were frequently found:

- hepatic pediculitis – 260 cases (20.6%);
- pedicular lipomatosis – 52 cases (4.1%);
- inflammatory reorganisations, such as: fibrous perivisceritis, traction of the main bile duct towards the infundibulo-cystic region, adhesion of the Hartmann pouch to the main bile duct.

The analysis of the causes that determined technical difficulties in L.C. showed the following: Pericholecystic plastron – 325 patients (23%).

Compared to the age of the lesions, the aspect and amplitude of the plastic subhepatic peritonitis, we observed:

- diffuse (phlegmonous) plastron – 221 cases (68%);
- fibrous (“wooden”) plastron – 91 cases (28%);
- abscessed plastron – 13 cases (4%) (Fig. 5).

228 patients were treated through mini-invasive techniques (70%), the remaining 98 (30%) open surgery being required. In 90.8% of the perivesicular plastrons, the gallbladder presented destructive parietal lesions (phlegmonous or gangrenous A.C.).

Choleperitoneum was encountered in 9 patients. 7 patients presented a choleperitoneum with a perihepatic localization, and in 2 patients the choleperitoneum was generalized. 6 patients were treated through mini-invasive technique, while 3 required open surgery.

Non-lithiasic A.C. was diagnosed in 6 cases. Severe sepsis and important alteration of reactivity were observed in all patients. Three patients presented diabetes mellitus. 4 cases were treated mini-invasively. (13)

A.C. in pregnancy was encountered in three patients, two in their first trimester, and one in the second. L.C. was successful in all instances, with good immediate and late results (normal due date, normal newborn).

Conversion to open surgery was required in 144 patients (10%), due to multiple causes:

- wooden pericholecystic plastron – 70 cases (49%);
- unclear anatomical orientation – 67 cases (46.5%);
- haemorrhage – 14 cases (9.7%);
- postoperative plastic peritonitis – 8 cases (5.5%);

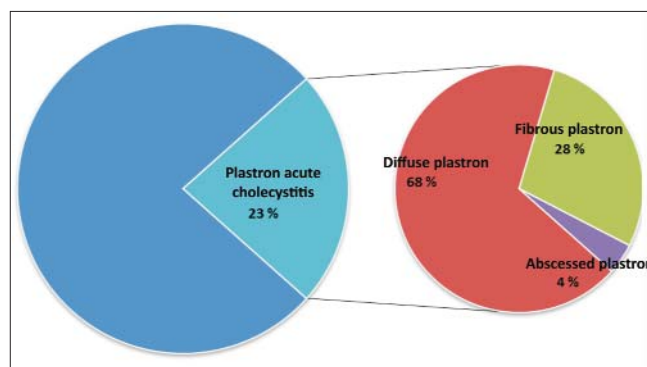


Figure 5. Acute cholecystitis with pericholecystic plastron

- difficult prehension of the gallbladder – 6 cases (4%);
- iatrogenic injury of the main bile duct – 3 cases (0.23%);
- infundibulo-cystic gangrene of the gallbladder – 3 cases (0.2%).

In most cases, more than one cause for conversion co-existed in the same patients. (14,15)

Results of statistical analysis through the  $\chi^2$  test show a significant association between the type of surgical intervention (laparoscopy/conversion) and the patient gender, age group and anatomic-clinical form ( $p < 0,001$ ). There is also a significant association between the treatment method for a plastron (laparoscopy/conversion) and the type of the plastron ( $p < 0,001$ ).

By calculating the odds ratio ( $> 1$ ) it was indicated that the male gender, an age  $> 50$  years, a gangrenous A.C and a fibrous plastron have a high risk of conversion. (Table 1) (16)

In the medical literature the conversion rate varies greatly, between 38% (Pessaux) and 3.7% (Unger). (4) If a rigorous selection of preoperative cases is made, the conversion rate will decrease significantly. In order for a L.C. intervention to present patients with the advantages of a mini-invasive approach, we opted for this principle. Exceptions were represented solely by firm contraindications, especially anaesthesiology related. (4,15)

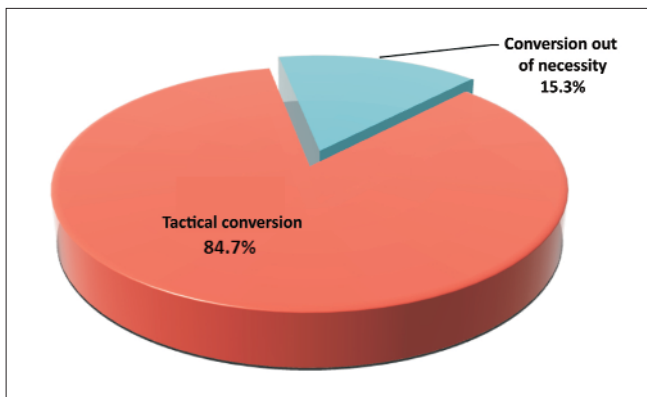
A 10% conversion rate, as was our case, is situated below the average rate of 15%, reported by large statistical studies. Romanian medical literature reports a conversion rate in A.C. varying from 7.1% (15) to 13.8% (5), with a 10% average.

In terms of moment of conversion, this was:

- initial conversion (following laparoscopic exploration) – 84 cases (58%);
- early conversion (before dissecting the Calot triangle)

Table 1. Factors indicating a high conversion risk

Risk Factors	Conversions No. / %	Laparoscopies No. / %	Odds ratio	IC 95%	p
Male gender	57 / 39.6%	316 / 25.1%	1.95	1.37-2.79	$< 0.001$
Age $> 50$ years	109 / 75.7%	707 / 56.2%	2.43	1.63-3.61	$< 0.001$
Gangrenous A.C.	84 / 58.3%	164 / 13.0%	9.34	6.45-13.52	$< 0.001$
Fibrous plastron	64 / 65.3%	27 / 11.9%	13.94	7.82-24.86	$< 0.001$



**Figure 6.** Case distribution according to conversion type

- 52 cases (36%);

- c) late conversion (after dissecting the Calot triangle) – 8 cases (6%).

It is to be observed that altogether, early and initial conversion represent 94% out of the total number of cases treated through open surgery, which is in our opinion a reflection of a judicious and pragmatic approach of each case of A.C.

Conversion out of necessity was performed in 22 patients, and the causes requiring it were:

- haemorrhage – 14 cases;
- tearing of the infundibulo-cystic region – 4 cases;
- iatrogenic injury of the main bile duct – 3 cases;
- iatrogenic plague of the gastric antrum – 1 case.

Tactical conversion was performed in 122 patients (84.7%). (Fig. 6)

Iatrogenic injuries of the main bile duct appeared due to the existence of severe morphopathological remodelings, which made anatomic orientation difficult and determined inadequate technical conditions for dissection (17,18):

- fibrous hepatic pediculitis – 4 cases;
- destructive parietal lesion of the gallbladder – 4 cases;
- voluminous Hartmann pouch, closely adherent to the main bile duct – 3 cases;
- pericholecystitis – 2 cases;
- bilio-biliary fistula – 1 case.

A complete sectioning of the main bile duct was performed in one single case, where it was confused for the cystic duct. In the other 3 situations, the main bile duct injury was due to exaggerated tension exerted on the cystic duct or the gallbladder wall, intimately adherent to the common bile duct. In 3 cases, the iatrogenic lesion was observed intraoperatively, and in the fourth case, a bilio-biliary fistula, it was revealed early postoperatively through early and persistent biliary leakage. The diagnosis was given by ERCP and imposed the necessity of a reintervention.

Reintervention was performed in 20 patients (1.4%). In 11 patients we resorted to open surgery (9 cases) or laparoscopic reintervention (2 cases).

Causes leading to the necessity of reintervention were:

- postoperative haemorrhage – 2 cases;

- postoperative obstructive jaundice – 1 case;
- right subhepatic abscess – 1 case;
- simultaneous presence of two severe diseases – 1 case;
- foreign body (drainage tube entering into the peritoneum) – 1 case;
- lack of possibility to perform a complete cholecystectomy and main bile duct exploration – 1 case.

Endoscopic mini-invasive reinterventions were performed in 13 patients, and were determined by:

- obstructive jaundice – 8 cases;
- acute pancreatitis – 4 cases;
- postoperative biliary leakage – 3 cases;
- acute cholangitis – 2 cases;
- fibrous inflammation of the Oddi sphincter and Vater ampulla – 2 cases.

During the first month following the L.C. reintervention was performed on 8 patients, the remaining 5 requiring endoscopic intervention after a longer length of time, varying between 2 months and one year.

## Discussions. Conclusions

After an analysis of the obtained data, it was observed that L.C. in A.C. determines good results:

- L.C. was accomplished in 90% of the patients;
- the conversion rate to open surgery was 10% out of the total number of cases;
- conversions out of necessity reported a low rate of 1.5%;
- iatrogenic injuries of the main bile duct represented a 0.28% percentage, close to the accident rate usually recorded by open surgery.

The severity of morphological remodelings, induced by the progression of the inflammatory and septic process, represented the most frequent cause for conversion to open surgery. (2,3,19) Despite complex imaging exploration, the exact diagnosis of the amplitude and severity of these remodelings could be made only intraoperatively.

Regardless of the experience and professional skills of the surgeon, there are cases of A.C. that cannot be treated through a laparoscopic approach. These situations proved to be hard to treat even through open surgery.

It is advisable in A.C. that the decision of conversion to open surgery, following an attempt of L.C., be taken before dissecting the Calot triangle, in order to avoid possible accidents and undesirable incidents. (4,20,21)

The advantages of “velvet” surgery proved to be valid for the laparoscopic approach in A.C. as well.

L.C. in A.C. is an assumed risk intervention and often proves to be a “touchstone” for the surgeon, who must be experienced in both open and laparoscopic surgery, in order to solve in full competence difficult and novel situations, offered by biliary pathology. The idea of assumed risk mustn't exclude the idea of caution and pragmatic approach in each case. (4)

No deaths were recorded during our study, giving way to our belief that the attitude taken was the appropriate one.

## References

1. Strasberg SM. Clinical practice. Acute calculous cholecystitis. *N Engl J Med.* 2008;358(26):2804-11.
2. Târcoveanu E, Georgescu S, Bradea C, Stratan I. Laparoscopic cholecystectomy in acute cholecystitis. *Chirurgia (Bucur).* 1995;44(4):29-37. Romanian
3. Palade R, Vasile D, Grigoriu M, Roman H, Caplan I. Difficult laparoscopic cholecystectomy. *Chirurgia (Bucur).* 1997;92(2):87-92. Romanian
4. Tîrcu F. Abordul miniinvaziv în tratamentul complicațiilor litiazei biliare. Teză de doctorat. București: U.M.F. „Carol Davila“; 2001, p.98-186.
5. Jitea N, Burcoș T, Voiculescu S, Cristian D, Vlad M, Angelescu N. Laparoscopic cholecystectomy in acute cholecystitis. *Chirurgia (Bucur).* 1998;93(5):285-90. Romanian
6. Kum CK, Goh PM, Isaac JR, Tekant Y, Ngoi SS. Laparoscopic cholecystectomy for acute cholecystitis. *Br J Surg.* 1994;81(11):1651-4.
7. Lo CM, Liu CL, Fan ST, Lai EC, Wong J. Prospective randomized study of early versus delayed laparoscopic cholecystectomy for acute cholecystitis. *Ann Surg.* 1998;227(4):461-7.
8. Duca S. Laparoscopic surgery: its value and limits. Is the conversion a failure? *Chirurgia (Bucur).* 1997;92(3):139-43. Romanian
9. Deziel DJ. Complications of cholecystectomy. Incidence, clinical manifestations, and diagnosis. *Surg Clin North Am.* 1994;74(4):809-23.
10. Koo KP, Thirlby RC. Laparoscopic cholecystectomy in acute cholecystitis: what is the optimal timing for operation? *Arch Surg.* 1996;131(5):540-4; discussion 544-5.
11. Grigoriu M, Palade R, Vasile D, Voiculescu D, Năstăsescu T. "Rendez-vous" procedure. Mini-invasive treatment of biliary stones. *Chirurgia (Bucur).* 2006;101(3):273-9. Romanian
12. Soper NJ, Brunt LM. The case for routine operative cholangiography during laparoscopic cholecystectomy. *Surg Clin North Am.* 1994;74(4):953-9.
13. Doran H, Mihalache O, Bobircă F, Bugă C, Pătrașcu T. Acute acalculous cholecystitis--difficulties of diagnosis and treatment. *Chirurgia (Bucur).* 2010;105(4):465-8. Romanian
14. Târcoveanu E, Niculescu D, Georgescu S, Epure O, Bradea C. Conversion in laparoscopic cholecystectomy. *Chirurgia (Bucur).* 2005;100(5):437-44. Romanian
15. Spătariu A, Nicolau AE, Beuran M, Tudor C, Oprescu C. Conversion in laparoscopic cholecystectomy for acute cholecystitis. *Chirurgia (Bucur).* 2010;105(4):469-72. Romanian
16. Brodsky A, Matter I, Sabo E, Cohen A, Abrahamson J, Eldar S. Laparoscopic cholecystectomy for acute cholecistitis: can the need for conversion and the probability of complications be predicted? A prospective study. *Surg Endosc.* 2000;14(8):755-60.
17. Tîrcu F, Dragomirescu C, Pletea S, Bănescu B. The problem of iatrogenic common bile duct injury, or the picture of an iceberg peak. *Chirurgia (Bucur).* 2011;106(2):187-94. Romanian
18. Pătrașcu T, Burcoș T, Doran H, Cristian D, Brezean I, Voiculescu S, et al. Injuries of the extrahepatic bile ducts in laparoscopic cholecystectomy. *Chirurgia (Bucur).* 2006;101(4):385-90. Romanian
19. Dragomirescu C, Copăescu C, Munteanu R, Drăghici L. Laparoscopic reoperations. *Chirurgia (Bucur).* 2001;96(5):469-77. Romanian
20. Palade R, Vasile D, Grigoriu M, Voiculescu D. The Fitz-Hugh-Curtis syndrome in laparoscopic surgery. *Chirurgia (Bucur).* 2002;97(6):557-61. Romanian
21. Suliman E, Palade R, Voiculescu D, Simion G. Porcelain gallbladder--diagnostic and therapeutic features. *Chirurgia (Bucur).* 2010;105(3):431-4. Romanian