

## Rives Technique, A Gold Standard for Incisional Hernias – Our Experience

V. Strâmbu<sup>1</sup>, P. Radu<sup>1</sup>, M. Brătucu<sup>1</sup>, D. Garofil<sup>1</sup>, C. Iorga<sup>1</sup>, R. Iorga<sup>1</sup>, F. Popa<sup>2</sup>

<sup>1</sup>Department of General Surgery, “Carol Davila” Nephrology Clinical Hospital, Bucharest, Romania

<sup>2</sup>Department of General Surgery, “St. Pantelimon” Clinical Emergency Hospital, Bucharest, Romania

### Rezumat

#### *Tehnica Rives, standardul de aur în tratamentul herniilor incizionale – experiența noastră*

Herniile incizionale sunt o problemă reală după chirurgia abdominală și pot apărea până la 18% dintre pacienții care au suferit intervenții chirurgicale. Sutura simplă sau așa-numitele procedee anatomice pot să conducă la recidivă în până la 50% din cazuri. Efectuarea unui procedeu aloplastic scade rata de recidivă la 10% - 12%. Popularizată în Europa de către Rives și Stoppa, tehnica sublay s-a dovedit a fi foarte eficientă, cu rate reduse de recurență (0% - 23%) și complicații minime. În clinica noastră am folosit această tehnică în ultimii 10 ani, dar cu unele modificări pe care le considerăm benefice pentru evoluția ulterioară a pacientului și mai ales pentru a obține un perete abdominal solid și funcțional din punct de vedere biomecanic. În timpul perioadei de studiu, am înregistrat un număr total de 45 de pacienți cu hernii abdominale incizionale, operate folosind acest procedeu. Toți pacienții au fost operați de către aceeași echipă chirurgicală. La nici un pacient nu a fost necesar reintervenția chirurgicală. Rezultatele noastre arată că tehnica Rives-Stoppa este o metodă eficientă, ieftină și perfect reproductibilă pentru repararea herniilor incizionale. Complicațiile și ratele de reparație sunt comparabile cu rezultatele în cazul efectuării altor procedee.

**Cuvinte cheie:** Rives modificat, defecte parietale

### Abstract

Incisional hernias are a real problem in abdominal surgery and occur in up to 18% of patients undergoing surgery. Simple sutures or so-called anatomical processes lead to recurrence in up to 50% of cases. Performance of an alloplastic procedure decreases relapse rate to 10%, down from 12%. Popularized in Europe by Rives and Stoppa, the sublay mesh repair technique has proven very effective, with low recurrence rates (0% -23%) and minimal complications. In our clinic we have been using this technique for about 10 years, adding some changes that we consider beneficial to the further evolution of the patient and especially to obtaining a strong abdominal wall, equally functional in terms of bio-mechanics. During the study period, we recorded a total of 45 patients with abdominal incisional hernias operated by this technique. All patients were operated on by the same surgical team. No patients required surgical reintervention. Our results show that the Rives-Stoppa technique is an effective method for repairing incisional hernias. Complications and recurrence rates are comparable with the results of other techniques.

**Key words:** Rives, incisional hernias, modified

### Corresponding author:

Petru Adrian Radu, MD  
Department of General Surgery  
“Carol Davila” Nephrology Clinical Hospital  
Grivitei street, no. 4, sector 1, Bucharest  
Romania  
E-mail: dradupetru@yahoo.com

### Introduction

Incisional hernias are a common problem in abdominal surgery and occur in up to 15% of patients after laparotomy. Incisional

hernia complications include infection, skin ulceration, incarceration of viscera, and intestinal obstruction. Patients also experience abdominal and aesthetic discomfort. Incisional hernia repair continues to be a challenge for any surgeon. Primary closure of parietal defects leads to recurrence rates of 25% - 50%. (1,2) Adding synthetic prostheses placed tension-free ever since the 1950s showed a reduction in the recurrence rate down to 10% (3).

Simultaneously with the development of new prosthetic materials, minimally invasive techniques and open surgical procedures improve, leading surgeons to further debate which type of technique is "ideal" for incisional hernia repair.

Sublay technique has proven very effective, with low recurrence rates (0% - 23%) and minimum rates of complications. (4,5) Among its disadvantages are the complexity of the surgery, longer duration of surgery and likely persistence of chronic abdominal pain.

## Materials and Methods

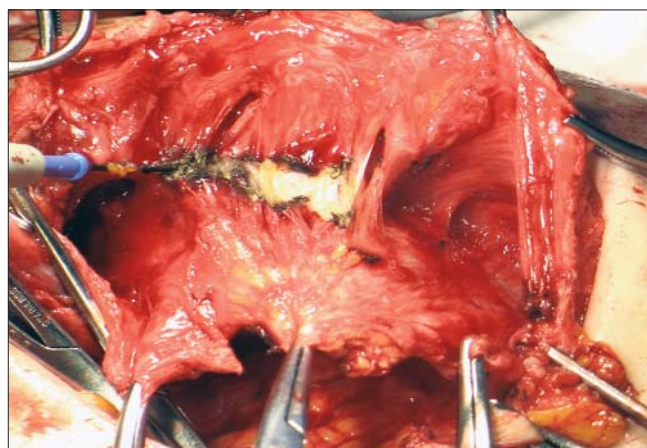
Between January 2003 and December 2011, 45 patients were operated on in our department. The male/female ratio was 1:1 with a mean age of 52 years, (range 27-76). All incisional hernias were located on the abdominal supraumbilical midline. 1 of 5 cases (n=9) were recurrent incisional hernias. At the time of surgery, parietal defects were clinically and symptomatically evident. In 8 cases of hernia incarceration was present. All patients were evaluated preoperatively by an anaesthesiologist, and respiratory tests were carried out.

The surgical technique performed is that described by Rives and Stoppa, but with some modifications. Hernia sac dissection was performed in all patients, followed by lysis of intraperitoneal adhesions, if identified.

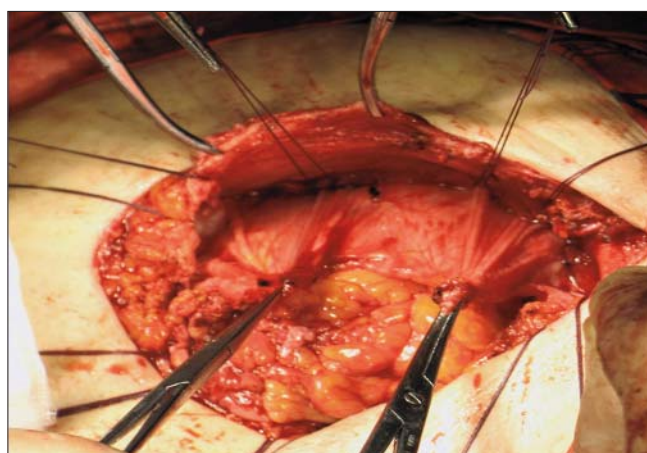
The abdominal fascial plane between the muscle and the posterior sheath was dissected, usually 5-10 cm from the margins of hernia. During the dissection we tried to preserve the nervous pedicle of the muscle as shown in the Fig. 1. We continued by placing the anchor wires, which unlike according to the original technique, are fixed only on the posterior sheath of the abdominal muscle, without involvement of the muscle itself, of the anterior sheath or of the skin. (Fig. 2)

We closed the posterior plane formed by the posterior sheath of rectus muscle and the peritoneum with an intermittent continuous suture (Fig. 3). It is to be mentioned that the closure plane must be performed without tension in the posterior suture. If this is not possible one needs a technical artifice to augment the posterior plane.

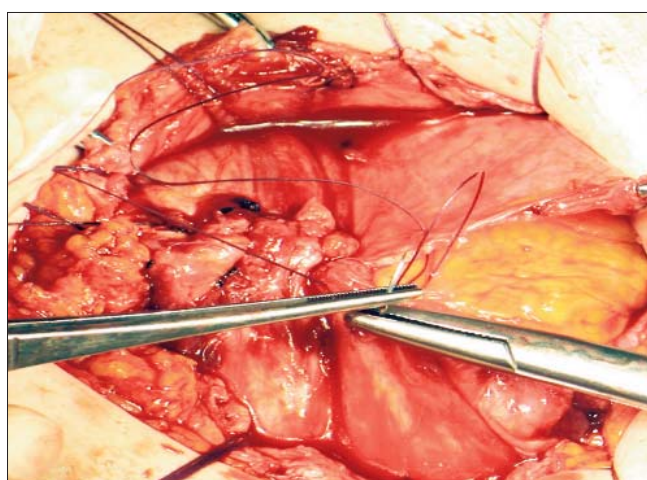
Blood loss was minimal and we were able to close the posterior rectus fascia in all cases. The mesh used was cut in a slightly larger size (5 cm overlap) than that of the fascial defect and anchored with sutures previously set without tension in place (Fig. 4). In all cases two drainage tubes were used: one multifenestrated tube placed retromuscularly (Fig. 5) and one in a supraaponevrotic position. The skin suture was performed with separate wires. Postoperative antibiotic therapy was



**Figure 1.** Dissection of the plane posterior to rectus muscle with vasculo-nervous pedicle preservation



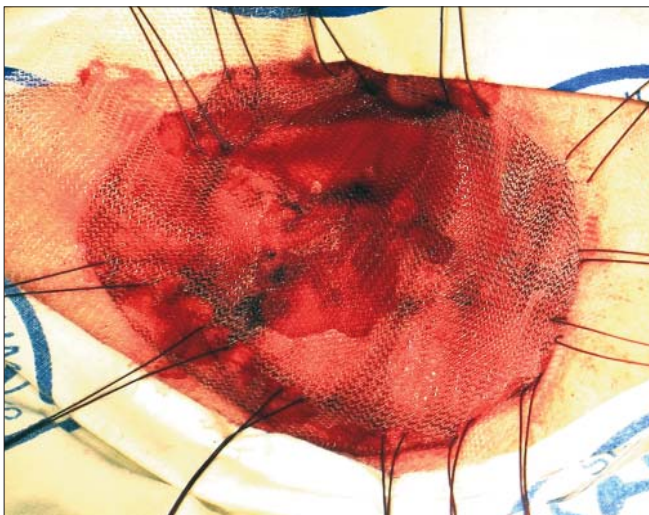
**Figure 2.** The anchor wires are placed only through the posterior sheath of rectus muscle



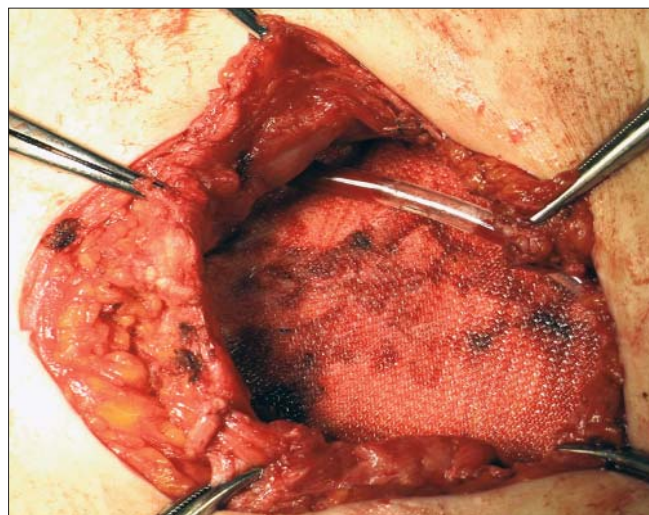
**Figure 3.** Closure of posterior fascial plane

initiated and continued until the suppression of the drain tubes (for a 3 - to 5-day period). Discharge took place on average after 3.5 days.

Follow-up was possible for 37 patients, with mean follow-



**Figure 4.** Anchorage of the mesh



**Figure 5.** Final aspect with retromuscular drain tube

up of 35 weeks (from a range of 4-140 weeks). All patients were examined during the follow-up visit by the operating surgeon. One patient died due to causes unrelated to the hernia repair.

## Results

All 45 patients tolerated the procedure well, without intra-operative complications. Four cases of postoperative complications were recorded. No myocardial infarction or pneumonia cases were recorded. One patient suffered a pulmonary embolism and was treated with anticoagulants. A haematoma was defined as a collection of liquid drainage bleeding. Three patients were readmitted for drainage of retromuscular haematoma. Blood loss was negligible, with a mean post-operative haemoglobin decrease of 0.9 mg / dl.

Most complications were minor, only seven patients requiring re-hospitalization for management. 3 patients had deep wound infection defined as purulent suppuration. The removal of the mesh was not necessary and all were managed successfully with antibiotic therapy and wound dressing. There was no evidence of infection, including in those patients with purulent suppuration. Wound cultures were not performed in patients with suspected seroma in the absence of clinical signs of infection. 7 patients experienced postoperative bowel slowdown phenomena, problem solved in all cases by specific medication. 2 patients had chronic abdominal pain.

3 patients developed recurrent incisional hernias as they presented for follow up. The first patient developed a small defect (3 cm) of hernia recurrence 8 months after the surgery. The patient had a medical history significant for diabetes and respiratory disorders. The other 2 cases were obese patients with important cardiac and respiratory disorders.

23 patients were considered to be obese (BMI > 40 kg/m<sup>2</sup>) and 9 patients have undergone a surgical procedure

that could lead to a malabsorption syndrome (various intestinal resections). In our group, history of diabetes, benign prostatic hyperplasia and chronic lung disease seem the only significant prognostic factors for recurrence.

## Discussion

Incisional hernia repair surgical techniques continue to evolve with remarkable progress in terms of prosthetic materials and minimally invasive technology. An optimal technique for mesh placement has not yet been determined and is still a subject of debate among surgeons. (6,7) Laparoscopic techniques seem to have many benefits, including decreased length of hospital stay, decreased postoperative pain, and reduce the time to return to work and normal activities, but is still not very accessible to all surgeons, especially in our country. Also, the special type of mesh used for this kind of procedures is quite expensive.

Our experience, developed through different techniques, shows that modified Rives procedures offer guaranties for optimal repair of incisional hernias with promising recurrence rates and low complication rates.

There are currently no reliable methods for selecting which patients are suitable for laparoscopic incisional hernia repair except for the dimensions of the hernia, but this is a subjective criterion depending on the surgeon (8). Data from our study suggest that the technique described here is associated rarely, if ever with the specific complications associated with this type of approach. Defects up to 22 cm in height can be closed using more relaxed incisions. Rives-Stoppa modified technique allows good cosmetic results. (9) Skin necrosis is rare because the plane dissection is minimal in the supraaponevrotic area, with minimum subcutaneous dissection. Modified Rives-Stoppa technique preserves functionality and integrity of the abdominal wall, factors thought to be essential for the effective repair of abdominal wall defects. By avoiding the suture of the entire abdominal wall with mesh anchor wires the biological

dynamics of the abdominal wall is better preserved in our opinion. The benefits of this technique include the ability to tap the fascial defect and identify any potential weaknesses. The Rives technique preserves the functionality and integrity of the abdominal wall, factors considered to be crucial for effective repair of abdominal wall defects by means of the separation of components technique. (10)

Peritoneal defects can be recognized, and, if necessary, we can use a larger mesh than the preoperative calculated area for reinforcing the real defect, which is often underestimated. Prosthesis placement between the posterior sheath and abdominal muscles uses intraabdominal pressure to ensure its fixing, at the same time minimizing the risk of adhesions and fistulas (11).

An extensive dissection plane between the posterior sheath and muscle decreases closure tension of the abdominal layer. (12,13) Also, we consider that avoiding as much as possible damages to the nervous pedicles promotes a better rectus muscle function and recovery.

It should be noted that most complications were minor and perfectly manageable in outpatient treatment. Despite pre-and postoperative antibiotic prophylaxis, infection rate remains at about 10% in most published studies. This may be attributed to patient dependent factors, and to their natural response to a foreign material. The tunnelling path of drain tubes may also be an explanation for this condition. Criteria for removing the drain tubes were generally represented by a daily flow below 30 ml/day.

An early suppression of drainage may decrease the rates of wound suppurations in our opinion, along with their unpleasant consequences.

Although common postoperative complications were not significant risk factors for relapse, other studies have recognized the risk of recurrence as increased in these cases.

In some studies in which patients underwent elective parietal repair concomitant with colon resection, the authors concluded that the repair of incisional hernias with prostheses can be performed in the contaminated territories, without increasing the risk of complications. Chronic pain is a concern in these patients, but with no significance in our study. The issue of chronic pain was also raised in previous studies. (14) McLanahan et al. reported that 11% of patients had moderate to severe pain 12 months after incisional hernia. (7)

Although diabetes, benign prostatic hypertrophy and chronic respiratory diseases were identified as risk factors for recurrence in all studies, due to the size of the study group it is most likely for it not to have sufficient statistical power to detect the significance of other known risk factors.

Sugerman et al. demonstrated that severe obesity is a greater risk factor for recurrence than steroid use. (15)

Although diabetes, benign prostatic hypertrophy and chronic respiratory diseases were identified as risk factors for recurrence in all studies, due to the size of the study group it is most likely to not have sufficient statistical power to detect significance of other known risk factors. (16,17,18)

## Conclusions

Rives-Stoppa technique modified as described above appears to be an effective treatment for incisional hernias. These results compare favourably with other published reports of Rives-Stoppa repair and other techniques.

The recurrence rate is clearly acceptable in this series, taking into consideration that it includes many patients with multiple risk factors and a number of patients who have not responded to previous attempts at repair.

We also believe that the lack of significant events after abdominal repair is important to be noted. Chronic pain and persistent abdominal rigidity continue to be problematic, but relatively easy to manage.

We also believe that the modified technique improves the bio-mechanics of the abdominal wall.

Finally, the choice of repair technique is substantially indicated by anatomical tissue representation and by surgeon experience.

## References

1. Millikan KW. Incisional hernia repair. *Surg Clin North Am.* 2003;83(5):1223-34.
2. Stoppa R, Louis D, Verhaeghe P, Henry X, Plachot JP. Current surgical treatment of postoperative eventrations. *Int Surg.* 1987;72(1):42-4.
3. Wantz GE. Incisional hernioplasty with Mersilene. *Surg Gynecol Obstet.* 1991;172(2):129-37.
4. Bauer JJ, Harris MT, Gorfine SR, KreeI I. Rives-Stoppa procedure for repair of large incisional hernias: experience with 57 patients. *Hernia.* 2002;6(3):120-3. Epub 2002 Jul 13.
5. Luijendijk RW, Hop WC, van den Tol MP, de Lange DC, Braaksma MM, IJzermans JN, et al. A comparison of suture repair with mesh repair for incisional hernias. *N Engl J Med.* 2000;343(6):392-8.
6. Temudom T, Siadati M, Sarr MG. Repair of complex giant or recurrent ventral hernias by using tension-free intraparietal prosthetic mesh (Stoppa technique): lessons learned from our initial experience (fifty patients). *Surgery.* 1996;120(4):738-43; discussion 743-4.
7. vanGeldere D. One hundred years of abdominal wound dehiscence and nothing has changed. *Hernia.* 2000;4:302-4.
8. McLanahan D, King LT, Weems C, Novotney M, Gibson K. Retrorectus prosthetic mesh repair of midline abdominal hernia. *Am J Surg.* 1997;173(5):445-9.
9. Yaghoobi Notash A, Yaghoobi Notash A Jr, Seied Farshi J, Ahmadi Amoli H, Salimi J, Mamarabadi M. Outcomes of the Rives-Stoppa technique in incisional hernia repair: ten years of experience. *Hernia.* 2007;11(1):25-9. Epub 2006 Nov 11.
10. Ramirez OM, Ruas E, Dellon AL. "Components separation" method for closure of abdominal-wall defects: an anatomic and clinical study. *Plast Reconstr Surg.* 1990;86(3):519-26.
11. Rives J, Lardennois B, Pire JC, Higon J. Large incisional hernias. The importance of flail abdomen and of subsequent respiratory disorders. *Chirurgie.* 1973;99(8):547-63. French
12. Clarke J. Incisional hernia. In: Bland KI, editor. *The Practice of General Surgery.* New York: Saunders; 2001. p. 803-9.
13. Gonzalez R, Rehnke RD, Ramaswamy A, Smith CD, Clarke JM, Ramshaw BJ. Components separation technique and

- laparoscopic approach: a review of two evolving strategies for ventral hernia repair. *Am Surg.* 2005;71(7):598-605.
14. White TJ, Santos MC, Thompson JS. Factors affecting wound complications in repair of ventral hernias. *Am Surg.* 1998; 64(3):276-80.
  15. Sugeran HJ, Kellum JM Jr, Reines HD, DeMaria EJ, Newsome HH, Lowry JW. Greater risk of incisional hernia with morbidly obese than steroid-dependent patients and low recurrence with prefascial polypropylene mesh. *Am J Surg.* 1996;171(1):80-4.
  16. Graur F. Treatment of incisional hernia using the sublay technique. *Chirurgia (Bucur).* 2010;105(3):387-91. Romanian
  17. Akinci M, Ergul Z, Kaya O, Kulah B, Kulacoglu H. Predictors for duration of hospital stay after abdominal wall hernia repairs. *Chirurgia (Bucur).* 2012;107(1):47-51.
  18. Nicolau AE. Laparoscopic repair of abdominal ventral hernias. *Chirurgia (Bucur).* 2010;105(6):817-22. Romanian