

Epidemiological Features and Management of Complex Neck Trauma from an ENT Surgeon's Perspective

M.D. Cobzeanu¹, D. Palade¹, C. Manea²

¹"Grigore T. Popa" University of Medicine and Pharmacy, "Sfantul Spiridon" Emergency Clinic Hospital, Iasi, Romania

²"Carol Davila" University of Medicine and Pharmacy, "Sfanta Maria" Clinical Hospital, Iasi, Romania

Rezumat

Traumatisme complexe la nivelul gâtului - aspecte epidemiologice și mod de abordare din perspectiva chirurgului ORL

Obiective: Scopul acestui studiu este de a prezenta aspectele epidemiologice ale traumatismelor gâtului, în cazul pacienților prezentați la camera de gardă. Studiul arată complexitatea diagnosticului și a planului terapeutic urmat în două departamente ORL – Spitalul „Sfanta Maria” din București și Spitalul „Sfantul Spiridon” din Iași.

Material și metode: Am efectuat un studiu retrospectiv pe 538 pacienți cu traumatisme de gât care s-au prezentat la camera de gardă a celor două spitale în perioada martie 2009 – martie 2011, dintre care s-au selectat 27 de cazuri cu implicații medico-legale.

Rezultate: În funcție de mecanismul etiologic, cele mai frecvente cauze ale traumatismelor de gât au fost cele produse prin atacuri sau mutilări cu arme albe (cuțite, lame de ras, furculițe, cioburi) – 56%. Următoarele ca frecvență (44%) au fost traumatismele prin zdrobire rezultate în urma accidentelor auto, strangulărilor sau căderilor accidentale. Patologia cea mai importantă printre pacienții internați a fost constituită din politraumatisme, hematoame, fracturi, emfizem subcutanat sau perforații ale pielii, traumatisme ale viscerelor, rupturi tisulare (10,34%), hemoragii importante (6,89%) și perforații ale organelor gâtului (3,45%). Cele mai frecvente complicații post-

operatorii au fost fistulele faringo-cutanate (7,4%) și stenozele laringo-traheale (7,4%). Alți 3 pacienți au prezentat complicații pe termen lung precum mediastinită acută (3,4%), paralizie recurențială cu sindrom Gerhardt (3,4%) și disfagie (3,4%).

Cuvinte cheie: traumatisme ale gâtului, plăgile penetrante ale gâtului, plăgile prin zdrobire ale gâtului, complicațiile traumatismelor gâtului

Abstract

Objectives: The aim of this study is to present a clear picture of the epidemiological aspects pertaining to the cases of neck trauma addressing to the ENT Emergency Room, as well as to display the complexity of the diagnostic and therapeutic management employed in two important Romanian ENT Departments - „Sfantul Spiridon” Hospital Iasi and „Sfanta Maria” Hospital Bucharest

Material and methods: We conducted a retrospective study on 538 patients with neck trauma that were referred to the above mentioned ENT Departments between March 2009 – March 2011, selecting 27 cases with forensic implications.

Results: In terms of aetiological mechanism, the most frequent neck injuries in our study were penetrating neck injuries due to assault or self-mutilation with white weapons (knives, razor blades, forks, glass) - 56%, followed by blunt trauma cases due to car accident, strangulation or accidental fall – 44%. The most important clinical findings recorded at admission were polytraumas (24.14%), hematomas, fractures, subcutaneous emphysema or skin perforation with visceral damages (representing each 13.8%) and tissue rip (10.34%), important bleedings (6.89%), as well as perforation of neck organs (3.45%). The most frequent postoperative complications were

Corresponding author:

Claudiu Manea, MD
Sfanta Maria Hospital, ENT Department
Ion Mihalache Bvd., 37-39, District 1
Bucharest, Romania
E-mail: cmmanea@yahoo.com

postoperative pharyngo-cutaneous fistula (7.4%) and laryngo-tracheal stenosis (7.4%). There were also 3 other patients with long-term complications, such as acute mediastinitis (3.4%) recurrential paralysis with Gerhardt's syndrome (3.4%) and dysphagia (3.4%).

Key words: neck traumas, penetrating neck injuries, blunt neck trauma, complications of neck traumas

Introduction

Due to the high concentration of important vital structures in a narrow anatomic space, cases of complex or even small neck traumas can lead to serious diagnostic and treatment problems. Given the lethal potential of this kind of injuries, selecting the most appropriate clinical and paraclinical investigation methods, as well as the most adequate treatment strategy is vital and has become a challenge for even the most experienced surgeons. (1)

Complex vascular-nervous and glandular lesions associated with laryngo-tracheal or pharyngo-oesophageal injuries often cause respiratory failure, swallowing difficulties, phonation disorders and other important local complications such as cervico-mediastinal infections, hematomas or important regional bleeding. (2)

The association of polytraumas with head, thoracic-abdominal or limb injuries requires a multidisciplinary management, in order to prevent forensic issues and those related to malpractice.

The aim of this study is to present a clear picture of the epidemiological aspects pertaining to the cases of neck trauma addressing to the ENT Emergency Room, as well as to display the complexity of the diagnostic and therapeutic management employed in two important Romanian ENT Departments - „Sfantul Spiridon” Hospital Iasi and „Sfanta Maria” Hospital Bucharest.

Material and Methods

We conducted a retrospective study on 538 patients with neck trauma that were referred to the above mentioned ENT Departments between March 2009 – March 2011, selecting 27 cases with forensic implications.

All patients were evaluated in the Emergency Room using the Advanced Trauma Life Support protocols (ATLS) (3,4), trying to identify life-threatening conditions such as: 1. laryngotracheal trauma or external compression by a large hematoma that can cause airway obstruction; 2. tension pneumothorax; 3. important external or internal active bleeding; 4. spinal cord injury or ischemic brain damage due to carotid artery occlusion. In addition, after the initial evaluation, our protocol included the assessment of other occult lesions, using endoscopic, radiologic or ultrasound methods, and also of those with lethal potential, such as: a. occult laryngotracheal

injuries; b. pharyngo-oesophageal injuries; c. cranial or peripheral nerve injuries; d. occult vascular injuries.

We evaluated the type of therapeutic measures that were taken in these cases of complex neck injuries, together with the type of immediate and late complications encountered.

Results

According to our observations, men were much more frequently involved in serious neck injuries than women: out of the 27 patients in our series, 21 were males and only 6 females (male/female ratio – 3.5/1). Patient age varied between 17 and 67 years, with a mean age of 47.3 years.

In terms of production mechanism, most of the cases were due to penetrating neck injuries after assault or self-mutilation with white weapons (knives, razor blades, forks, glass) – 15 cases, representing 56%, while the other 12 patients presented with blunt traumas due to car accident, strangulation (with a rope) or accidental fall. (Fig. 1)

Post-aggression injuries were the most frequent among penetrating injuries, representing 73.33% of the latter (11 cases), 7 of them being caused using knives, 2 inflicted with forks, 1 due to an attack with glass pieces, and 1 by use of a razor blade. Out of the injuries produced by self-mutilation (4 cases, 26.66%), 2 were due to the use of knives, 1 after glass piece manipulation, and 1 was produced using a razor blade. (Fig. 2)

The blunt trauma cases were due mainly to neck collision with a solid surface, such as a steering wheel or dashboard in car accidents (7 cases, 58.33%), the rope used for strangulation (3 cases, 25%) or various objects and surfaces hit during accidental falls (2 cases, 16.67%). (Fig. 3)

Another important parameter that was taken into account in our study was the type of lesion involved in the neck trauma. Most patients were polytraumatised (7 cases, 24.14%), followed by patients with important hematomas, fractures, subcutaneous emphysema or skin perforation with visceral damages (4 patients, one representing each and corresponding to 13.8%), patients with tissue rip (3 cases, 10.34%), important

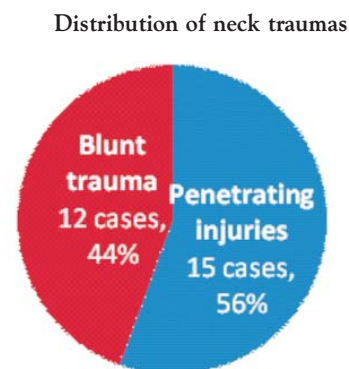


Figure 1. Distribution of neck traumas in accordance with their etiology

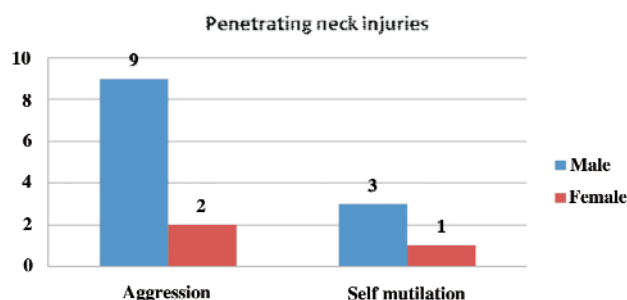


Figure 2. Distribution of penetrating neck injuries, classified in accordance with the production mechanism and sex

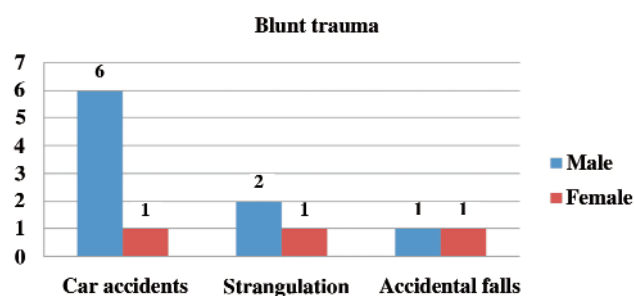


Figure 3. Distribution of blunt traumas, classified in accordance with the production mechanism and sex

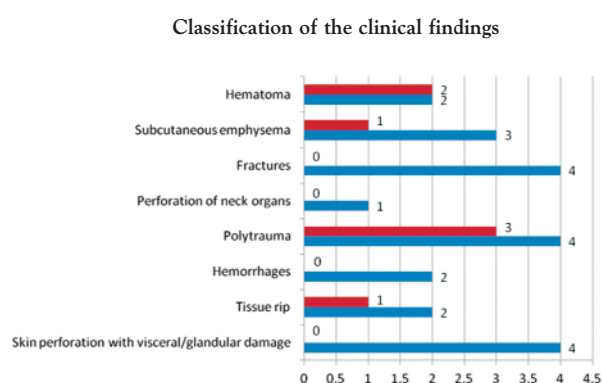


Figure 4. Classification of the clinical findings on admission in patients with neck traumas




Figure 5. Complications of complex neck trauma

bleedings (2 cases, 6.89%), and also with perforation of neck organs (1 case, 3.45%). (Fig. 4)

Regarding the therapeutic algorithm employed in our traumatic cases, we used exploratory cervicotomy in the majority of them, followed by careful control of the bleeding, closure of the visceral breaches, with or without the use of muscle flap reconstruction to prevent digestive fistulas. Digestive rest - using a nasogastric feeding tube - and tracheostomy, for 7-14 days, are important conditions for the resumption of swallowing, breathing and normal phonation. Also, the administering of broad-spectrum antibiotics, anti-inflammatory agents and proton pump inhibitors, prevents regional complications and sequelae.

We had 7 patients with post-therapeutic complications in our study group (Fig. 5). The most frequent were postoperative pharyngo-cutaneous fistula (2 cases, 29% of all complications, 7.4% of all cases) and laryngo-tracheal stenosis (2 cases, 29% of all complications, 7.4% of all cases). Also, there were another 3 patients with long-term complications, such as acute mediastinitis (1 patient, 14% of all complications, 3.7% of all cases), recurrential paralysis with Gerhardt's syndrome (1 case, 14% of all complications, 3.7% of all cases) and dysphagia (1 case, 14% of all complications, 3.7% of all cases).

Further on we will discuss one case of complex neck trauma due to aggression, exemplifying the pathological and therapeutic aspects listed above.

Case 1. Patient U.S. aged 58, is brought by ambulance to the hospital after a violent assault using a knife, presenting multiple cervico-facial trauma with epistaxis, bruising, facial and neck hematoma, severe dyspnoea, difficulty swallowing, dizziness and cephalalgic syndrome.

After a careful evaluation of the damages, we performed a laryngeal videofibroscope, a plain radiography and a CT scan exam, showing a retro-cricoid hematoma with extension into the piriform sinuses and enlargement of the cervical space and of the anterior mediastinum.

An emergency low tracheotomy was performed, under general anaesthesia with tracheal intubation, followed by the exploration of the continuity solution found at the level of the thyro-hyoidian membrane, and then by hypopharyngo-laryngeal hematoma removal with the placing of a nasogastric tube, and pharyngo-laryngeal repair. The patient had a good postoperative recovery with swallowing and oral breathing restoration after 12 days, without any postoperative functional sequelae (Fig. 6).

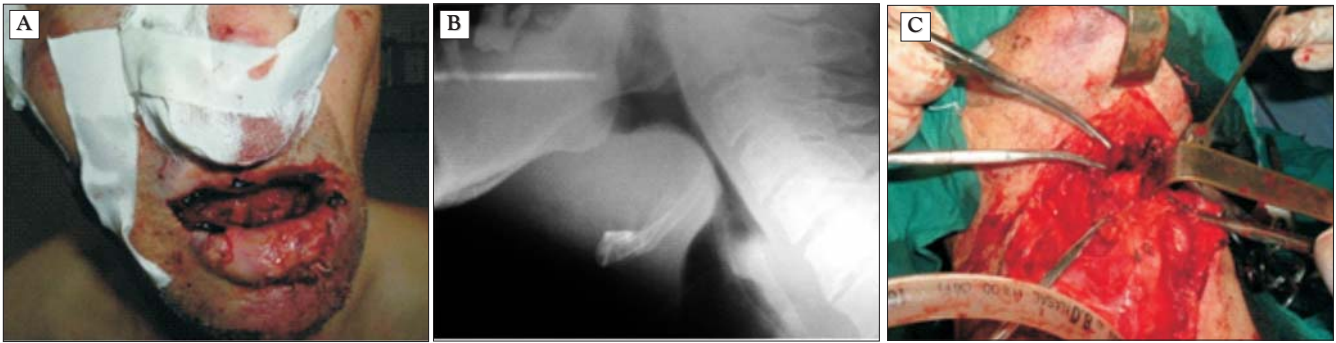


Figure 6. Polytrauma. Case 1 – polytraumatised patient after violent assault presenting multiple cervico-facial trauma due to fist fight with bruising and facial hematoma, epistaxis (anterior nasal package – (A) and neck hematoma due to cervical knife wound (plain cervical radiography showing anterior cervical hematoma – (B, C) – intraoperative image showing the continuity solution at the level of the thyro-hyoidian membrane

Discussions and case presentation

In the United States, most of the penetrating neck injuries addressing to urban trauma centres are produced using various firearms (44%), shotguns (4%) or other weapons (12%), and only 40% are due to stab wounds (4). In Romania however, due to the restrictive legislation regarding firearm possession, the vast majority of this kind of injuries are produced using white weapons. In our study, none of the 15 patients with penetrating neck injuries owed their condition to firearms. This may be a positive aspect, because it is a known fact that gunshot wounds are more likely to be linked with vascular or aerodigestive injuries, or large neck hematomas, than knife wounds (5,6).

Blunt trauma to the neck is produced especially during car crashes when unrestrained drivers strike their anterior neck to the steering wheel (7). This was also the case in our study, 7 of our patients with blunt traumas being involved in car accidents. Contrary to cervical spine injuries, that are common in this type of traumas, aerodigestive lesions are rarer, being encountered in less than 1% of blunt traumas (8), and far less common than in cases of penetrating neck injuries, where they can be encountered in up to 5-15% of patients (9). In our study, there were no complications due to blunt traumas, the two cases of pharyngo-cutaneous fistulas (representing 7.4% of all cases) being observed in cases of penetrating neck injuries.

This kind of complications involving the larynx, trachea, hypopharynx, oesophagus or major neck vessels can sometimes be life-threatening. Their resolution depends on the first aid measures taken in order to evaluate the damages, to ensure the airway patency, to perform an emergency haemostasis and to transport the victim to a specialized trauma centre. (10,11)

The most severe complications that can occur immediately after the aggression are represented by circulatory and respiratory failure, traumatic and haemorrhagic shock. These complications may worsen in the absence of a firmly therapeutic conduct after a well-established protocol that avoids the appearance of morpho-functional sequelae with

forensic implications. (12)

The ability and experience of the surgical team can help avoid postoperative complications by performing an efficient haemostasis, and by repairing the continuity of the digestive tract (hypopharynx - oesophagus), of the respiratory tract (laryngo-tracheal) or of other injured neck tissue elements as the case may be. (13,14)

Given the anatomic complexity of the cervical region, the ENT surgeon, in order to be able to prevent therapeutic mistakes with forensic implications, must be well-skilled in trauma treatment and have competence in the fields of plastic, aesthetic and vascular surgery.

The difficulties (where any) in the management of neck traumas with a forensic impact were generated by (15,16):

- a) specific anatomic neck conditions, anatomic variants, complexity of the landmarks and close vicinity to the upper aero-digestive path and to the vascular-nervous bundle of the neck;
- b) posterior relationship with the cervical spine and its possible injury;
- c) the association of complex polytraumas: head, cervical, thoracic, abdominal and limb injuries;
- d) surgical technique problems caused by a short or a kyphotic neck with associated pathology of the thyroid gland (diffuse goitre, nodular goitre with widened isthmus or presenting as chest plunged goitre), vascular-nervous malformation of the neck.

Patients should be informed regarding the type of medical treatment that is to be applied, and sign an informed consent, necessary to diminish the constraints put on health professionals and to prevent forensic implications (17,18). It is initially necessary to record the patient status at admission and the immediate first aid measures taken, describing in detail the therapeutic protocol and the possible outcomes of the surgical act from an aesthetical and functional point of view. All these measures will exonerate the medical doctor from any future complaints of the patients, as well as of the perpetrators. (19,20)

Conclusions

Traumatic neck injuries remain a challenge for ENT surgeons due to the large amount of vital structures present in a narrow anatomic space. The precocity of lesion balancing using precise clinical and paraclinical methods, followed by rigorous medical and surgical therapeutic measures, may lead to good functional results in these life-threatening conditions.

In order to prevent complications and sequelae a multi-disciplinary approach is sometimes needed, involving a vascular surgeon, a neurosurgeon and/or a thoracic surgeon, along with the ENT surgeon. Also, the traumatized patient requires a well-trained anaesthesiologist and intensive-care specialist to be able to support his/her vital functions.

Regarding the aetiological mechanism, in our study the most frequent neck injuries were penetrating neck injuries due to assault or self-mutilation with white weapons (knives, razor blades, forks, glass) - 56%, followed by blunt trauma cases due to car accident, strangulation or accidental fall - 44%.

The most important clinical findings recorded at admission were polytraumas (24.14%), hematomas, fractures, subcutaneous emphysema or skin perforation with visceral damages (representing each 13.8%) and tissue rip (10.34%), important bleedings (6.89%), as well as perforation of neck organs (3.45%).

The most frequent postoperative complications were post-operative pharyngo-cutaneous fistula (7.4%) and laryngo-tracheal stenosis (7.4%). There were also 3 patients with long-term complications, such as acute mediastinitis (3.4%) recurrential paralysis with Gerhardt's syndrome (3.4%) and dysphagia (3.4%).

The therapeutic algorithm we followed included in the majority of cases exploratory cervicotomy, subsequent careful haemostasis, closure of the visceral breaches, with or without the use of muscle flap reconstruction to prevent digestive fistulas. Digestive rest using nasogastric tube and breathing through tracheotomy were also employed.

References

1. Beuran M, Negoï I, Paun S, Runcanu A, Gaspar B. History of trauma care. *Chirurgia (Bucur)*. 2011;106(5):573-80.
2. Schaefer SD. Laryngeal and esophageal trauma. In: Cummings CW, ed. *Otolaryngology Head Neck Surgery*. Vol 3. 3rd ed. Mosby: St Louis; 1998:2001-2012.
3. Balcou S, Sarbulesco G. Gunshot wound to the root of the neck; bullet on the cervical pleura; operation; recovery, 1937. *Chirurgia (Bucur)*. 2011;106(3):369-72.
4. Bouillon B, Kanz KG, Lackner CK, Mutschler W, Sturm J. The importance of Advanced Trauma Life Support (ATLS) in the emergency room. *Unfallchirurg*. 2004;107(10):844-50.
5. Kortbeek JB, Al Turki SA, Ali J, Antoine JA, Bouillon B, Brasel K, et al. Advanced trauma life support, 8th edition, the evidence for change. *J Trauma*. 2008;64(6):1638-50.
6. Demetriades D, Theodorou D, Cornwell E, Berne TV, Asensio J, Belzberg H, et al. Evaluation of penetrating injuries of the neck: prospective study of 223 patients. *World J Surg*. 1997; 21(1):41-7; discussion 47-8.
7. Demetriades D, Velmahos GC, Asensio JA. Penetrating injuries of the neck. In: Shoemaker W, editor. *Textbook of Critical Care*. 4th ed. Philadelphia: WB Saunders; 2000. Chapter 29. p. 330-7.
8. Yen PT, Lee HY, Tsai MH, Chan ST, Huang TS. Clinical analysis of external laryngeal trauma. *J Laryngol Otol*. 1994; 108(3):221-5.
9. Gussack GS, Jurkovich GJ, Luteran A. Laryngotracheal trauma: a protocol approach to a rare injury. *Laryngoscope*. 1986;96(6):660-5.
10. Atkins BZ, Abbate S, Fischer SR, Vaslef SN. Current management of laryngotracheal trauma: case report and literature review. *J Trauma*. 2004;56(1):185-90.
11. Beuran M, Negoï I, Păun S, Runcanu A, Gaspar B, Vartic M. Trauma scores: a review of the literature. *Chirurgia (Bucur)*. 2012;107(3):291-7. Romanian
12. Abujamra L, Joseph MM. Penetrating neck injuries in children: a retrospective review. *Pediatr Emerg Care*. 2003; 19(5):308-13.
13. Iuonut AM, Gongonau DN, Precup CG, Dindelegan GC, Ciuce C. Current methods for wound debridement. *Chirurgia (Bucur)*. 2011;106(5):605-12.
14. Carducci B, Lowe RA, Dalsey W. Penetrating neck trauma: consensus and controversies. *Ann Emerg Med*. 1986;15(2): 208-15.
15. White RK, Morris DM. Diagnosis and management of esophageal perforations. *Am Surg*. 1992;58(2):112-9.
16. Luntz M, Nusem S, Kronenberg J. Management of penetrating wounds of the neck. *Eur Arch Otorhinolaryngol*. 1993;250(7): 369-74.
17. Bumpous JM, Whitt PD, Ganzel TM, McClane SD. Penetrating injuries of the visceral compartment of the neck. *Am J Otolaryngol*. 2000;21(3):190-4.
18. McConnell DB, Trunkey DD. Management of penetrating trauma to the neck. *Adv Surg*. 1994;27:97-127.
19. Apffelstaedt JP, Müller R. Results of mandatory exploration for penetrating neck trauma. *World J Surg*. 1994;18(6):917-9; discussion 920.
20. Edwards WH Jr, Morris JA Jr, DeLozier JB 3rd, Adkins RB Jr. Airway injuries. The first priority in trauma. *Am Surg*. 1987; 53(4):192-7.
21. Martin WS, Gussack GS. Pediatric penetrating head and neck trauma. *Laryngoscope*. 1990;100(12):1288-91.