

## A Modified Surgical Technique for Inferior Alveolar Nerve Repositioning on Severely Atrophic Mandibles: Case Series of 11 Consecutive Surgical Procedures

H.M. Barbu<sup>1,2</sup>, L. Levin<sup>3</sup>, M.B. Bucur<sup>4,5</sup>, R.M. Comaneanu<sup>6</sup>, A. Lorean<sup>7,8</sup>

<sup>1</sup>Department of Oral Implantology, Faculty of Dentistry, "Titu Maiorescu" University, Bucharest, Romania

<sup>2</sup>"Victor Babeş" General Hospital, Bucharest, Romania

<sup>3</sup>Department of Periodontology, School of Graduate Dentistry, Rambam Health Care Campus, and Faculty of Medicine, Technion, IIT, Haifa, Israel

<sup>4</sup>Faculty of Dentistry, "Carol Davila" University, Bucharest, Romania

<sup>5</sup>Private Practice, Dentimplant, Bucharest, Romania

<sup>6</sup>Department of Radiology, Faculty of Dentistry, "Titu Maiorescu" University, Bucharest, Romania

<sup>7</sup>Laniado Hospital, Netanya, Israel

<sup>8</sup>Department of Oral Implantology, Faculty of Dentistry, "Titu Maiorescu" University, Bucharest, Romania

### Rezumat

#### ***O tehnică chirurgicală modificată pentru re poziționarea nervului alveolar inferior în atrofiile severe mandibulare: o serie de 11 proceduri chirurgicale consecutive***

**Context:** Pentru a evidenția caracteristicile și posibilele dificultăți ale tehnicii de re poziționare a nervului alveolar inferior (NAI) în cazurile de resorbție osoasă severă în regiunea posterioară mandibulară și de a modifica tehnica manipulării țesuturilor dure și moi.

**Materiale și Metode:** Am analizat retrospectiv, șapte pacienți care s-au prezentat în cadrul clinicilor noastre solicitând restabilirea funcției masticatorii cu ajutorul unor restaurări protetice fixe, având o grosime osoasă reziduală minimă (0.5 mm -1.5 mm) deasupra NAI. Au fost efectuate intervenții de re poziționare a NAI simultan cu inserarea implanturilor dentare.

**Rezultate:** Unsprezece proceduri de re poziționare NAI au fost efectuate pe mandibule cu resorbție osoasă severă. Vârsta medie a pacienților a fost de 43,29 ani (SD 12,37). Osul rezidual deasupra NAI a variat între 0,5 mm și 1,5 mm, cu o medie de 0,93 mm (0,35 SD). În total, 32 de implanturi

dentare au fost inserate simultan cu re poziționarea NAI. Timpul mediu de dispensarizare a fost de 35.71 luni (41,75 SD), variind între 7 și 120 de luni.

**Concluzii:** Cazurile severe de atrofie necesită atenție specială din cauza pierderii țesutului keratinizat de la nivelul crestei alveolare. Utilizarea unei abordări chirurgicale modificate și instrumente chirurgicale specifice oferă un mediu de lucru mai sigur pentru operator și asigură rezultate optime.

**Cuvinte cheie:** re poziționarea nervului alveolar inferior, implanturi dentare, resorbția severă mandibulară, osul rezidual, gaura mentonieră

### Abstract

**Background:** To emphasize the characteristics and possible pitfalls of nerve reposition in cases of severe bone resorption in the posterior mandibular area, and to modify hard- and soft-tissue manipulation accordingly.

**Methods:** We analyzed retrospectively, 7 patients in which we performed full arch lower jaw rehabilitation. The patients presented for oral rehabilitation having a minimal residual bone above the mandibular canal and had undergone inferior alveolar nerve (IAN) displacement with modified surgical technique for fixed prosthetic rehabilitation.

**Results:** Eleven procedures of nerve repositioning were

Corresponding author:

Raluca Monica Comaneanu, MD  
Gheorghe Petrascu 67A, Bucharest, Romania  
E-mail: monica.tarcolea@gmail.com

performed on severely atrophic mandibles. The average age of the patients was 43.29 years (12.37 SD). Residual bone above the mental foramen ranged between 0.5 mm and 1.5 mm, with an average of 0.93 mm (0.35 SD). In total, 32 dental implants were inserted into the area simultaneously with nerve displacement. The average follow-up time was 35.71 months (41.75 SD), ranging between 7 and 120 months.

**Conclusions:** Severe atrophic cases require special attention due to the loss of keratinized tissue around the crestal area. The use of a modified surgical approach and specific surgical instruments provides a safer working environment for the operator and ensures optimal results.

**Key words:** inferior alveolar nerve repositioning, dental implants, resorbed mandibles, residual bone, mental foramen

## Introduction

The treatment of severe bone atrophy in the posterior mandible is challenging and difficult, even for experienced clinicians. Short implants can be placed in edentulous atrophic mandibles for avoiding additional bone augmentation or nerve displacements and we found in the literature many articles showing good results (1).

Thus, in severely atrophic mandibles usually we find that the residual bone above the mandibular canal ranges between 0.5-1.5 mm, so short implants placement is not a viable option in this case.

Different options may arise during the treatment-planning phase: 4 implants placed in the anterior region of the mandible, restored with a removable denture in case the patients agree with this type of restoration, onlay bone grafting for restoring the unfavorable intermaxillary relationships so implant placement may be possible in a correct position from a functional and esthetic point of view, the all-on-four concept, can also be considered when restoring full edentulous mandibles and nerve transposition and reposition.

All-on-four concept had shown very good results especially in the mandibles due to increased density of the bone especially in the anterior region. However in cases of severe resorption of the bone, very often the residual height even in the anterior region allows placement only of short implants with average length of 8 mm. Survival rate at 5-year follow-up of 'all-on-four' concept on short implants is relatively low ranging between 51 - 67 % for short implants (2).

Bone grafting is an excellent treatment option for restoring vertical bone loss, for the correction of inter-maxillary relationships, recreating an adequate bone volume not only to allow implant placement but also in a correct, prosthetically driven position (3) that involves several drawbacks, such as: graft harvesting with increased morbidity and a second-site surgery (sometimes extra-orally), a second surgery for removal

of the osteosynthesis screws or the non-resorbable membrane and insertion of dental implants after graft integration (4), requiring longer treatment time, increased morbidity and higher treatment costs.

Although several bone-grafting techniques have been developed and described in recent years for avoiding nerve displacements, multiple complications involving the bone grafts may occur (5) and the results published thus far are relatively disappointing (6).

However, while planning a rehabilitation of the posterior mandible with severe atrophy there we have to take into consideration the fact that in some particular situations, not very often fortunately, the residual bone above the canal is 1.5 mm or less. In those cases even if a graft of 8 mm of bone can be successful we do not know exactly the amount of bone resorption that will take place after the integration of the graft (7).

It is difficult to state which technique is the best for reconstructing the bone loss in posterior resorbed mandibles because all of them have advantages and disadvantages and until now it has not been proven that one of them can enhance the long term survival of the implant placed (8).

Inferior alveolar nerve displacement is a technique that has been used for over 20 years with good survival and success rates (9). The classic technique, described in the literature by many authors (10) which later suffered several modifications (11), has the indisputable advantages of allowing for the simultaneous placement of implants during surgery, a reduction in treatment time compared with other techniques that require a long waiting period before implant insertion together with additional surgeries and good primary stability due to bi-cortical engagement and placement of the implants in native basal bone (12).

The major inconvenience is an alteration, for various periods of time, in the sensory function of the mental nerve (13).

Such alterations can be avoided by the use of a meticulous surgical procedure, state-of-the-art surgical instruments, and solid surgical experience.

In 1977, Alling described a technique for lateral repositioning of the inferior alveolar neurovascular bundle to ease neurosensory disturbances due to denture pressure on the mental nerve (14). Although implants were not inserted, the procedure dramatically improved the patient's quality of life and allowed for continued denture wear.

The surgical protocol was revised 10 years later by Jensen and Nock and allowed for simultaneous implant placement in the atrophic mandibular posterior region (15). Post-surgical complications included altered sensitivity in the area served by the inferior alveolar nerve; this sensitivity recovered gradually over the ensuing 5 post-operative weeks.

The procedure requires careful pre-operative planning, imaging, and extremely precise surgical technique (16), to avoid the complications represented by transient or permanent neural disturbances (17) in the area of the inferior alveolar and mental nerves or fracture of the mandible (18).

## Material and Methods

### Study population

We analyzed retrospectively, 7 patients in whom we performed unilateral or bilateral inferior alveolar nerve repositioning followed by full arch rehabilitation. Written consent was given by the patients for their information to be stored in the hospital database and used for research. Ethic committee approval was waived by the Titu Maiorescu University review board due to the retrospective nature of the study.

Their ages ranged between 19 and 57 years, they had between 0.5 and 1.5 mm of residual bone height above the mandibular canal, they were non-smokers, and they agreed to a follow-up at between 7 and 120 months post-surgery.

### Surgical technique

After clinical and radiological assessment of these patients, and based on our previous experience with this technique, we conclude that these special cases required a different approach because of inherent anatomical and morphological changes.

All surgeries were performed under general anesthesia. Premedication with antibiotics (amoxicillin or clindamycin) and steroids (dexamethasone) was administered one day prior to surgery.

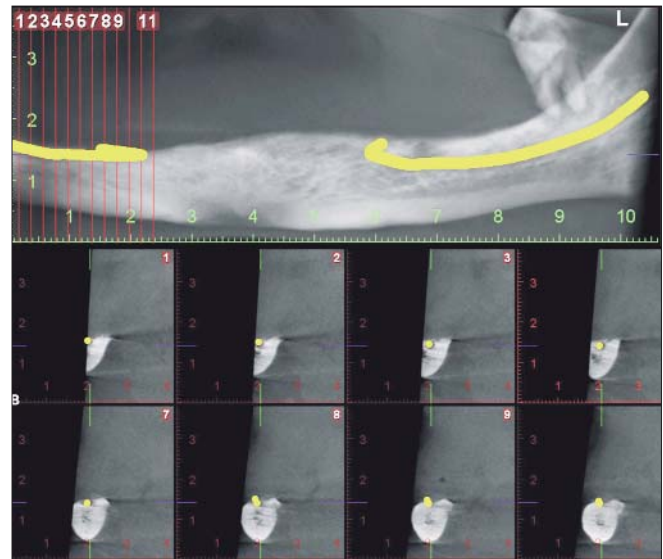
The following pitfalls are characteristic of these atypical cases:

- The marked atrophy of the posterior mandible influences the topography of the mental foramen; therefore, the mental nerve emerges on top of the residual crest (Fig. 1).
- Due to bone resorption, the surface of the keratinized tissue represented by attached gingiva is quantitatively reduced, and sometimes the patients are left with only a narrow strip of ca. 1-2 mm (Fig. 2).

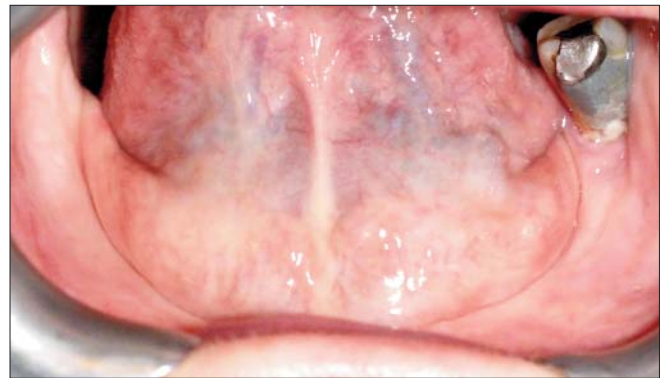
It is imperative to preserve this strip to avoid direct attachment of the free gingiva around the neck of the implant.

To avoid these pitfalls, we implemented the following changes in the surgical technique:

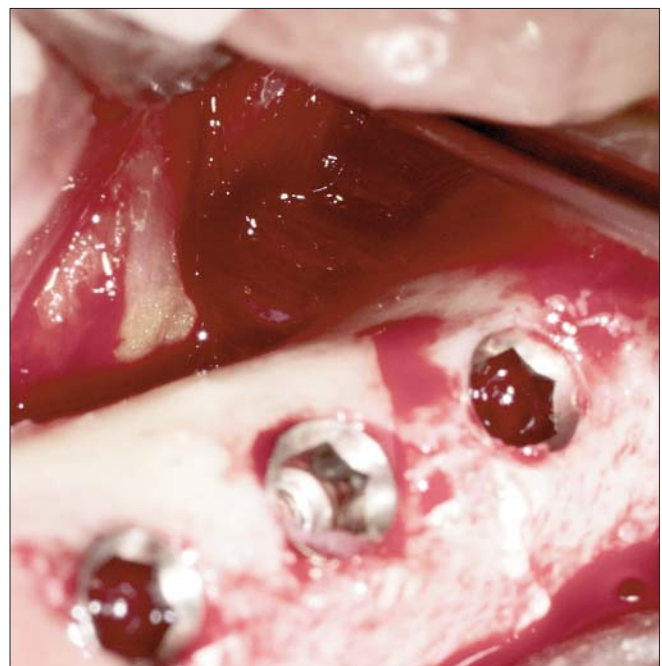
- 1) The mid-crestal muco-periosteal incision described in the classic approach was shifted 0.5-0.7 mm to the lingual aspect of occlusal residual crest of the mandible. This type of incision allowed for better soft-tissue closure and better protection of the mental neurovascular bundle, which, in these cases, is situated on the mandibular crest.
- 2) This approach provides a better visual field, and, in some cases, especially when membranes are needed to cover the implants and the graft, dissection of the mylohyoid muscle can be performed more safely and more accurately than periosteal scoring on the buccal aspect of the flap (Fig. 3).
- 3) The osteotomy was performed in a smaller window (5-6 mm) than described in the usual technique, because the nerve was situated directly on the crest, thus



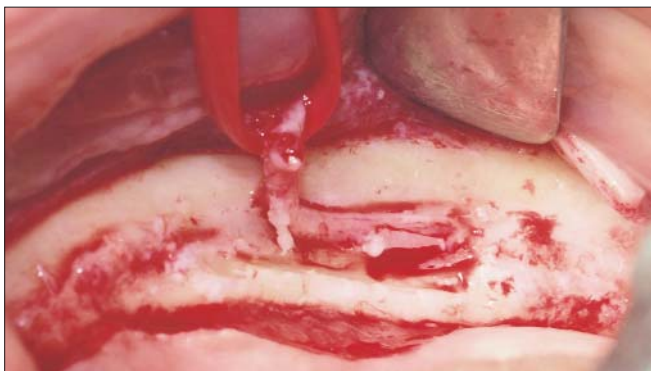
**Figure 1.** Pre-op CT shows that IAN and mental foramen are directly on the residual crest



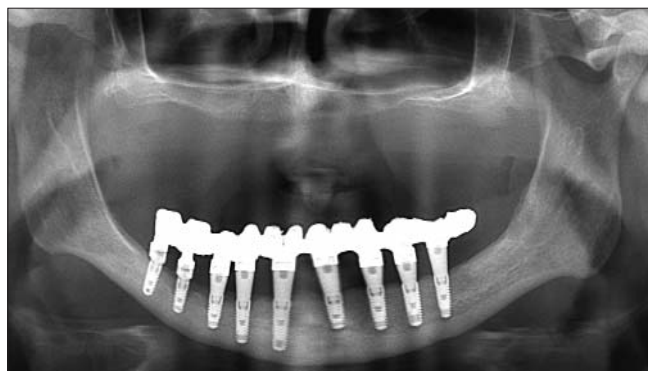
**Figure 2.** Due to extreme resorption there is almost no attached gingiva left



**Figure 3.** Dissection of the mylohyoid muscle can be performed



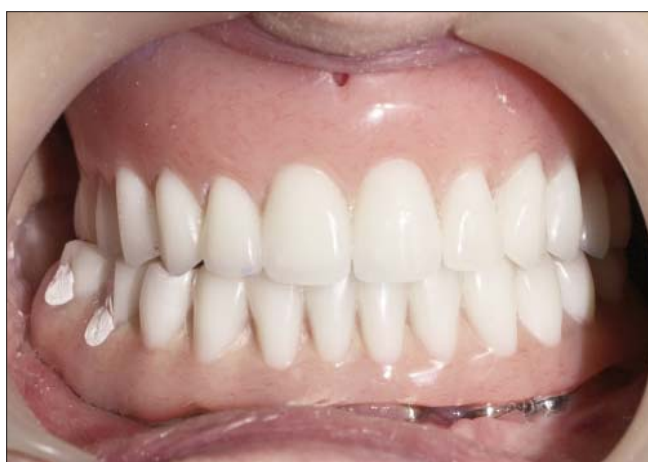**Figure 4.** IAN and mental foramen situated on the residual crest



**Figure 5.** Post-op panoramic x-ray with 10 Zimmer implants and the final restoration

allowing for a better and safer approach (Fig. 4).

- 4) To preserve the maximum amount of bone and to avoid the overheating that could jeopardize the fragile vascular supply, we used an ultrasonic bone surgery device with a thin tip, OT7S (Piezosurgery, Mectron, Italy). We strictly avoided the use of diamond burs or saws, which tend to remove larger amounts of tissue.
- 5) In three cases of fully edentulous mandibles, into which we placed more than 6 implants, we performed provisional immediate loading with a fixed cemented acrylic bridge (Fig. 5).
- 6) Because the mental neurovascular bundle is situated directly on the residual crest, we have chosen the nerve repositioning technique in all these cases, for better protection of the nerve, after the prosthetic loading (Fig. 6).



**Figure 6.** Final restoration

## Results

Overall, 11 inferior alveolar nerve displacement procedures were performed in 7 patients, on severely atrophic mandibles. All cases underwent nerve repositioning. The average age of the patients was 43.29 years (12.37 SD). None of the patients reported smoking. Residual bone above the inferior alveolar nerve ranged between 0.5 mm and 1.5 mm, with an average of 0.93 mm (0.35 SD). In total, 32 dental implants were inserted into the area simultaneous with nerve displacement. The mean implant length was 11.64 mm (1.94 SD); the mean implant diameter was 3.78 mm (0.19 SD). The average follow-up time was 35.71 months (41.75 SD), ranging between 7 and 120 months. No implant loss was observed during the follow-up period.

Immediately following surgery, all patients reported transient neural disturbances for up to 2 months. None of the patients experienced permanent neural deficiencies.

## Discussion

In 1992, Rosenquist reported 10 interventions for transposition of the inferior alveolar nerve with simultaneous implant insertion. Six months after surgery, in 20% of cases, he found

persistent nerve dysfunction in the operated regions, but one year after surgery, neurosensory function had returned to normal in all cases (19).

Morrison, who performed 26 inferior alveolar nerve lateralization procedures on a group of patients, reported osseointegration of all implants. All patients complained of initial sensitivity disturbances in the area served by the mental nerve, and these disturbances resolved progressively in less than a month. In four cases, sensitivity was improved in 6 months (20).

Alveolar nerve repositioning includes risks of neurosensory disturbance of the inferior alveolar nerve (numbness, temporary paresthesia, transient anesthesia) (21,22), or mandible fracture (23) risks of which the patient must be informed and for which the patient, together with the surgeon, should assume responsibility.

Treatment of severe mandibular atrophy poses a difficult challenge for the surgical and reconstruction team. IAN displacement performed under a strict and meticulous protocol, combined with state-of-the-art instruments and ultrasonic bone surgery, dramatically improves the surgical outcome. Additional bone grafting around the nerve is necessary because replacing the bone block that was removed for gaining access to the mandibular canal, may injure the nerve. The use of allografts is

currently a hot topic of discussion (24), but the high resorption rate of the allografts might interfere with the long term survival of the implants. However IAN displacement is a useful technique in severely atrophic mandibles because the risk of neural dysfunction appears to be low (25) but present (26).

The major advantages of this procedure are: immediate insertion of the implants, thus reducing treatment time; elimination of the need for bone grafting from any source, especially in case when severe resorption of the mandible requires major bone grafting procedures (27) thus influencing the cost of the procedure and reducing the potential morbidity related to a second donor site; and the option for immediate loading for enhancement of masticatory function, dramatically improving the patient's quality of life.

The major risk of this surgical procedure is neurological deficiencies of the inferior alveolar bundle, with resultant neurosensory disturbances to the IAN and its terminal branches. Therefore, it is important for the clinician to perform a thorough surgical risk assessment, because the major reason for using this technique is to prevent IAN injury.

A characteristic of the cases presented in this paper is the minimal residual quantity of keratinized tissue on the remaining basal bone, which was overcome by a modified lingual approach of the incision, combined with the release of the mylohyoid muscle.

The osteotomy was carried out with a very fine piezosurgical tip (OT7S), and due to the modified topography of the nerve, which was positioned on top of the residual crest, the procedure was performed with minimal bone sacrifice.

## Conclusions

Extreme cases of severe resorption in the posterior mandible require an approach different from that applied to the more traditional cases of IAN displacement.

In this particular series, we encountered more difficulties than in the routine displacement of the IAN with average bone resorption. Therefore, it is advisable to implement the changes in surgical technique that we described above.

Potential anatomical impediments should be meticulously assessed prior to surgery, and appropriate techniques and instruments should be chosen for these cases to gain a high rate of success with fewer complications.

## Acknowledgements

All authors have equal contribution in preparing and writing the manuscript.

## References

1. Bassi AP, Marcelo Cardoso de Oliveira J, Ramalho-Ferreira G, Faverani LP. Short dental implants in posterior mandible. *J Craniofac Surg.* 2013;24(2):e130-2.
2. Maló P, de Araújo Nobre M, Rangert B. Short implants placed one-stage in maxillae and mandibles: a retrospective clinical study with 1 to 9 years of follow-up. *Clin Implant Dent Relat Res.* 2007;9(1):15-21.
3. Merli M, Lombardini F, Esposito M. Vertical ridge augmentation with autogenous bone grafts 3 years after loading: resorbable barriers versus titanium-reinforced barriers. A randomized controlled clinical trial. *Int J Oral Maxillofac Implants.* 2010;25(4):801-7.
4. Artzi Z, Nemcovsky CE, Tal H, Weinberg E, Weinreb M, Prasad H, et al. Simultaneous versus two-stage implant placement and guided bone regeneration in the canine: histomorphometry at 8 and 16 months. *J Clin Periodontol.* 2010;37(11):1029-38.
5. Chiapasco M, Zaniboni M. Failures in jaw reconstructive surgery with autogenous onlay bone grafts for pre-implant purposes: incidence, prevention and management of complications. *Oral Maxillofac Surg Clin North Am.* 2011;23(1):1-15.
6. Aghaloo TL, Moy PK. Which hard tissue augmentation techniques are the most successful in furnishing bony support for implant placement? *Int J Oral Maxillofac Implants.* 2007;22(Suppl):49-70.
7. Chiapasco M, Zaniboni M, Rimondini L. Autogenous onlay bone grafts vs. alveolar distraction osteogenesis for the correction of vertically deficient edentulous ridges: a 2-4-year prospective study on humans. *Clin Oral Implants Res.* 2007;18(4):432-40. Epub 2007 May 14.
8. Chiapasco M, Casentini P, Zaniboni M. Bone augmentation procedures in implant dentistry. *Int J Oral Maxillofac Implants.* 2009;24(Suppl):237-59.
9. Fernández Díaz JÓ, Naval Gías L. Rehabilitation of edentulous posterior atrophic mandible: inferior alveolar nerve lateralization by piezotome and immediate implant placement. *Int J Oral Maxillofac Surg.* 2013;42(4):521-6.
10. Ferrigno N, Laureti M, Fanali S. Inferior alveolar nerve transposition in conjunction with implant placement. *Int J Oral Maxillofac Implants.* 2005;20(4):610-20.
11. Peleg M, Mazor Z, Chaushu G, Garg AK. Lateralization of the inferior alveolar nerve with simultaneous implant placement: a modified technique. *Int J Oral Maxillofac Implants.* 2002;17(1):101-6.
12. Hirsch JM, Branemark PI. Fixture stability and nerve function after transposition and lateralization of the inferior alveolar nerve and fixture installation. *Br J Oral Maxillofac Surg.* 1995;33(5):276-81.
13. Hashemi HM. Neurosensory function following mandibular nerve lateralization for placement of implants. *Int J Oral Maxillofac Surg.* 2010;39(5):452-6.
14. Alling CC. Lateral repositioning of inferior alveolar neurovascular bundle. *J Oral Surg.* 1977;35(5):419.
15. Jensen O, Nock D. Inferior alveolar nerve repositioning in conjunction with placement of osseointegrated implants: a case report. *Oral Surg Oral Med Oral Pathol.* 1987;63(3):263-8.
16. Nocini PF, De Santis D, Fracasso E, Zanette G. Clinical and electrophysiological assessment of inferior alveolar nerve function after lateral nerve transposition. *Clin Oral Implants Res.* 1999;10(2):120-30.
17. Kan JY, Lozada JL, Goodacre CJ, Davis WH, Hanisch O. Endosseous implant placement in conjunction with inferior alveolar nerve transposition: an evaluation of neurosensory disturbance. *Int J Oral Maxillofac Implants.* 1997;12(4):463-71.
18. Kan JY, Lozada JL, Boyne PJ, Goodacre CJ, Rungcharassaeng K. Mandibular fracture after endosseous implant placement in conjunction with inferior alveolar nerve transposition: a patient treatment report. *Int J Oral Maxillofac Implants.* 1997;12(5):655-9.
19. Rosenquist B. Fixture placement posterior to the mental foramen with transpositioning of the inferior alveolar nerve. *Int J Oral Maxillofac Implants.* 1992 Spring;7(1):45-50.

20. Morrison A, Chiarot M, Kirby S. Mental nerve function after inferior alveolar nerve transposition for placement of dental implants. *J Canad Dent Assoc.* 2002;68(1):46-50.
21. Sandstedt P, Sörensen S. Neurosensory disturbances of the trigeminal nerve: a long-term follow-up of traumatic injuries. *J Oral Maxillofac Surg.* 1995;53(5):498-505.
22. Chrcanovic BR, Custódio AL. Inferior alveolar nerve lateral transposition. *J Oral Maxillofac Surg.* 2009;13(4):213-9.
23. Luna AH, Passeri LA, de Moraes M, Moreira RW. Endosseous implant placement in conjunction with inferior alveolar nerve transposition: a report of an unusual complication and surgical management. *Int J Oral Maxillofac Implants.* 2008; 23(1):133-6.
24. Tănase M, Marin S, Amza S, Toader A. The use of allografts in the surgical treatment of enlarged hiatal hernias. *Chirurgia (Bucur).* 2012;107(2):195-8.
25. Lorean A, Kablan F, Mazor Z, Mijiritsky E, Russe P, Barbu H, et al. Inferior alveolar nerve transposition and reposition for dental implant placement in edentulous or partially edentulous mandibles: a multicenter retrospective study. *Int J Oral Maxillofac Surg.* 2013;42(5):656-9.
26. Yoshimoto M, Watanabe IS, Martins MT, Salles MB, Ten Eyck GR, Coelho PG. Microstructural and ultrastructural assessment of inferior alveolar nerve damage following nerve lateralization and implant placement: an experimental study in rabbits. *Int J Oral Maxillofac Implants.* 2009;24(5):859-65.
27. Esposito M, Grusovin MG, Kwan S, Worthington HV, Coulthard P. Interventions for replacing missing teeth: bone augmentation techniques for dental implant treatment. *Cochrane Database Syst Rev.* 2008;(3):CD003607.