

Carcinoid Tumor of the Cecum Presenting with Acute Appendicitis: A Case Report

E. Çakar¹, S. Bayrak, H. Bektaş, Ş. Çolak, A. Güneyi, M. Mahsuni Sevinç, M. Bağ²

¹Department of General Surgery, Istanbul Training and Research Hospital, Istanbul, Turkey

²Department of General Surgery, Kocaeli State Hospital, Kocaeli, Turkey

Rezumat

Tumoră carcinoidă de cec prezentând tablou clinic de apendicită acută: prezentare de caz

Date generale: Apendicita acută reprezintă cea mai comună cauză de abdomen acut. Tumorile carcinoide de apendice vermiform sunt descoperiri incidentale ce pot determina un tablou clinic de apendicită acută.

Prezentare de caz: În timpul intervenției chirurgicale pentru apendicită acută, o masă solidă de 3 cm, ce nu fusese observată la exterior, a fost palpată la baza apendicelui. Masa și apendicele au fost rezecate în bloc. Examenul histopatologic a decelat o tumoră carcinoidă la nivelul masei.

Concluzii: Scopul prezentării a fost de a atrage atenția asupra faptului că, deși rareori, neoplazmele apendiculare pot prezenta un tablou clinic de apendicită acută, și de a sublinia că acestea, în special cele de la baza apendicelui și din cec, pot trece neobservate în timpul laparoscopiei. Importanța tomografiei computerizate trebuie menționată în asemenea cazuri.

Cuvinte cheie: apendicită acută, tumoră carcinoidă, laparoscopie, tomografie computerizată

Abstract

Background: Acute appendicitis is the most common cause of acute abdomen. Carcinoid tumor of the appendix is a rare incidental finding that can present with the clinical picture of acute appendicitis.

Case report: During open surgery for acute appendicitis, a 3 cm solid mass, not noticed externally, was palpated at the base of the appendix. The mass and the appendix were excised by en-bloc wedge resection. The histopathological examination of the lesion revealed carcinoid tumor.

Conclusion: The aim of this presentation is to remind that neoplasms of the appendix may, although rarely, present the clinical picture of acute appendicitis, and to highlight that they, particularly those located at the base of the appendix and in cecum, may be overlooked during laparoscopy. The importance of preoperative computerized tomography in such cases has to be underlined.

Key words: acute appendicitis, carcinoid tumor; laparoscopy, computed tomography

Corresponding author:

Dr. Ekrem Çakar
Department of General Surgery
Istanbul Training and Research Hospital
Istanbul, Turkey
E-mail: ekremcakar@hotmail.com

Introduction

Acute appendicitis is the most common clinical picture that requires surgery in emergency surgery practice. The likelihood of having acute appendicitis is 7 in the lifetime of an individual (1). The most common cause of acute appendicitis is obstruction which may result from fecaliths, foreign bodies, gallstones, and cecal tumors or primary tumors of the appendix. Less than 1% of acute appendicitis cases have been associated with malignancy (2). Ninety percent of carcinoid

tumors are benign in nature and great majority are smaller than 1 cm (3,4). Of these tumors, are located at the tip of the appendix, whereas approximately 10 are located at the base (5). The aim of this presentation is to remind that some rare lesions might be masked by acute appendicitis clinically and to lay stress on laparoscopic approach in such cases.

Case report

A 19-year-old female patient presented to emergency room with complaints of abdominal pain and loss of appetite for two days. Her physical examination revealed muscular defense and rebound tenderness in the right lower quadrant.

Results of laboratory tests were as follows hemoglobin (Hb): 12.1 g/dL, hematocrit (Hct): 41, white blood cells (WBC): 21,100 K/mL, platelet (PLT): 218,000 K/mL and beta-human chorionic gonadotropin (β HCG): 2 mIU/mL.

Abdominal computed tomography (CT) scan revealed edematous bowel loops in the right paracecal region and free fluid collection at the location of cecum. There was thickening in the walls of the lumen that was located in the area consistent with cecum and appendix. There was excessive free fluid in the pouch of Douglas. According to these findings, evaluation together with the clinical findings was recommended in terms of gastrointestinal tract perforation.

Since gynecology consultation did not consider any gynecopathology, the patient underwent surgery with a pre-diagnosis of acute abdomen. Surgical exploration revealed an appendix approximately 6 cm in length and 2 cm in width; there was acute inflammation, hyperemia, and perforation in the proximal part. Additionally, a 3x3x2 cm mass lesion was palpated in the region adjacent to the appendix and cecum. Fluid collection consistent with perforation was observed in the right paracolic area in the pouch of Douglas. Appendix and the mass were excised with en-bloc wedge resection, providing that the surgical margin was negative macroscopically and the surgical procedure was completed. Pathological examination revealed a tumor with a size of 3.5x2.5x2 cm that was located 1 cm from the proximal surgical margin (Fig. 1).

According to the World Health Organization (WHO) 2000 classification, the case is included in the well-differentiated neuroendocrine carcinoma group, since it invaded the mesoappendix. Since the diameter of the tumor was larger than 2 cm, it was considered as a stage 3 tumor (PT3) according to the European Neuroendocrine Tumor Network (ENET); and since the diameter of the tumor was smaller than 4 cm, it was considered as a stage 2 tumor (PT2) according to American Joint Committee on Cancer (AJCC).

Discussion

Malignancies of the appendix are quite rare and seen by 0.5-1.4 following overall appendectomies (6). Although carcinoid tumors can be seen in all ages, they are more common in adults and females (7). Tumors are usually detected incidentally during laparoscopy performed for another reason, or they appear associated with acute inflammation of the appendix. These

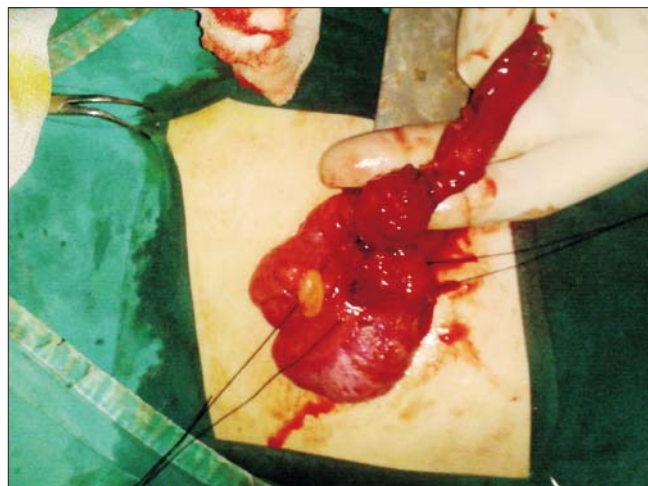


Figure 1.

tumors are rarely suspected before surgery. Furthermore, 50 of these tumors are diagnosed during surgery (8). However, carcinoid tumor-related clinical symptoms seen particularly in the presence of metastases are important for preoperative diagnosis. It is known that these tumors secrete many gastrointestinal peptides and hormones, 5-hydroxytryptamine (serotonin) being the leading. Secretion of these substances may lead to carcinoid syndrome with clinical signs including skin flushing usually in the head-neck and upper part of the body, diarrhea, asthma or wheezing, valvular cardiac disease, and facial telangiectasia (9). Preoperative anamnesis of the present case did not reveal any carcinoid syndrome-related clinical signs and the results of postoperative laboratory analyses were within normal limits. In many series, carcinoid tumors are the most common neoplasms of the appendix and accounts for 50 of the primary lesions of the appendix (5,6,10). However, a new evaluation performed by The National Cancer Institute's Surveillance, Epidemiology and End Results program found that mucinous adenocarcinoma is the most common diagnosis in 37 of all reported cases and the annual incidence of age-related malignancies is 0.12 out of 10,000. Carcinoid tumors are the second leading histological type of cancer with an incidence of 33 in all cases (8).

Gastrointestinal carcinoids are mostly located in the small intestine and rectum, followed by the appendix. The likelihood of appendiceal carcinoids with carcinoid syndrome is quite low, unless there is widespread metastasis, of which the incidence is 2.9. Similar to the carcinoid tumors at other sites, there is a close relation between the size of the appendiceal carcinoid tumor and metastasis. Approximately 90 of carcinoid tumors have benign characteristics, and majority of the cases are smaller than 1 cm. Prognosis is worsened if the tumor size is greater than 2 cm. Whilst the risk of metastasis is 2 for the tumors smaller than 1 cm, risk reaches up to 80 for lesions larger than 2 cm. Overall 5-year survival is considered to be higher than 90 in appendiceal carcinoid tumors (3,4). Overall relapse rate is about 2. Most of the carcinoids are located at the tip of the appendix. Malignant potential is associated with

Table 1. Indications for right hemicolectomy in the treatment of appendiceal carcinoid tumors (4,11-13)

Indications for right hemicolectomy
Lesions larger than 2 cm
Tumors localized at the base of the appendix
Invasion of lymphatic channels, serosa and mesoappendix
Presence of regional lymph node metastases
Mucin production (mucinous carcinoid tumors)
Cellular pleomorphism with a high mitotic index
Childhood carcinoid tumors

tumor size; extension outside of the appendix is very rare for the tumors smaller than 1 cm and has a low probability. A study found that 78 of appendiceal carcinoids were smaller than 1 cm, 17 were between 1 and 2 cm, and only 5 were greater than 2 cm. Their treatment rarely requires more than simple appendectomy. Right hemicolectomy is recommended for the tumors smaller than 1 cm extending into mesoappendix and for all tumors greater than 1.5 cm (5,6,10). Besides the size of the tumor, many other factors play a role for right hemicolectomy. Indications for right hemicolectomy in the treatment of appendiceal carcinoid tumors are specified in Table 1 (4,11-13). The current tumor was 3 cm in size, located at the base of the appendix and invaded mesoappendix. According to these findings, right hemicolectomy was planned. The patient was prepared for elective surgery. Laboratory test results were normal.

Abdominal CT and positron emission tomography (PET)-CT revealed normal findings. The patient underwent right hemicolectomy. Histopathological examination of 54 lymph nodes revealed carcinoid tumor metastasis in four of them. The patient was transferred to the oncology department for follow-up.

Tumors of the appendix may cause acute appendicitis by obstructing the appendiceal lumen like a fecalith in certain cases. The cecum and the mesoappendix should be carefully evaluated in patients who undergo surgery for acute appendicitis. Carcinoids should be suspected in the event of a solid, yellow, tumor-like mass seen in the appendix.

The mass was detected by careful palpation in the present case that underwent open surgical procedure. Today, laparoscopic surgery is widely used but does not have the ability of detection as open surgery has. Detection of the lesions that cannot be seen with naked eye is difficult with laparoscopy, as was in our case. If we had performed a laparoscopic procedure, we would have probably been unable to detect the lesion.

In the literature, a case was reported with a submucosal mass detected in the cecum, the patient underwent colonoscopy due to mucin islets detected at the base of appendix on histopathological examination performed after laparoscopic appendectomy, and right hemicolectomy was performed. Histopathological examination revealed cecal carcinoid tumor, which could have not been detected during the first intervention (14). Nevertheless, CT should detect a 3 cm lesion as in the present case. Although we performed preoperative CT, the lesion could not be detected on the

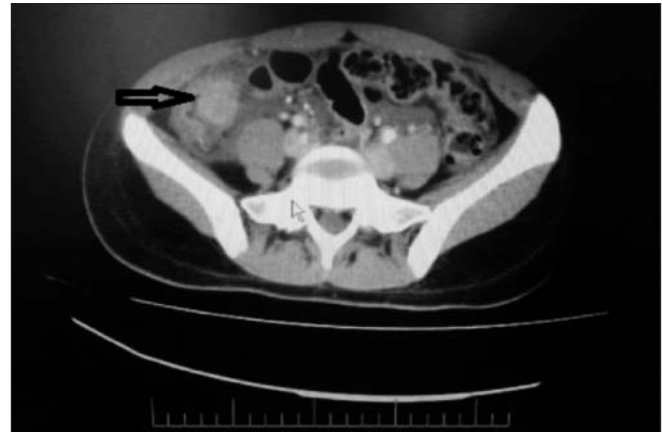


Figure 2.

evaluation done under emergency conditions. The mass was noticed when the CT scans were evaluated retrospectively (Fig. 2).

Conclusion

It should be kept in mind that a mass obstructing the appendix lumen might present with the clinical picture of acute appendicitis during laparoscopic surgery. Careful evaluation of CT scans by experienced physicians may be beneficial in detecting such unpredictable concomitant lesions.

References

1. Tumay V, Ozturk E, Ozturk H, Yilmazlar T: Appendiceal endometriosis mimicking acute appendicitis. *ActaChirBelg* 2006, 106:712-713.
2. Blair NP, Bugis SP, Turner LJ, MacLeod MM: Review of the pathologic diagnoses of 2,216 appendectomy specimens. *Am J Surg* 1993, 165:618-620.
3. Pastore C, D'Annibale A, Piazza A, Pignata G, Conte C, Berna G, Pavanello M, Di Falco G: (Diagnosis and treatment of gastrointestinal carcinoid. Report of a clinical case with duodenal site). *Minerva Chir* 1997, 52:283-287.
4. Deans GT, Spence RA: Neoplastic lesions of the appendix. *Br J Surg* 1995, 82:299-306.
5. Roggo A, Wood WC, Ottinger LW: Carcinoid tumors of the appendix. *Ann Surg* 1993, 217:385-390.
6. Connor SJ, Hanna GB, Frizelle FA: Appendiceal tumors: retrospective clinicopathologic analysis of appendiceal tumors from 7,970 appendectomies. *Dis Colon Rectum* 1998, 41:75-80.
7. Hermans JJ, Hermans AL, Risseeuw GA, Verhaar JC, Meradji M: Appendicitis caused by carcinoid tumor. *Radiology* 1993, 188:71-72.
8. McCusker ME, Coté TR, Clegg LX, Sobin LH: Primary malignant neoplasms of the appendix: a population-based study from the surveillance, epidemiology and end-results program, 1973-1998. *Cancer* 2002, 94:3307-3312.
9. De Vita VT, Hellman S, Rosenberg SA: Cancer of the Endocrine System. In *Cancer: principles and practice of oncology*. 4th edition. Edited by Morton AJ, Levin B, Jensen RT. Philadelphia: Lippincott Company; 1993:1371.
10. Deans GT, Spence RA: Neoplastic lesions of the appendix. *Br*

- J Surg 1995, 82:299-306.
11. Adolfsson G: Benign and malignant tumours of the appendix. *ActaChirScand* 1974, 140:151-155.
 12. Gouzi JL, Laigneau P, Delalande JP, Flamant Y, Bloom E, Oberlin P, Fingerhut A: Indications for right hemicolectomy in carcinoid tumors of the appendix. *The French Associations for Surgical Research. SurgGynecolObstet* 1993, 176:543-547.
 13. Parkes SE, Muir KR, al Sheyyab M, Cameron AH, Pincott JR, Raafat F, Mann JR: Carcinoid tumours of the appendix in children 1957-1986: incidence, treatment and outcome. *Br J Surg* 1993, 80:502-
 14. Shayani V: Mucinous cystadenoma of the cecum missed at laparoscopic appendectomy. *Pitfalls in laparoscopy. Surg Endosc* 1999, 13:1236-1237.