

## Morbidity after Ultra Low Anterior Resection of the Rectum

N.D. Straja, S. Ionescu, E. Brătucu, M. Alecu, L. Simion

First Surgical Clinic, "Prof. Dr. Al. Trestioreanu" Institute of Oncology, Bucharest, Romania

### Rezumat

#### *Morbiditate după rezecție anterioară ultra-joasă de rect*

Rezecțiile anterioare de rect, utilizate ca alternativă la amputația de rect, sunt folosite din ce în ce mai frecvent, ajungând să fie indicate pentru neoplasme situate de la 7 până la 4 cm distanță de orificiul anal. Complicațiile rezecțiilor anterioare joase și ultra-joase nu sunt deloc neglijabile, iar rata de recurență locală neoplazică este semnificativ mai mare față de amputația de rect. Cu toate acestea literatura de specialitate recomandă rezecțiile anterioare de rect joase și ultra-joase, chiar dacă uneori indicațiile metodei sunt fortate sau intervențiile sunt efectuate la solicitarea pacientului, în scopul evitării colostomiei definitive. Autorii acestui articol își propun să contureze un tablou real al modificărilor produse de rezecțiile anterioare de rect, joase și ultra-joase, astfel încât, fără a nega meritele acestor rezecții, să pună în evidență întreaga patologie postoperatorie care apare la acești pacienți. Rezecțiile ultra-joase de rect, până la 3-4 cm de orificiul anal, aduc modificări morfo-funcționale importante pentru actul defecației și pentru continența anală. Aceste modificări de tranzit colo-anal au o incidență mult mai mare decât tulburările genito-urinare postoperatorii. Un alt aspect important desprins în urma studiului de față este legat de incidența crescută a dezunirilor anastomotice, a stenozelor și a diverselor grade de inconti-

nență, complicații care adesea nu pot fi rezolvate decât prin completarea amputației de rect și colostomie definitivă. În plus rezultatele funcționale ale acestor rezecții ultra-joase nu sunt întotdeauna la nivelul așteptat de către pacient. Deasemenea din punct de vedere al performanței chirurgicale, cota mare de complicații specifice ale procedurii pune sub semnul întrebării această tehnică. Pentru toate aceste motive autorii consideră necesară revizuirea limitei inferioare la care poate să coboare o rezecție anterioară de rect.

**Cuvinte cheie:** rect, neoplasm, rezecție anterioară, ultra-joasă, limită

### Abstract

Anterior resections of the rectum, used as an alternative to amputation of the rectum, are performed more and more frequently, being presently indicated for neoplasms located at a distance of 7 to 4 cm from the anus. Complications of low and ultra low anterior resections are not at all negligible, and local neoplastic recurrence rate is significantly higher than after amputation of the rectum. However, literature data recommends low and ultra low anterior rectal resections, even if sometimes the method indications are pushed to the limit or the interventions are performed at the patient's request, in order to avoid permanent colostomy. The authors of this article aim to outline a true picture of the changes caused by anterior resections of the rectum, low and ultra low, so that, without denying the merits of these resections, the entire post-operative pathology that occurs in these patients is depicted and understood. Ultra low rectal resections, up to 3-4 cm from the anus, bring important morphological and functional changes to the act of defecation and to anal continence.

---

Corresponding author: Sinziana Ionescu, MD  
First Surgical Clinic, „Prof. Dr. Al. Trestioreanu”  
Institute of Oncology  
252nd Fundeni Road, 2nd District, 022328  
Bucharest, Romania  
E-mail: ionescu\_sinzy@yahoo.com

These changes in colo-anal bowel movement have a much higher incidence than postoperative genitourinary disorders. Another important aspect emerging from the present study is related to the increased incidence of anastomotic disunity, stenosis and various degrees of incontinence, complications that often can only be solved by completion of rectum amputation and permanent colostomy. In addition, the functional outcomes of these ultra low resections are not always at the level expected by the patient. Also, in terms of surgical performance, the higher share of specific complications of the procedure raises questions with regard to the technique. For all these reasons the authors consider it necessary to review the lower limit to which an anterior rectal resection can descend.

**Key words:** rectum, neoplasm, anterior resection, ultra low, limit

## Introduction

More and more frequently we encounter in anterior resection surgical practice: low, very low and ultra low resection of the rectum, as an alternative to amputation of the rectum. The method is used for neoplasms located 7 cm from the anal orifice or below this level, including for tumours located at 4 cm from the anal orifice. According to literature data, low resections are performed for neoplasms located 6-7 cm from the anal orifice, very low resections are reserved for localizations under 6 cm to 5 cm from the anal orifice, and finally, for neoplasms below 5 cm ultra low resections are performed. Currently there are surgeons indicating ultra low resection even for tumours 4 cm from the anus. It is the current literature as well that provides data on the postoperative morbidity after very low and ultra low resections. (1-6)

Their complications are not at all insignificant: 17-20% anastomotic fistula, 15-20% stenosis, 50-60% anal dysfunction, 15-30% temporary safety colostomy complications. (7-10).

To these shortcomings we must add one more: higher rate of local neoplastic recurrence, (10% vs. 3%) for neoplasms located less than 7 cm away from the anus. It appears clear from major studies that morbidity increases as the resection descends towards the anal canal. However, the caudal limit of the resection continued to be lowered as if it were part of a genuine competition. It has come to performing resections with the inferior limit in full anal canal, 2-3 cm from its external orifice. Currently, from 90% amputations of the rectum in the 1970s, we have reached 21% in 2004 (11). Moreover, the performance of a surgical service is appreciated according to reduced frequency of amputations as well (11,12). However, when a surgical procedure presents a 50% postoperative morbidity it is imperative that its indications be reassessed. This statement is valid only for very low and ultra low resections, with the inferior tranche under 5-6 cm from the anus. In these situations, there is virtually no rectal stump, the anastomosis being in fact

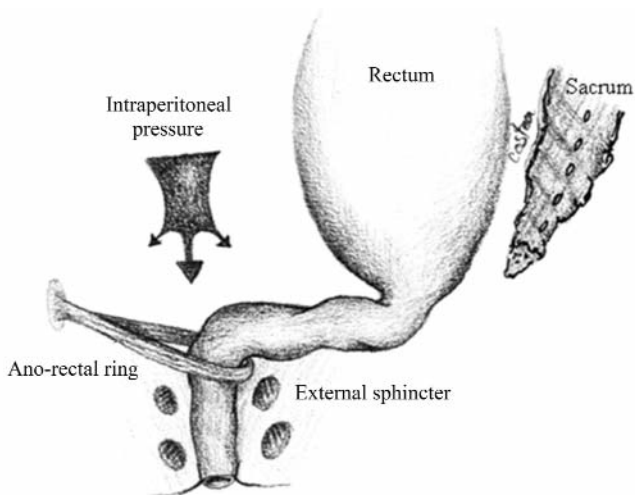
coloanal. Further on, very low and ultra low resections will be designated by the abbreviation ULAR.

The specialized literature continues to recommend these ULARs. Of course, some are "forced" or performed "at the patient's request" to avoid permanent colostomy. We had the unpleasant opportunity to observe a number of such cases of coloanal anastomosis with severe postoperative complications, debilitating, which were then resolved by amputation of the rectum. Months of intense suffering, repeated unsatisfying interventions, and ultimately, death or amputation with permanent colostomy. All these cases involved ULAR. ULAR indication remained adamant however, being given even by those publishing the daunting results of postoperative morbidity (13). We tried to identify the reasons for which this type of resection is accompanied by such a complication rate. The purpose of this article is to outline a real picture of the changes determined by ULAR, both in terms of morphology, and of physiology of the anal-sphincter region. We do not intend to criticize the ULAR procedure. This technique is of definite value. However, forcing the indication of this technique by lowering too much the anastomosis, 3-4 cm from the AO, entails a vast postoperative pathology.

The current indication for intersphincteric coloanal anastomosis, a genuine ULAR, was established by Bretagnol and RULLIER in 2004 (15), being those who described the technique. This technique addresses tumours with the inferior edge 5 cm from the anal orifice. Another landmark is the pectineal line. The tumour was located 3 cm above the lower edge of this line. In essence, resection will remove 1cm under the tumour, which compromises the pubo-rectal bundle merged with the deepest (upper) portion of the external sphincter (13,15). Obviously ULAR will be performed in full physiological anal canal, shortening it (14). The technique involves removing the internal sphincter 1-2 cm below the tumour, and sometimes the upper segment of the external sphincter is also removed. We wish to understand the causes leading to such undesirable developments, including: fistula, stenosis, stercoral peritonitis, pelvic abscesses, major defecation disorders, local recurrence. Genitourinary dysfunction are not the object of this article.

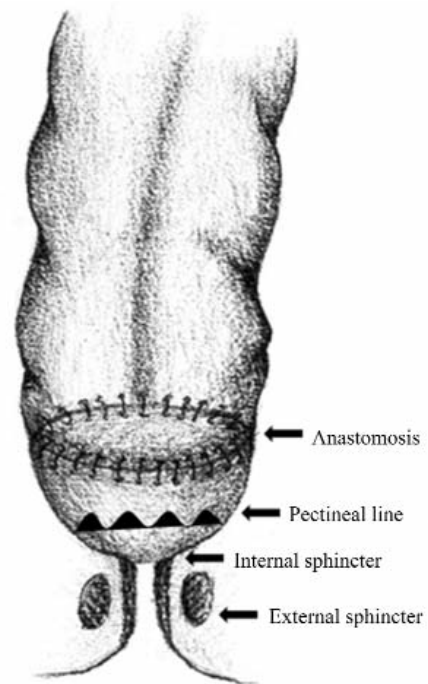
## *Anatomo-functional changes after ULAR*

The anatomic anal canal has a length of 3 cm, stretched between the anocutaneous line and the pectineal line. The physiological anal canal includes 2 more centimetres above this line. In total it is estimated that the anal segment is 5 cm long, in accordance with the actual sphincter activity (16). The normal anatomy controlling and ensuring normal continence is ensured by the following structures: anal sphincter apparatus, levator ani muscles, anorectal ring and anorectal valve. All these structures are evidently under the command of anorectal innervation (15,16,18). Looking at Fig. 1 we can observe that anal continence depends on a number of anatomical factors essential to ensuring this function. Complete removal of the rectum, and sometimes of a part of the anal canal, causes structural and functional changes that could significantly alter

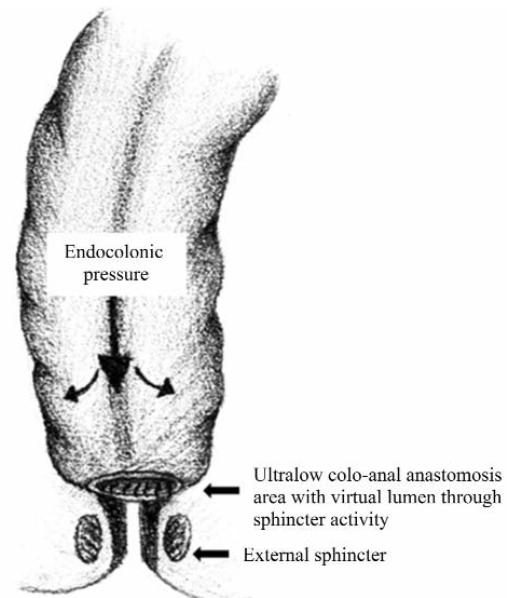


**Figure 1.** Sketch of the structures ensuring anal continence

the function of defecation. ULAR completely removes the rectum and brings together the colon and the anal canal, by anastomosis. Resection lowered to 3-4 cm from the anal orifice has a series of consequences. It suppresses the anorectal ring (angle), located at the junction of the pubo-rectal bundle in the levator ani muscles with the upper segment of the external sphincter. The anorectal ring is at 5 cm from the anal orifice, i.e. 2-3 cm above the pectineal line, and has a cardinal role in continence. A second consequence is the disappearance together with the rectum of the anorectal valve (flap valve), that maintains the anal canal closed and opens when the pressure gradient in the rectum increases (18). ULAR also creates another inadequate local condition: virtually the anal canal is basically closed when it is at rest. The anastomosed colon develops pressures of 100-200 mm Hg, such as those typical for the rectum during defecation (16,17,20). After performing coloanal anastomosis there is a period of adaptation for the two anastomotic partners. While the colic side develops pressures of about 100 mm Hg, the anal canal, and thus the anastomosis, remain closed. There are no nerve connections between the anal canal and the anastomotic colon, so there is no functional synergism, as in the case of the rectum and anus. No opening of the anal canal will follow a propulsive contraction of the colon. Therefore, the colonic side of the anastomosis expands, but the anal segment does not open to retrieve and to amortize the pressure upstream. The anal canal is closed at rest and nervously disconnected from the colon. In the absence of the rectum, the reflex act of defecation is interrupted. As a result, endocolic pressure will be exerted on the walls of the colon and on the closed anastomosis, the anal canal being at rest. Thus, some anastomotic clips can succumb to this pressure with no drain valve through the anus, hence: fistulae, pelvic abscesses and more. Anastomoses 3-4 cm from the anal orifice are credited with 30% fistula rate in the best statistics. Ileostomy, anal dilatation and various plasties do not reduce the rate of these complications, but only decrease their magnitude. Also, a coloanal anastomosis is an almost permanently closed anastomosis, excepting the moments of defecation. A conse-



**Figure 2.** Colorectal anastomosis above the pectineal line (maintaining the rectal stump)



**Figure 3.** Sketch of ultra low coloanal anastomosis behavior

quence proven in practice is that some of these ULARs progress to stenosis, because the anal side is almost permanently closed. This causes the healing of the coloanal anastomosis to be directed mainly towards stenosis (Fig. 2 and 3).

### Consequences of ULAR

The functional anatomical changes described above entail a number of consequences. It is obvious that the caudal exten-

sion of the resection down to 3-4 cm from the anal orifice determines the partial sacrifice of the upper sphincter level. Resection down to 3 cm from the anus lifts the segment called physiological anal canal entirely, located 2 cm above the pectineal line. Continence and defecation remain the exclusive responsibility of the 3 cm of anatomical anal canal. Absence of the rectum, reduction of the anal canal and of the sphincter level determine a number of disabilities of anal continence. These would be the anatomical consequences of ULAR. But there are also physiological consequences due to nerve disconnections occurred during surgical dissection. The rectum and anal canal benefit from a synergistic innervation over the act of defecation. Complete disappearance of the rectum and restoration of digestive continuity by coloanal anastomosis will create a series of functional changes. Two anastomotic partners whose innervation is contrary, antagonistic, are put in contact. The two anatomical segments, colon and anal canal, are nervously disconnected, and therefore unable to ensure normal functionality of releases. Sympathetic innervation of the colon determines its relaxation, and the parasympathetic one - dorsal nucleus of the vague - provides contractile motor activity. The anal canal behaves in an opposite manner: the sympathetic nerve system contracts the sphincter apparatus, and the sacral parasympathetic system relaxes the anus. The conditions of a motor neuro dyssynergism are created (15,17).

All these morpho-functional changes due to ULAR lead both to decreasing resting anal tone, and to lowering voluntary contraction pressure. The causes of these decreases in anal tone result from partial sacrifice of the pubo-rectal bundle that innervates the anorectal ring, and from partial interception of sympathetic S2-S4 responsible for the tonicity of the anal canal. The consequence: the high pressure area correspondent to a normal continent anal canal is reduced. This results in dysfunctions of defecation such as urgency or incomplete defecation, erratic releases, partial or total incontinence. Decreased anal pressure generates partial reflex incontinence with conservation of conscious continence.

### **Local recurrence after ULAR**

Today widely recorded in the literature, as the rule of principle, is the need to remove 1 cm below the rectal tumour, but 5 cm of the mesorectum below the tumour limit. This rule cannot always be obeyed. For a neoplastic lesion located 5 cm from the anal orifice, ULAR should sever the rectum 4 cm from the anus, but to descend with lax tissue excision under the cone of the levator ani muscles, the latter marking the lower limit of the mesorectum. So resection should descend and excise the inferior perirectal space (the ischio-rectal fossa) to meet the requirement of removing 5 cm of adipose tissue under the tumour, as stipulated in the operating protocols (17). Is this possible in an anterior resection, either laparoscopically or by classic approach? This gesture is never performed. Thus it follows that the principles of oncological safety are not respected - the lower perirectal lymph tissue can present disseminated cells from a malignant tumour located 5 cm from the anal orifice. Literature

data show a level of 13-19% local recurrence after ULAR (Eichhoff), while after resections for cancers located >7cm the recurrence rate is 3%. The lower the tumour is located, the nearer to the anus is the resection performed, and the more the recurrence rate increases. (9,12,21,34)

### **Morbidity inherent to ULAR**

Summarizing, it can be argued that ULAR, meaning resections of the rectum located at  $\leq 5-6$  cm from the anal orifice, are accompanied by complications and disorders that not infrequently turn the final assembly into a perineal colostomy, severely disabling and unable to be accompanied by a prosthesis.

Recent data obtained from 120 patients submitted to ULAR show a 27% percentage of specific complications: 16% pelvic abscess, 11% anastomotic fistula (22). All patients had a temporary ileostomy. In the same group 30% developed local recurrences. All patients presented appreciable anal disorders 12 months from the closing of the stoma, according to the Wexner index, index which if  $\geq 2$  certifies the existence of various degrees of anal incontinence. The group we are referring to recorded a Wexner index = 10, which indicates the existence of notable defecation disorders (22,23,24). Resection with the lower limit 3-4 cm from the anal orifice with anastomosis at this level creates the following changes in the anatomy and function of the anal region:

- suppression of the puborectal muscle (part of the levator ani muscles, playing the role of a "tie" that creates and maintains the anorectal ring and angle). This muscle bundle was 1-2 cm above the pectineal line and is dissociated during ULAR, resulting in a rectitude of the coloanal anastomotic segment with consequences on reflex continence.
- cancellation of the anorectal angle acting as a valve by completely removing the rectum and maintaining the anal canal
- resection of, the lower limit up to 3 cm from the anal orifice breaks the cone of the levator ani muscles, especially in the area of the pubo-rectal bundle, which it abolishes
- the high pressure area is reduced both by nerve interception (especially sympathetic with pelvic plexus origin), and by the anatomical changes mentioned above. The coloanal pressure gradient is changed by reduction in anal tone as a consequence of sympathetic innervation damage, with a prevalence of relaxing parasympathetic stimulation. Anal segment resting pressure is ensured by the internal sphincter to a rate of 85%, while the striated external sphincter contributes to only 15% (20). The result - decreased anal resting tone with varying degrees of incontinence
- lack of any nervous interconnections between colon and anal canal. Colic innervation works contrary to anal innervation, the two vegetative types of innervation balancing each other.
- the normal act of defecation summarily involves the



relaxation of the levator ani muscles and of the puborectal muscle, fading of the anorectal angle, relaxation of the internal anal sphincter that allows advancement of the bowl simultaneous with external sphincter contraction. All these mechanisms are disrupted by ULAR.

What are in fact the consequences of all these structural and functional changes of the ano-sphincter apparatus? The literature abounds in enumerating and counting these debilitating disorders. Thus, a 25-60% morbidity after ULAR is recorded, including 20% more common anastomotic dehiscences after mechanical anastomosis (4,9,12,21,28,31). Other statistics recorded 40.7% anastomotic complications: stenosis, fistulas, necrosis after ULAR (18-20). The Dutch Colorectal Cancer Group recorded fistulas in 12-17% of cases, 7% recurring (Carlsen Karanjit, Heald). Moreover, we find significant disorders of defecation as well: erratic defecation 44%, urgency (19-36%), constipation 20%, partial incontinence 45-50% (Soiling), total incontinence 10% (6,13,21). All these increase in frequency as the anastomosis descends to and into the anal canal. With high anterior resection all defecation disorders are near 9% (5). Overall 66% of patients with ULAR present bowel movement dysfunction with repeated and uncontrolled releases (4,21). Eversince the 1970s, D'Allaines (quoted by 22) notes that 40% of patients in whom only 4 cm of the anal canal were kept would present continence disorders. More recently, most studies register perfect continence in 43-67% of cases and good in 20-30% (21,23). Other studies provide the following percentages: 15% slippage, 3-5% soilage, 22% urgency (24). Manometric recordings showed decreased resting anal tone in these patients with abnormal discharge. A study by Eichhoff G. (9) covering neoplasms located on average 4.4 cm from the anal orifice recorded 40.7% complications of the ultra low anastomosis, and incontinence was 10%. Note that in 36.4% of patients ileostomy was needed due to ULAR consecutive sequelae. Basically, preserved anus but associated with ileostomy. The same author (9) quotes Kirwan which records the need for definitive colostomy in 39% of patients undergoing ULAR. This remarkable share of dysfunctions has led some surgeons to appreciate that there are no notable differences between QL after ULAR, and after amputation of the rectum (29). Also note that this review of the literature did not include post-operative genitourinary disorders. According to K Havenga and W Enker after low and ultra low resections, 67% of patients over 60 years sustain sexual activity and 87% of men present orgasm. The percentages are triumphal to say the least (22).

Nowadays amputation of the rectum is on an obvious and just-deserved declining slope. Performed in 90% of patients in the 1970s, it decreased to 37% in the 1990s, and to 21% in 2004 (10). According to current precepts, amputation remains an indication under the following circumstances: neoplastic involvement of the external sphincter, of the levator ani, impossibility of a R0 resection, or incontinence preceding the operative act. Unfortunately, the absence of the 4 conditions above is not enough to obtain a good result after ULAR. The mandatory condition to keep at least 5 cm from the anal canal should be added to indicate ULAR. Lowering the anastomosis to 4 cm or less from the anal opening creates the premises of

immediate and late morbidity which are hard to neglect. (35,36,37) Anastomoses in the sphincteric area are subject to chance, adding unacceptable risks for both surgeon and especially for the patient. High endoanal pressure ensures continence and is the result of the joint activity of the internal sphincter, the external one, and of the puborectal bundle within the levator ani muscle. Complete or partial intersphincteric resections remove the upper sectors of the internal sphincter to the pectineal line or 1 cm below it (22). This technique is reserved for cancers located 4-5 cm from the anal orifice - continence remains the responsibility of the external sphincter, obviously with high rates of failure. In both cases there will be a decrease in the area of high endoanal pressure, on account of damage to the main component-the internal sphincter.

## Conclusion

In conclusion, we can draw some points of view urging to reflection:

- 1) ultra low resection of the rectum, down to 3-4 cm from the anal orifice, is accompanied by significant changes in the morpho-functional device responsible for anal continence and defecation;
- 2) surgeons' concern, as shown in the literature, are mainly directed towards postoperative genitourinary disorders, which however present modest incidence compared with the morbidity rate due to coloanal transit after ULAR;
- 3) ULAR presents a high rate of anastomotic disunity, stenosis and various degrees of incontinence, all these complications together totalling about 55% percent. Solving these debilitating morbidities quite frequently ends in amputation of the anal-sphincteric complex and permanent colostomy;
- 4) ULAR remains a highly demanding surgical intervention, with uncertain results even in centres with remarkable experience in this field. Postoperative sphincter complex function does not always present the qualities desired and expected by both surgeon and, especially, patient;
- 5) from a surgeon's point of view a 50% share of specific complications after a certain surgical procedure cannot be regarded as a success. Consequently, it cannot be regarded as recommended procedure either without restraint and without warnings mentioned in the informed consent forms;
- 6) the lower limit to which a rectum resection can descend without being accompanied by the entire array of complications inherent to ULAR would require to be reconsidered. Keeping the 5 cm of the anal canal (anatomical and physiological) would considerably reduce morbidity after ULAR.

## References

1. Kapitejin E, Van de Velde C.J.H., European trials with total mesorectal excision ; Sem.Surg.Oncol., 2000,19:350-357
2. Pricolo V.E., Potenti F.M., Modern management of rectal cancer ; Dig.Surg.,2001,18:1-20

3. Enker WE1, Thaler HT, Cranor ML, Polyak T. Total mesorectal excision in the operative treatment of carcinoma of the rectum. *J Am Coll Surg.* 1995 Oct;181(4):335-46.
4. Vironen Jaana, How to improve results in rectal cancer surgery; Academic dissertation, Helsinki University Printing House, Helsinki 2005
5. Bretagnol F, Rullier E., Laurent C, et al Comparison of functional results and quality of life between intersphincteric resection and conventional coloanal anastomosis for low rectal cancer; *Dis Colon Rectum*, 2004, 47:832-838
6. Turet E., Exeresse totale du mesorectum et conservation de l'innervation autonome a destine genitourinaire dans la chirurgie du cancer du rectum; *Encicl. Med. Chir., Fiche additive* 40-610, 2005
7. Dozois R.R., Pezim M.E., Gunderson L.L., Carcinoma of the rectum; *S.Chir N.Amer* 1986, 66,4:821-832
8. Daams F, luyer M., Lange J.F., Colorectal anastomotic leakage: aspects of prevention ,detection and treatment, *W.J. Gastroen.*, 2013, 19(5):2293-2297
9. Eichhoff G, Short and long term results of hand sewn coloanal anastomosis performed as a salvage procedure after rectal resection, *Internet J.Surgery*, 2008,18,1, <http://is.pub.com/ij/s/18/1/88/7>
10. Wallace W.D., White T.J., Lynca A.C., Heriot A.G., A century of abdomino perineal excision for rectal cancer; *Colorectal cancer*, 2012, 1(1): 25-35.
11. Tilney H.S., Herriot A.G., Purkayastna S et al, A national perspective on the decline of abdominoperineal resection for rectal cancer; *Ann Surg.*, 2008, 247(1):77-84
12. Arbman G., Nilsson E., Hallbook O et al, Local recurrence following mesorectal excision for rectal cancer; *Br.J.Surg.*, 1996,83:375-379
13. Gamagami R.A., Liagre A, Chiotasso P, et al., Coloanal anastomosis for distal third rectal cancer, *Dis. Colon Rectum*, 1992, 42:1272-1275
14. Ortiz H., Miguel M., Armendariz P, et al, Coloanal anastomosis. Are results better with a pouch? *Dis. Colon Rectum*, 1995, 38:375-377
15. Shafik A., A concept of the anatomy of the anal sphincter mechanism and physiology of defecation; *Dis. Colon rectum* ,1981,30: 970-980
16. Ger R., Surgical anatomy of the pelvis; *S.Chir. N. Amer*, 1988, 68,6:1201-1207
17. Siddarth P, Ravo B, Colorectal neovasculature and anal sphincter, *A.Chir. N. Amer.*, 1988, 68,6:1185-1201
18. Bartolo D.C.C., Roe A.M., Locke-Edmunds J.C. et al: Flap valve theory of anorectal continence; *Br .J.Surg*, 1986, 73:1012-1021
19. Parks A.G., Percy J.P., Resection and coloanal anastomosis for rectal carcinoma, *Br.J.Surg.*, 1982, 69: 301-304
20. Henry M.H., Thompson J.P., The anal sphincters, *Scand. J. Gastroent.*, 1984,19: 53-65
21. Cavaliere F, Pemberton J.H., Cosinelli M, et al, Coloanal anastomosis for rectal cancer. Longterm results at the Mayo and Cleveland Clinics ; *Dis.Colon Rectum*, 1995,38:807-812
22. Nishizawa Y, Saito N., Fujii S. Et al: Association between anal function and therapeutic effect after preoperative chemoradiotherapy followed by intersphincteric resection, *Dig. Surg.*, 2012, 29,5:439-446
23. Wolf B.G., Fleshman J.w., Beck D.E., Pemherstom J.H., Wexner S.D., *ASCRS Textbook of colon and rectal surgery*; Ed Springer 2007- Bleaday R., Garcia Aguilar J., Surgical treatment of rectal cancer; p: 413-136
24. Jorge J.M., Wexner S.D., Etiology and management of fecal incontinence; *Dis. Colon Rectum* 1993, 36: 77-97
25. Carlsen E., Schlichting E., Guldvog I et al, Effect of the introduction of TME for the treatment of rectal cancer; *Br. J. Surg.*, 1998, 85:526-529
26. Karanjia N.D., Corder A.P., Beam P., Heald R.J., Leakage from stapple low anastomosis after TME for carcinoma of the rectum; *Br.J.Surg.*, 1994, 81:1224-1226
27. Heald R.J., Husband E.M., Ryall R.D.H., The mesorectum in rectal cancer surgery; the clue to pelvic recurrence; *Br. J.Surg.*, 1982, 69: 613-615
28. Rullier E., Laurent C., Garrelon j.l. et al, Risk factors for anastomotic leakage after resection of rectal cancer; *Br.J. Surg.*, 1998, 85:355-358
29. Camillieri-Brennan J., Steele R.J., Objective assessment of morbidity and quality of life after surgery for low rectal cancer; *Colorectal Dis.*, 2002,4:61-66
30. Fl. Mandache, *Chirurgia rectului*; Ed. Med. Bucuresti, 1971
31. Braun J., Treutner K.H., Winkeltau G et al, Results of intersphincteric resection of the rectum with direct coloanal anastomosis for rectal carcinoma; *Amer. J. Surg.*, 1992, 163: 407-412
32. Schiessel R., Karner-Hanusch J., Herbst Fet al, Intersphincteric resection for low rectal tumours; *Br. J. Surg.*, 1994, 81:1376-1378
33. Havenga K, Enker W.E., Mc Dermott K. Et al, Male and female sexual nd urinary function after TME with autonomic nerve preservation for carcinoma of the rectum ; *J. Ann. Coll. Surg.*, 1996, 182:495-502
34. Scott N., Jackson P, Jaberit et al, Total mesorectal excision and local recurrence; *Br.J.Surg.*, 1995, 82:1031-1033
35. Dekker J.N., Liefers G.J., de Mol van Otterloo et al, Predicting the risk of anastomotic leakage int he left sided colorectal surgery using a colon leakage score ; *Surg.Res.*, 2011, 166: 27-34
36. Den Dulk M., Noter S.L., Hendriks E.R. et al, Improved diagnosis and treatment of anastomotic leakage after colorectal surgery; *Eur. J.Surg. Oncol.*, 2009,35:420-426
37. Grama F.A., Burcos S.T., Bordea A., Cristian D., Localization and preservation of the autonomic nerves in rectal cancer surgery; *Chirurgia* 2014, 109: 380-387