

Image Quiz for Surgeons

Chirurgia (2015) 110: 300-307
No. 3, May - June
Copyright© Celsius

Giant Esophageal GIST: Diagnostic and Therapeutic Challenge - Case Report

S. Constantinoiu¹, M. Gheorghe¹, L. Popa², C. Ciocea², C. Iosif³, R. Tiutiuca⁴, A. Iordache⁵, I. Cordoș⁵

¹General and Esophageal Surgery Department, Center of Excellence in Esophageal Surgery, "Sfânta Maria" Clinical Hospital "Carol Davila" University of Medicine and Pharmacy, Bucharest, Romania

²Anesthesiology and Intensive Care Department, "Sfânta Maria" Clinical Hospital, Bucharest, Romania

³Pathology Department, "Sfânta Maria" Clinical Hospital, Bucharest, Romania

⁴Surgery Department, Military Clinical Hospital Iasi, Romania

⁵Thoracic Surgery Department, "Marius Nasta" Pneumoftiziologie Institute, Bucharest, Romania

Rezumat

GIST esofagian gigant: o provocare diagnostică și terapeutică - prezentare de caz

GIST sunt tumori mezenchimale rare ale tractului digestiv (sub 1% din neoplaziile tubului digestiv). Dintre acestea mai puțin de 1% sunt întâlnite la nivel esofagian. Chirurgia reprezintă tratamentul principal al GIST și este dublată de tratamentul țintit cu inhibitori de tirozin-kinază de tipul imatinib mesilatului. Prezentăm cazul unei paciente de 51 de ani, internată pentru o masă tumorală mediastinală posterioară, voluminoasă după depistarea acesteia în urma investigațiilor pentru stare de fatigabilitate la eforturi mari. Examenul clinic a fost nespecific. Radiografia toracică și apoi CT toraco-abdominală au identificat o lărgire a mediastinului printr-o formațiune tumorală mediastinală posterioară ce a deviat mult spre stânga esofagul toracic, fără a provoca disfagie sau simptome respiratorii notabile. S-a decis intervenția chirurgicală prin toracotomie în spațiul V intercostal drept și s-a practicat excizia totală a

tumorii. Examenul histopatologic a confirmat suspiciunea preoperatorie de GIST esofagian. Prognosticul bolii este rezervat, riscul de recidivă fiind foarte înalt, ținând cont și de faptul că tumora a fost extrasă fragmentat. În prezent pacienta este sub tratament cu imatinib mesilat și a intrat în programul de urmărire clinico-imagistică, așa cum prevăd ghidurile clinice.

Cuvinte cheie: GIST esofagian gigant, chirurgie toracică, multidisciplinaritate, imatinib mesilat, monitorizare oncologică

Summary

GIST are rare mesenchymal tumors of the digestive tract (less than 1% of the digestive tract neoplasia). Of these, less than 1% are found in the esophagus. Surgery is the main treatment of GIST and is supported by targeted therapy with tyrosine kinase inhibitors like imatinib mesylate. We present the case of a female patient of 51 years, admitted in our clinic for a bulky tumor in the posterior mediastinum, diagnosed after investigations performed for fatigue for the great efforts. Clinical examination was unspecific. Chest X-ray and thoraco-abdominal CT identified a widening of the mediastinum through a posterior mediastinal tumor mass, determining a deviation to the left of the thoracic esophagus without causing notable dysphagia or respiratory symptoms. It was decided surgery by thoracotomy in V right intercostal space and total excision of the tumor was performed. Histopathology examination confirmed the preoperative suspicion of esophageal GIST.

Corresponding author: Mircea Gheorghe, MD, PhD
General and Esophageal Surgery Clinic
Center of Excellence in Esophageal Surgery
"Sfânta Maria" Hospital
"Carol Davila" University of Medicine and Pharmacy, Bucharest
B-dul Ion Mihalache 37-39, Sector 1,
Bucharest, Romania
E-mail: drgheorghemircea@yahoo.com

Prognosis is reserved, the risk of relapse is very high given the fact that the tumor was extracted fragmented. Currently the patient is under treatment with imatinib mesylate and entered into clinical and imaging follow-up program, according to clinical guidelines.

Key words: giant esophageal GIST, thoracic surgery, multi-disciplinary, imatinib mesylate, oncological follow-up

Introduction

GIST are rare mesenchymal tumors of the digestive tract, with an incidence of 1-3% of malignancies with this location. The most frequent location is the stomach (60-70%), followed by the small intestine (20-25%), rectum and colon (5%), and esophagus (about 1%). Typically occurs in patients aged 50-60 years (1). The size ranges from small tumors less than 1 cm, typically incidentally discovered during investigations of other diseases, up to large tumors of 35 cm (mean diameter 5 cm), with various and non-specific symptomatology. (2) Regardless of size, GIST have in common histological and immunohistochemical characteristics: positive tyrosine-kinase receptor (KIT, CD117) and containing a single mutation in the KIT gene (80-85%) or platelet derived growth factor alpha PDGFRA gene (5-7%). (3) Although the majority of GIST occur by KIT or PDGFRA activating mutations, a small subset is associated with other mutations - wild type, their production mechanism involving other intracellular signaling pathways. (4) Surgery is the main treatment, complemented by targeted therapy with tyrosine-kinase inhibitors like imatinib mesylate, in adjuvant or neoadjuvant therapy, when biopsy specimen is accessible. (5)

We will present a rare case of giant esophageal GIST, significant due to clinical and laboratory investigations, to perioperative anesthetic-surgical issues and to the surgical treatment. The histopathological and immunohistochemical tests that indicated the diagnosis, and complementary treatment and follow-up program initiated for this patient is also presented.

Case report

Female patient G.E., 51 years old, with BMI = 19.1, was admitted for asthenia, increased after moderate-great physical effort. Physical examination, biochemical and hematological analysis were within normal range. Cardio-pulmonary radiology: highlights a widening of the mediastinal shadow, by an opacity of subcostal intensity occupying the entire posterior mediastinum, heart shadow and tracheo-bronchial tree pushed to anterior, suggestive for a tumoral process in the posterior mediastinum. (Fig. 1) Abdominal ultrasound: no visible pathological changes. Barium swallow: shows an impression and deviation to the left side of the esophagus without mucosal

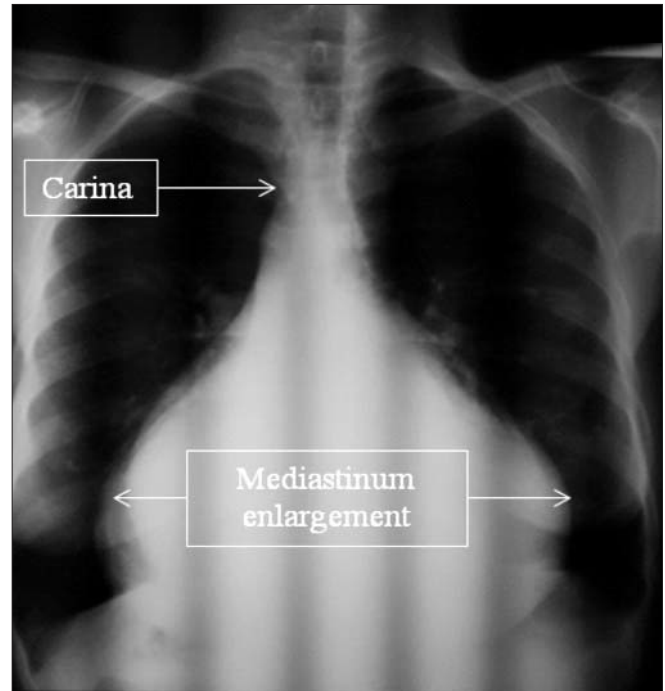


Figure 1. Thoracic X-ray – enlargement of mediastinal shadow

changes; indentation in the upper stomach, gastric body, D1, DII without changes. (Fig. 2) Thorax and upper abdominal CT scan: highlights a tumor of 20/30 cm, located in the posterior mediastinum with heterogeneous structure, extended cranial

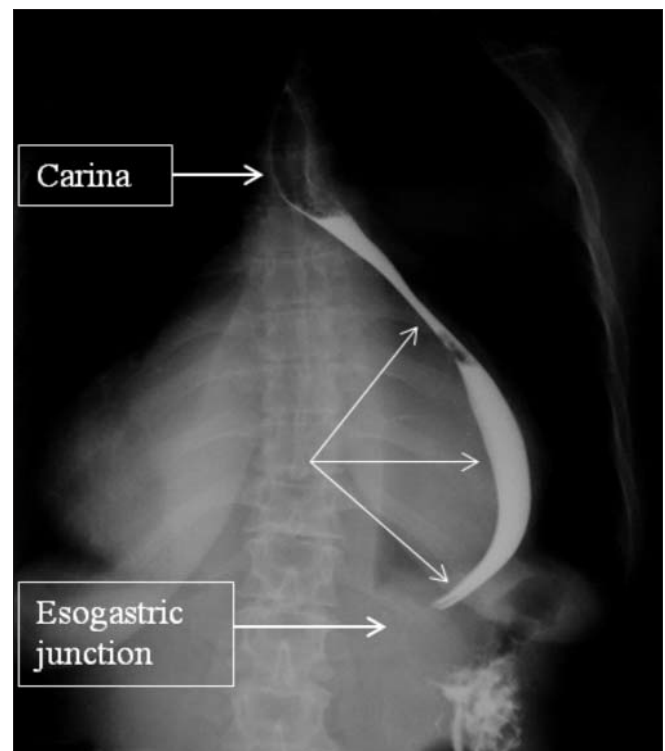


Figure 2. Barium swallow - impression and deviation to the left side of the esophagus without mucosal changes; indentation in the esogastric junction

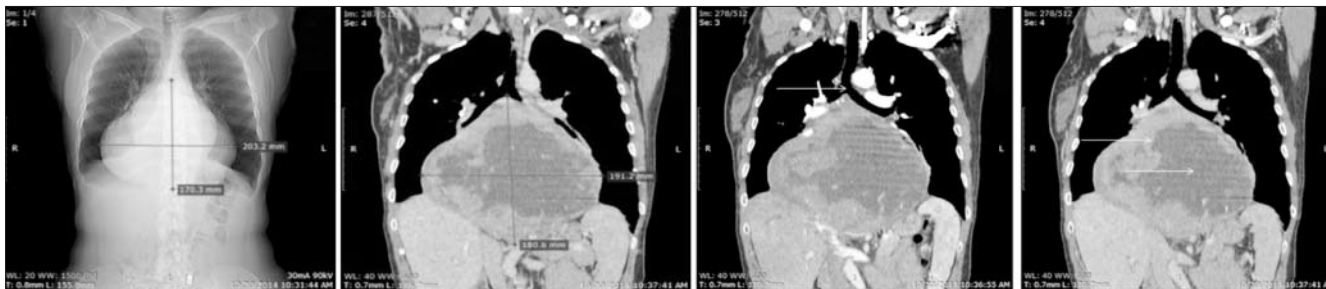


Figure 3. Tumor of 20/30 cm, heterogenous structure, extend upwards from tracheal bifurcation, downwardsto celiac trunk

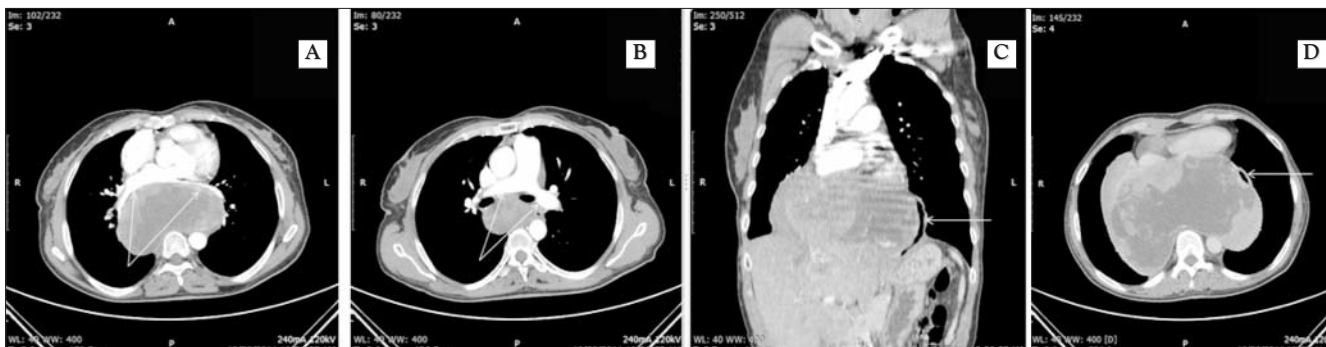


Figure 4. Tumor of posterior mediastinum, indentation of the pulmonary vessels and heart (A, B), lateral deviation of the esophagus (C,D)

from the tracheal bifurcation and caudal to the celiac trunk, with indentation of the pulmonary vessels and heart. No liver, splenic, pleural, peritoneal metastases or thoracic and abdominal lymphadenopathy are identified. (Fig. 3-5) Upper endoscopy: indented esophagus, but with normal esophageal distension after insufflation, without mucosal changes, stomach, DI, DII with normal endoscopic appearance. Bronchoscopic examination: trachea without particularities, significant primitive stenosis in the right bronchus. Spirometry: moderate restrictive dysfunction. Echocardiography: extrinsic compression of both atria, predominantly in the right atrium and inferior posterior wall of the left ventricle, pulmonary artery - no signs of compression, free pericardium.

Thus we found the presence of a bulky tumor in the

posterior mediastinum, from the trachea bifurcation to the the celiac (Luschka) region, with deviation/significant compression of the heart and great intrathoracic vessels, with a heterogeneous solid/fluid structure, which requires a surgical approach, with difficult tumor extraction. We formed a multidisciplinary team composed of general and thoracic surgeons, anesthesiologists, pathologists, radiologists and oncologists.

Anesthesia was marked by the existence of a high risk of potentially fatal accidents such as complete obstruction of the airways, cardiovascular collapse – these complications can occur in transition to the supine position, during induction of the general anesthesia, during the manipulation and extraction of the tumor, and at extubation. In literature, the

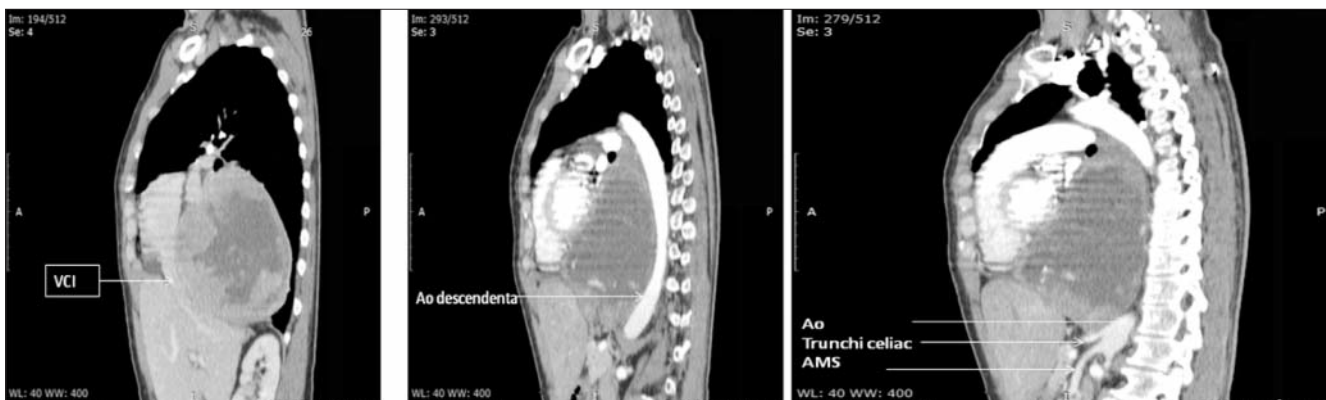


Figure 5. Tumor of posterior mediastinum with compression on heart and inferior vena cava (IVC) – left, and celiac trunk - right

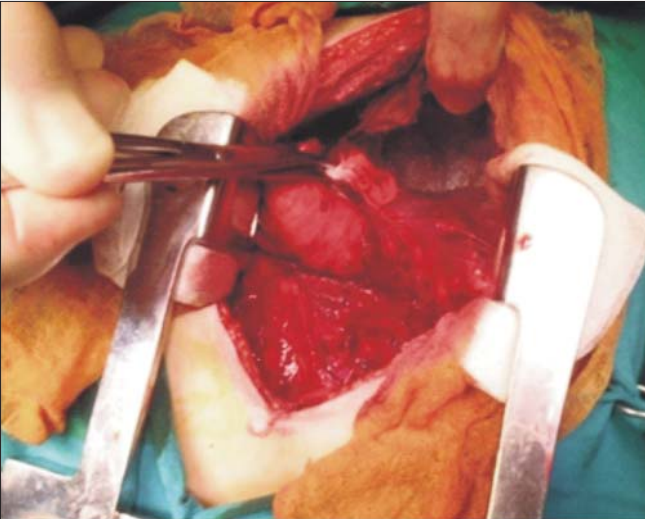


Figure 6. Intraoperative aspect—tumor occupying almost all the right hemitorax, after pulmonary collapse

incidence of these complications in the perioperative period is between 7-20%. (6)

During surgery, the team assured a jugular and femoral central venous catheter; invasive blood pressure monitoring, BIS monitoring (monitoring brain activity during anesthesia), selective left bronchus intubation, positive pressure ventilation test, muscle relaxant along with thoracotomy. Intraoperative, the mechanical one lung ventilation was difficult, with a hemodynamic instability corrected after administration of vasopressor; intraoperative bleeding was about 2.5 liters, compensated with crystalloid solutions and blood transfusion.

Surgery was performed by right thoracotomy in V intercostal space; we found an intense adherential process of the pleura and lung that needed and careful dissection and, after collapse of the right lung, it is highlighted a voluminous encapsulated tumor, which compresses the heart and lungs to anterior, in close proximity with the right lower lung lobe and pulmonary veins that are dissected with relative difficulty. (Fig. 6) Upwards tumor extends to the carina that is deviated and downwards tumor extends through the esophageal hiatus into the upper abdomen. Dissection is hampered by the large tumoral volume and it requires the fragmented extraction of the

tumor.

Macroscopic appearance is an encapsulated tumor, of a heterogeneous consistency, with alternating areas of necrosis and fibrous structure, with dimensions of about 30/20 cm. It was needed to suture right pulmonary vein with 6.0 Prolene thread. An injury in the right lower lung lobe is sutured with 4.0 Prolene thread. There were identified esophageal wall muscle and adventiceal injuries, without injury to the esophageal mucosa after blue methylene test inserted through the esophageal tube. Drainage of the thoracic cavity with two polythene multiperforated tubes standard positioned to apex and right costo-phrenic sinus and connected to a Béclair system.

Pathological frozen sections examination: ancient schwannoma/ GIST. Paraffin microscopic examination: spindle cell proliferation with palisadic disposition, crossed with large areas of necrosis; relatively frequent atypical mitosis; rare hemangiopericytoma like vessels. Histological appearance is suggestive for different diagnosis: hemangiopericytoma, solitary fibrous tumor, stromal tumor. Densely cellular areas, mitotic activity > 4 / 10HPF and large areas of necrosis are arguments for malignancy of the lesion. (Fig. 7) Immunohistochemical staining: focal positive reaction for CD117 and diffuse positive reaction for DOG1 in tumoral cells, negative reaction for Actine, negative reaction for CD34 in tumoral cells. (Fig. 8) The histopathological aspect and immunohistochemical staining correlated with anatomical, clinical and imaging aspects are compatible with the diagnosis of GIST, with high risk of recurrence.

Patient was discharged in tenth postoperative day after performing a contrast radiological exam to prove the lack of fistula (at day 6) (Fig. 9) and progressive oral food intake.

In the first postoperative month a barium radiological exam was performed (thoracic esophagus in normal anatomical position) (Fig. 10, 11) There were no signs of local recurrence or metastasis at CT scans made at fifth postoperative months. (Fig. 12, 13)

The prognosis of the disease is poor considering risk factors: mitotic index, tumor volume, localisation. The risk is estimated at 71%. The fragmented tumor excision, it is also considered as supplementary risk factor which place the case in the highest risk of recurrence

The patient was included in the national program for

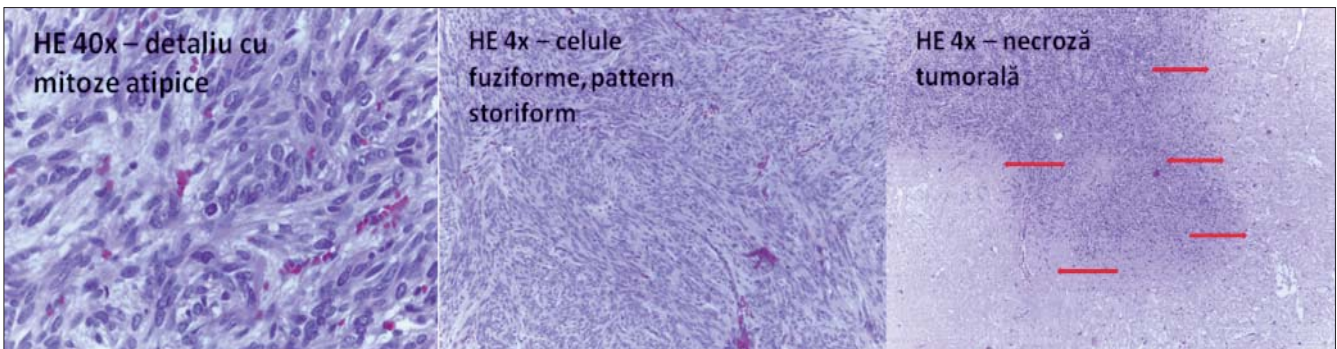


Figure 7. HE staining: atypical mitosis (left), spindle cell morphology (middle), tumor necrosis (right)

Figure 8. *Imunohistochemistry - CD117+/DOG1+, confirmation of GIST*

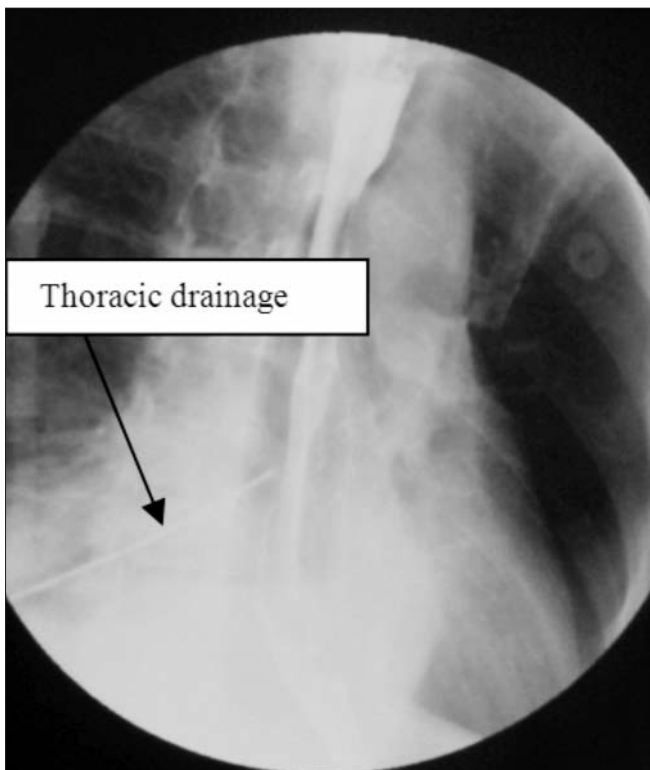
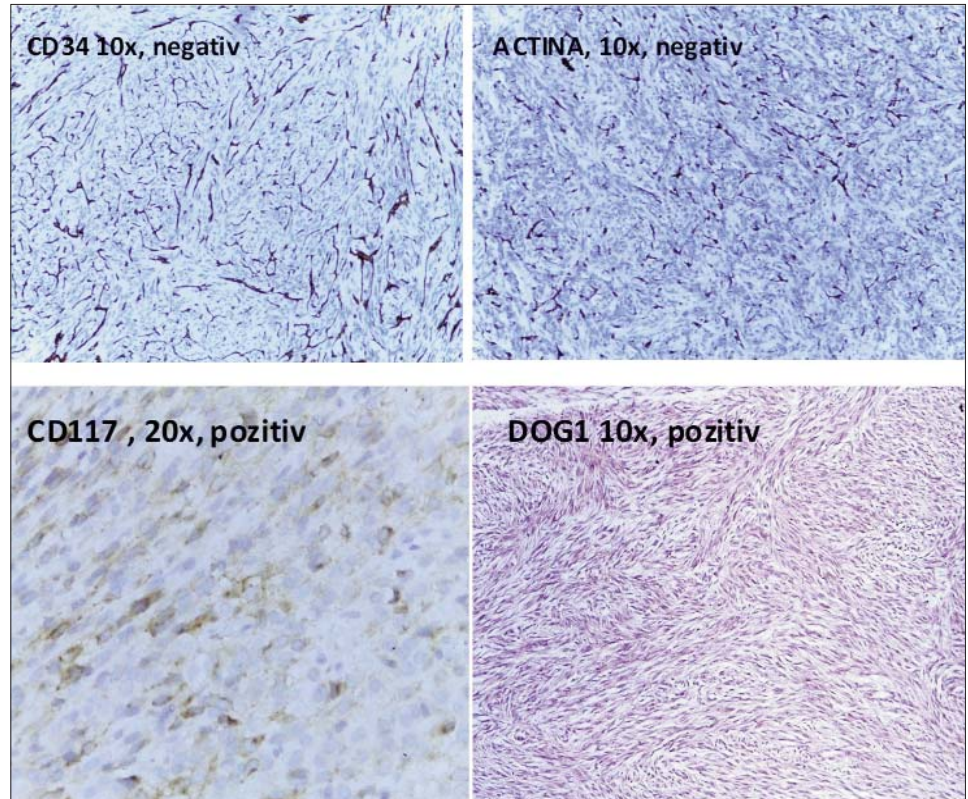


Figure 9. *Radiological contrast control at sixth postoperative day – no esophageal fistula, thoracic drainage tube*

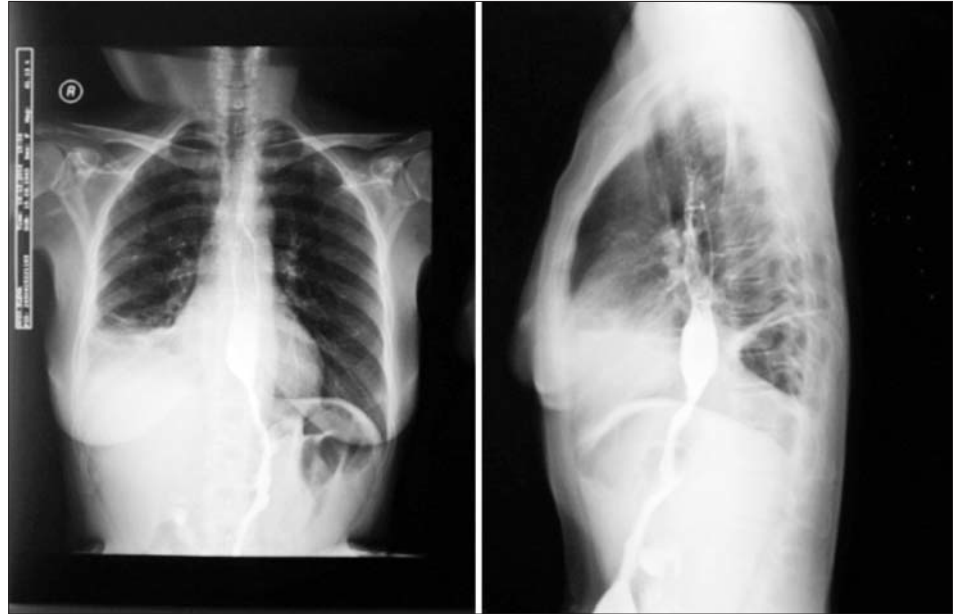
administration of imatinibmesylate, 400 mg/day, and will carry out regular CT scans at 3 months in first year, at 6 month for three years, and annually for the next 5 years. Clinical and imagery follow-up (including also PET CT scan) is very important especially in the first month from the beginning of treatment.

The appearance of local recurrence or distant metastases means imatinibmesylate resistance and treatment will be modulated according to clinical guidelines. Genetic tests are necessary and we are supporters of systematic mutational analysis in each case. It can identify the genetic profile that might offer any resistance to imatinibmesylate and orientation to the second line treatment with sunitinib maleate.

Discussion

From existing epidemiological data we face a rare tumor, esophageal location is extremely rare, about 0.01-0.03% of the digestive tract malignancies. (7,8) GIST tumor biology allows the development to giant sizes without altering the general condition, which is a clinical characteristic of these tumors. Heterogeneous appearance with solid and necrotic areas, encapsulated tumors that also compress the surrounding digestive organs are radiological characteristics which guide the clinician to the suspicion of GIST. The development from interstitial cells of Cajal does not involve the digestive mucosa and often endoscopic mucosal biopsy is negative. Lack of lymphatic dissemination of GIST is another characteristic that can be detected by imaging as absence of lymph nodes. On one

Figure 10. Barium swallow control at first postoperative month – esophagus in normal position



hand it makes unnecessary local and regional lymphodissection and on the other hand allows resections with organ preservation. The clinical and imaging data may allow the suspicion of GIST and adjustment of diagnostic algorithm according to current guidelines. Being in front of a sarcoma biopsy is to be avoided, although Trucut biopsy is acceptable regarding dissemination risk in the opinion of many authors. This would allow a biopsy specimen necessary to start targeted neoadjuvant-treatment with tumor downstaging and organ spare resections with function preservation. Surgery is the only curative treatment far available in this type of neoplasia. (5) Surgery of this type of tumor is delicate, performed in the extracapsular plan, in order to obtain R0 resection, avoiding trauma of tumor capsule which would place the tumor in the metastatic setting. (10) This goal can be achieved especially for tumors up to 10 cm diameter, while for larger sizes the esophagectomy seems to be the correct oncological intervention. (11) After obtaining the biopsy specimen diagnosis is confirmed by IHC staining using a panel of monoclonal antibodies Characteristics are (CD117 and DOG1). Stratification of tumor aggressiveness using the scale AFIP (Armed Force Institute of Pathology) is most often used by large volume centers, taking into account different malignant behavior of GIST, relying on a number of parameters such as tumor size, number of mitosis, tumor site, adding tumor capsule rupture, multiorgan involvement or incomplete resection. (12) Mutational analysis come to finalize the diagnosis, stating mutant gene which gives a better targeted treatment, tumors with exon 9 mutated KIT gene being recognized as more aggressive than the exon 11 ones and known that some GISTs are resistant to standard treatment with tyrosine-kinase inhibitors. (13) Comparing mutational analysis costs with two or three months of ineffective treatment with tyrosine-kinase inhibitors, it is justified the use of this genetic methods for the benefit of the patient and the healthcare

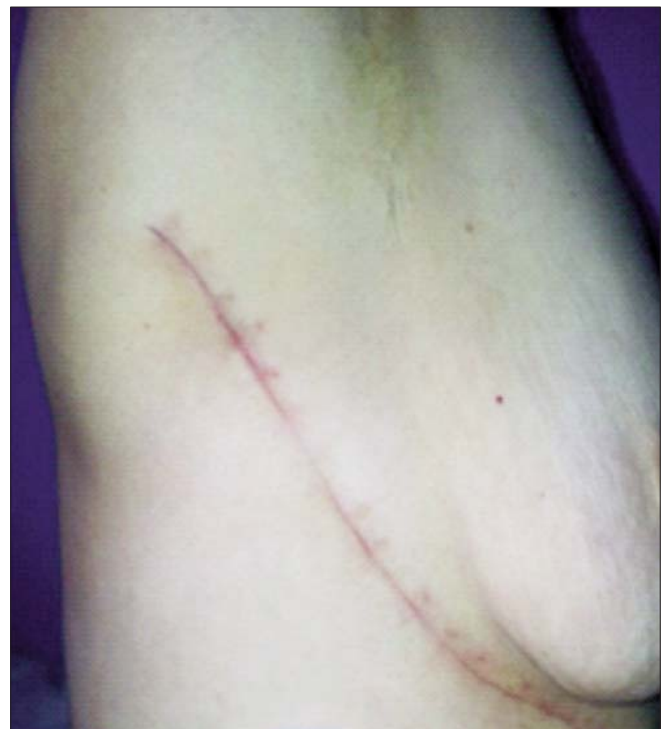

Figure 11. Clinical aspect at first postoperative month

system. It is absolutely necessary to address each case to a multidisciplinary team that includes different specialties working with this type of pathology. (14) This can ensure correct diagnosis and therapy of these patients, according to actual clinical guidelines, applying effective and specific treatment and consistent reporting of each case, thus providing a picture of the true incidence of GIST in Romania.

Figure 12. CT scan: preoperative (left) vs 5 months postoperative (right) – coronal aspect

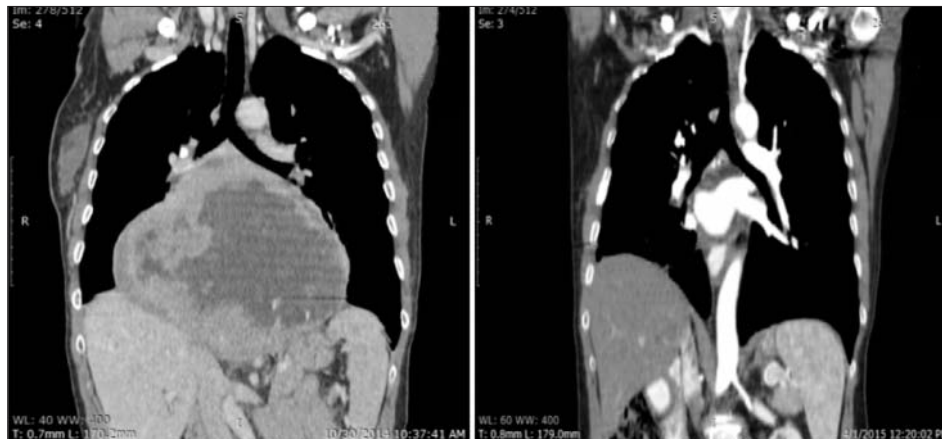
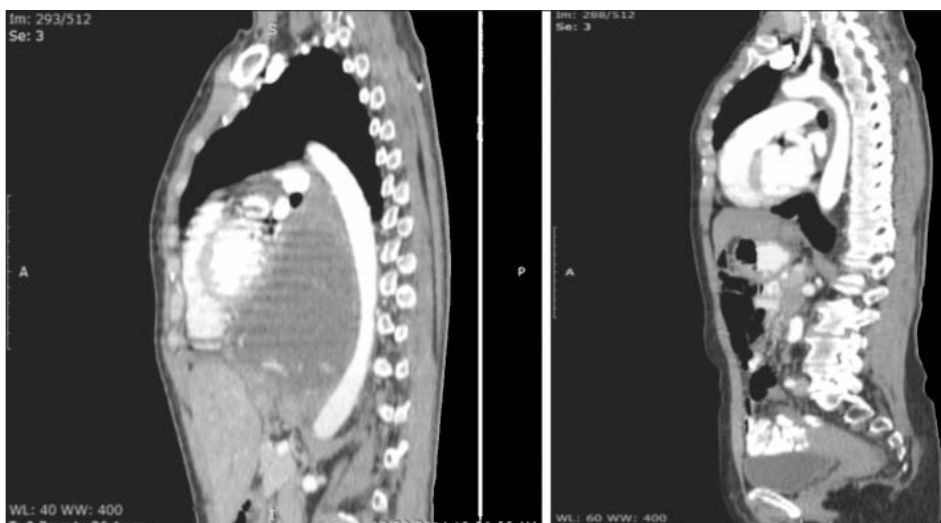


Figure 13. CT scan: preoperative (left) vs 5 postoperative months (right) – sagittal aspect



Conclusion

We presented in this article the issue of diagnosis and surgical treatment of a giant esophageal GIST with the difficulties caused by its intra thoracic localization. We insist that such a case should be treated in a multidisciplinary team assessing the immediate anaesthetical and surgical risk and also the risk of recurrence by pathological and genetic complete evaluation, in conjunction with adjuvant or even neoadjuvant specific therapy.

References

- Miettinen M, Lasota J. Gastrointestinal stromal tumors: pathology and prognosis at different sites. *SeminDiagnPathol*2006; 23: 70-83 (PMID: 17193820 DOI: 10.1053/j.semdp.2006.09.001)
- Demetri GD, Benjamin RS, Blanke CD, Blay JY, Casali P, Choi H, et al. NCCN Task Force report: management of patients with gastrointestinal stromal tumor (GIST)—update of the NCCN clinical practice guidelines. *J NatlComprCancNetw*. 2007;5 Suppl 2:S1-29. 182.
- Heinrich MC, Corless CL, Demetri GD, Blanke CD, von Mehren M, Joensuu H, et al. Kinase mutations and imatinib response in patients with metastatic gastrointestinal stromal tumor. *J ClinOncol*. 2003;21:4342-9.
- Miettinen M, Wang ZF, Sarlomo-Rikala M, Osuch C, Rutkowski P, Lasota J. Succinate dehydrogenase-deficient GISTs: a clinicopathologic, immunohistochemical, and molecular genetic study of 66 gastric GISTs with predilection to young age. *Am J SurgPathol*. 2011; 35:1712-21.
- The ESMO / European Sarcoma Network Working Group. Gastrointestinal stromal tumors: ESMO Clinical Practice Guidelines for diagnosis, treatment and follow-up. *Annals of Oncology* 23 (Supplement 7): vii49–vii55, 2012 doi:10.1093/annonc/mds252.
- Bécharde P, et al: Perioperative cardiorespiratory complications in adults with mediastinal mass: incidence and risk factors. *Anesthesiology* 2004; 100: 826-34
- Simon Lott, Michael Schmieder, Benjamin Mayer, Doris Henne-Bruns, UweKnippschild, Abbas Agaimy, Matthias Schwab, Klaus Kramer - Gastrointestinal stromal tumors of the esophagus: evaluation of a pooled case series regarding clinicopathological features and clinical outcome - *Am J Cancer Res* 2015;5(1):333-343
- Predescu D, Gheorghe M, Predoiu I, Iosif C, Constantin A, Chiru F, Cociu L, Constantinoiu S – Gastrointestinal stromal tumor (GIST) – medical rarities?.- *Chirurgia (Bucur)*. 2010 Jul-Aug;105(4):577-85. Romanian

9. Gheorghe M, Predescu D, Iosif C, Ardeleanu C, Băcanu F, Constantinoiu S - Clinical and therapeutic considerations of GIST *Journal of Medicine and Life* Vol. 7, Issue 2, April-June 2014, 139-149
10. Rutkowski P, Nowecki ZI, Michej W, Debiec-Rychter M, Wozniak A, Limon J, Siedlecki J, Grzesiakowska U, Kakol M, Osuch C, Polkowski M, Gluszek S, Zurawski Z, Ruka W: Risk criteria and prognostic factors for predicting recurrences after resection of primary gastrointestinal stromal tumor. *Ann Surg Oncol* 2007, 14:2018–2027.
11. Jiang P, Jiao Z, Han B, Zhang X, Sun X, Su J, Wang C and Gao B. Clinical characteristics and surgical treatment of oesophagealgastrointes- Esophageal GIST 343 *Am J Cancer Res* 2015;5(1):333-343 tinal stromal tumours. *Eur J CardiothoracSurg* 2010; 38: 223-227.
12. Joensuu H, Vehtari A, Riihimäki J, Nishida T, Steigen SE, Brabc P, Plank L, Nilsson B, Cirilli C, Bordoni A, Magnusson MK, Linke Z, Suflarsky J, Federico M, Jonasson JG, Dei Tos AP, Rutkowski P: Risk of recurrence of gastrointestinal stromal tumour after surgery: an analysis of pooled population-based cohorts. *Lancet Oncol* 2012, 13:265–274.
13. Christopher L. Corless et al. Pathologic and Molecular Features Correlate With Long-Term Outcome After Adjuvant Therapy of Resected Primary GI Stromal Tumor: The ACOSOG Z9001 Trial, doi: 10.1200/JCO.2013.53.5971
14. Badulescu A., Badulescu F, Cosntantinoiu S., Popescu C., Schenker M. – Gastrointestinal stromal tumors (GIST) – a new diagnostic and therapeutic paradigm. – *Chirurgia (Bucur)* 2006 Jan-Feb; 101 (1):87-89. Romanian