

## Stump Appendicitis: A Clinical Enigma\*

F. Çiftci<sup>1</sup>, I. Abdurrahman<sup>2</sup>, Z. Tatar<sup>3</sup>

<sup>1</sup>Vocational School of Health Services, Istanbul Gelişim University, Avcılar, Istanbul, Turkey

<sup>2</sup>Department of Internal Medicine, Safa Hospital, Istanbul, Turkey

<sup>3</sup>Istanbul Pathomer Pathology Centre, Istanbul, Turkey

### Rezumat

#### *Appendicita de bont: o enigmă clinică*

Apendicectomia este una dintre operațiile efectuate cel mai frecvent. Apendicita de bont, complicație postoperatorie a apendicectomiei, reprezintă inflamația țesutului restant atunci când are loc o rezecție incompletă. Vă prezentăm cazul unui pacient cu apendicită de bont, asupra căruia s-a intervenit laparoscopic în urmă cu 6 luni, pentru tratamentul chirurgical al apendicitei acute. Pacientul a fost diagnosticat cu apendicită, a fost supus intervenției chirurgicale și externat în a 3-a zi postoperatorie fără complicații. Apendicita de bont este o cauză rară de patologie abdominală acută, dar trebuie inclusă în diagnosticul diferențial. Ecografia abdominală este un instrument util în diagnosticarea acesteia.

**Cuvinte cheie:** apendicită de bont, diagnostic, tratament

### Abstract

Appendectomy is one of the most frequently performed operations. Stump appendicitis, as a postoperative complication of appendectomy, is inflammation of the remnant

residue when an incomplete excision occurs. We present a patient with stump appendicitis who had been operated on, laparoscopically, for acute appendicitis 6 months before. The patient was diagnosed with acute appendicitis, underwent surgery, and was discharged on postoperative day 3 without complications. Stump appendicitis is a rare cause of acute abdominal disease but should be considered in the differential diagnosis. Ultrasonography is helpful in the diagnosis.

**Key words:** stump appendicitis, diagnosis, treatment

### Introduction

Inflammation of the remnant stump leads to acute abdominal manifestations when the appendix vermiformis is not completely excised during an appendectomy and is called stump appendicitis. Stump appendicitis manifests all of the clinical findings of acute appendicitis and presents as acute abdominal disease. A history of appendectomy may delay diagnosis and increase morbidity. Acute appendicitis is one of the most frequent surgeries for an acute abdomen. The incidence of acute appendicitis in the general population is about 7% (1). Complications encountered after appendectomy include wound-site infection, postoperative ileus, intra-abdominal abscess, and leaks from the remnant stump.

Stump appendicitis is a very rare complication (2). We present a case of stump appendicitis in a 17-year-old male, who presented to our hospital with the complaint of right lower quadrant pain and a history of laparoscopic appendectomy.

---

*Corresponding author:* Fatih Çiftci, MD  
Basak mah. 2.etap D-35/24 34306  
Basaksehir/Istanbul-Turkey  
E-mail: oprdrfatihciftci@gmail.com

\* This study was presented as an electronic mail at the 19<sup>th</sup> National Surgery Congress of Turkey held on April 16–20, 2014.

## Case report

A 17-year-old old male presented to the emergency unit complaining of anorexia, nausea, vomiting, and abdominal pain originating from around the navel that later moved to the right lower quadrant. He had undergone laparoscopic appendectomy 6 months before but had no other history. A physical examination revealed axillary body temperature of 37.3°C, blood pressure of 120/80 mmHg, pulse rate of 80/minute, and a rhythmic breathing rate of 21/min. Small incision scars were found on the abdominal wall, and bowel movements were hypoactive on auscultation. Defense and rebound tenderness were detected in both lower quadrants; however, these signs were more prominent in the right lower quadrant. A laboratory examination revealed leucocytosis of 16,500/mm<sup>3</sup> and a left shift in the leukocyte formula. Antero-posterior chest and direct abdominal X-rays were normal. Abdominal ultrasonography showed an uncompressed and nonperistaltic 8 x 6 mm intestinal mass that had a blind end in the right lower quadrant, indicating acute appendicitis.

A laparotomy was performed through a median incision below the umbilicus and disclosed an abscess pouch surrounded by the cecum and small intestine. Adhesions were dissected, a 3 cm diameter edematous appendicular stump was resected to the appendix radix, and a drainage system was placed (Fig. 1).

An elastic drain was placed in the right paracolic space, and the operation was complete. The drain was removed on postoperative day 2, and the patient was discharged on postoperative day 3. The histopathological evaluation of the perioperative material indicated suppurative stump appendicitis. Active intense inflammation with predominant neutrophilic leukocytes had infiltrated the tissues surrounding the appendix and destroyed all layers of the appendix wall (Fig. 2).

## Discussion

Complete surgical removal of an inflamed appendix is the treatment for stump appendicitis. This intervention may be open or laparoscopic (3). Complications including wound site infection and cecocutaneous fistula may develop postoperatively. Stump appendicitis is a very rare complication of subtotal appendectomy (2). Cecal diverticulitis is the differential diagnosis for stump appendicitis and should be considered due to its location. Cecal diverticulitis occurs more frequently in patients who are 30–50-years-of-age, and the associated symptoms are localized to the right lower quadrant. In contrast, our patient was 17-years-old, and symptoms involved bilateral lower quadrants, although the symptoms affected the right side more than the left. Moreover, the ultrasonographic findings revealed an aperistaltic segment confirming acute appendicitis. These findings helped us to distinguish this case from cecal diverticulitis.

Stump appendicitis can develop as early as 2 months after the first operation. However, development of the disease 50 years after the operation has been reported (4,5). Our patient developed stump appendicitis 6 months later. This disease is a

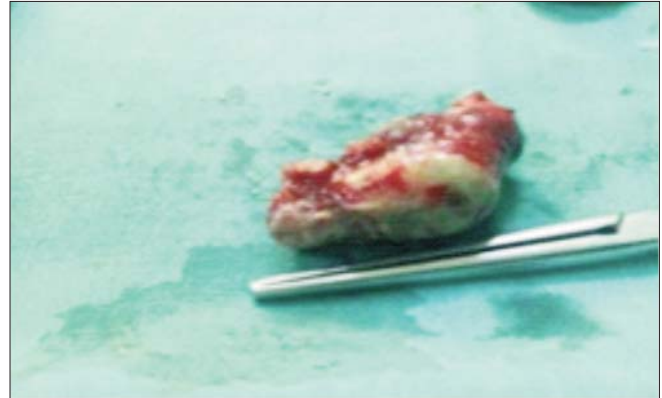


Figure 1. Stump appendicitis

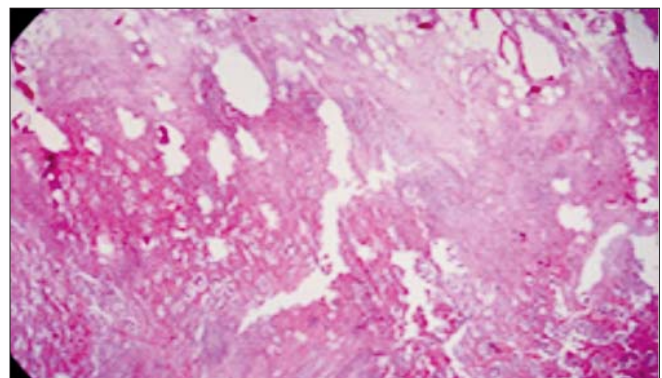


Figure 2. Pathological view of stump appendicitis

rare cause of acute abdominal disorder; however, incidence has increased slightly due the increased use of a laparoscopic approach for appendectomy. The stump left behind during laparoscopic appendectomy is relatively long (2). Indeed, the remnant stump should not be > 5 mm or it may serve as a fecalith pouch. Stump appendicitis may be inevitable if fecalith obstructs the intestinal lumen (6).

Imaging techniques play a very significant role in the diagnosis of stump appendicitis in patients with a history of appendectomy, and ultrasonography and computed tomography are frequently employed for this purpose. Some studies have reported that barium colonography and colonoscopy are useful for the diagnosis(3). The various methods for treating stump appendicitis involve reappendectomy with or without inverting the stump or a restricting right hemicolectomy. The resected stump varies in length (1.3– 5.1 cm) in most cases of stump appendectomy (7-11). Our case had a stump length of 3 cm. Antibiotic treatment may need to be prolonged due to intra-abdominal contamination. We found no intra-abdominal contamination in our patient.

## Conclusion

Stump appendicitis is a delayed and rare complication of appendectomy and manifests as an acute abdomen. A history of appendectomy may decrease suspicion. Patients

presenting with a history of appendectomy, complaints of right lower quadrant pain, and signs of peritonitis in bilateral lower quadrants should be suspected for stump peritonitis along with other differential diagnoses.

**Conflict of interest:** None declared

**Source and support:** None

**Authors contributions**

FC: general surgeon. IA: emergency specialist. ZT: pathologist. All authors have read and approved the final manuscript.

**References**

1. Subramanian A, Liang MK, "A 60-year literature review of stump appendicitis: The need for a critical view," *The American Journal of Surgery*, 2012; 203(4): 503-507
2. Menten O, Zeybek N, Oysul A, et al. Stump appendicitis, rare complication after appendectomy: report of a case. *Turkish J Trauma & Emergency Surgery* 2008; 14: 330-332.
3. O'Leary DP, Myers E, Coyle J, et al. Case report of recurrent acute appendicitis in a residual tip. *Cases J.* 2010; 9: 14. doi.org/10.1186/1757-1626-3-14
4. Mangi AA, Berger DL. Stump appendicitis. *Am Surg* 2000; 66: 739-741.
5. Baldisserotto M, Cavazzola S, Cavazzola LT, et al. Acute edematous stump appendicitis diagnosed preoperatively on sonography. *AJR* 2000; 175: 503-504.
6. Durgun AV, Baca B, Ersoy Y, Kapan M. Stump appendicitis and generalized peritonitis due to incomplete appendectomy. *Tech Coloproctol* 2003; 7: 102-104. doi.org/10.1007/s10151-003-0018-4
7. Cama JK, "Recurrent abdominal pain post appendectomy: a rare case," *Pacific Health Dialog*, 2010;16(2):78-81
8. Constantin V, Popa F, Carap A, Socea B. Stump appendicitis-an overlooked clinical entity. *Chirurgia (Bucur)* 2014; 109(1): 128-31
9. Puylaert JB, Rutgers PH, Lalisang RI, de Vries BC, van der Werf SD, Dörr JP, et al. A prospective study of ultra-sonography in the diagnosis of appendicitis. *N Engl J Med* 1987; 317: 666-9.
10. Belli S, Yalcinkaya C, Ezer A, Bolat F, Colakoglu T, and Simsek E, "Stump appendicitis and chorioamnionitis due to incomplete appendectomy: a case report," *Turkish Journal of Gastroenterology*, 2011; 22(5): 540-543
11. Werbin N, "Unfinished surgery," *Harefuah*, 2005; 144(12): 894-908.