

## Ileocecal Obstruction Due to B-cell Non-Hodgkin Lymphoma

Vasile Negrean<sup>1,2</sup>, Florin Graur<sup>1,3</sup>, Emil Mois<sup>1,3</sup>, Nadim Al-Hajjar<sup>1,3</sup>

<sup>1</sup>Iuliu Hatieganu University of Medicine and Pharmacy, Cluj-Napoca, Romania

<sup>2</sup>Universitary Hospital CF, Cluj-Napoca, Romania

<sup>3</sup>Prof. O. Fodor Regional Institute of Gastroenterology and Hepatology, Surgery Department, Cluj-Napoca, Romania

### Rezumat

#### ***Ocluzie ileo-cecală secundară unui limfom non-Hodgkin cu celule B***

Prezentăm un caz rar de limfom non-Hodgkin care se manifestă ca o masă tumorală ileocecală. Pacient bărbat de 77 de ani se prezintă cu simptome de obstrucție intestinală parțială, durere în fosa iliacă intermitentă, pierdere în greutate, vărsături și oboseală. La inspecția clinică se pune în evidență sensibilitate abdominală moderată, cu o masă palpabilă în fosa iliacă dreaptă. Colonoscopia relevă o invaginație ileo-cecală cu stenoză la acest nivel. Pe parcursul internării pacientul dezvoltă ocluzie intestinală motiv pentru care se decide intervenția chirurgicală de urgență. Intraoperator se decelează o masă ileocecală de 10-12 cm în diametru, cu stenoză completă la acest nivel și dilatarea în amonte a intestinului subțire. Peritoneul parietal și ficatul prezintă multipli noduli cu aspect de carcinomatoză peritoneală. O ileotransverso-anastomoză a fost realizată cu biopsii de la nivelul nodulilor. Evaluarea histopatologică a relevat un limfom non-Hodgkin difuz cu celule B mari localizat ileocecal și pe peritoneul parietal.

**Cuvinte cheie:** limfom non-Hodgkin, ileocecal, ocluzie intestinală

### Abstract

We report a rare case of non-Hodgkin lymphoma presented as an ileocecal mass. The patient was a 77-year-old man with history of symptoms of partial bowel obstruction, intermittent right iliac fossa pain, loss of weight, vomiting and fatigue. Clinical signs included moderate abdominal tenderness with a palpable mass in the right iliac fossa at the physical examination. Colonoscopy revealed an intussusception of the right colon causing a complete stenosis. The patient developed complete bowel obstruction during hospitalization that required emergent surgical intervention. Intraoperatively an ileocecal mass was found measuring 10-12 cm in diameter, causing complete stenosis at its level and bowel dilatation proximally. Multiple nodules were found in the liver and the parietal peritoneum as well. An ileotransverso-anastomosis was performed and biopsies of the nodules were taken. Pathological evaluation revealed a diffuse large B cell non-Hodgkin's lymphoma of the ileocecum and the parietal peritoneum.

**Key words:** non-Hodgkin lymphoma, ileocecum, bowel obstruction

---

Corresponding author:

Florin Graur, MD  
Prof. O. Fodor Regional Institute of  
Gastroenterology and Hepatology  
Str. Croitorilor 19-21, Cluj-Napoca, Romania  
E-mail: graurf@yahoo.com

### Background

The latest classification of lymphomas, which was established by the WHO in 2008, had abandoned the terms "Hodgkin" and "non-Hodgkin" using more than 80 different forms of lymphoma in 4 broad groups (1). Despite that the terms "Hodgkin" and "non-Hodgkin" are still used in daily practice.

Primary gastrointestinal lymphoma is very rare, constituting

only about 1-4% of all gastrointestinal malignancies (2). The gastrointestinal (GI) tract is the most common extranodal site of involvement in non-Hodgkin lymphoma (NHL)(3). The stomach is the predominant location for GI lymphomas (50%), whereas intestinal lymphomas are less frequently observed in the small bowel (20-30%)(4, 5). The small intestine is less commonly involved with lymphomas than the large intestine. The ileum is the most common site of small intestinal lymphoma (6).

The most frequent presentation of small bowel tumors is occult gastrointestinal bleeding forming 57% of the cases, while chronic abdominal pain, diarrhea and bowel obstruction account for 15% of them (7). Intussusception is the least frequent presentation, particularly in adults. It is most often seen in infants and children and only 5% of all cases are adults. Adult intussusception is genuinely rare, only 1% of adult bowel obstructions are due to intussusception and about 40% of them are related to malignant lesions (6).

### Case report

A 77-year-old man presented with symptoms of partial bowel obstruction; vomiting, pain in the right iliac fossa associated with weight loss (about 5 kg in the last month). On physical examination, the patient looked pale and had a palpable mass on the right iliac fossa. Laboratory tests revealed anemia (Hb=9 d/dl; Hct= 27.1%) and anormal tumor marker level (CEA=0.5 ng/mL). An abdominal ultrasound was performed, which detected a mass in the right iliac fossa of about 12 cm in diameter and multiple nodules spreading in the liver measuring up to 1 cm in diameter. To complete the investigations, a total colonoscopy was performed, revealing a stenosis of the right colon, with aspect of a colic intussusception; biopsies were taken from that area as well. Moreover, a chest X-ray was done, but no tumors were discovered in the lungs.

Histopathological examination revealed nonspecific colitis. During hospitalization, the patient developed complete bowel obstruction and we decided to perform the surgery.

Intraoperatively, an ileo-cecal mass was found measuring 10-12 cm in diameter, causing a complete stenosis at its level and bowel dilatation proximally. The parietal peritoneum and the liver were covered with multiple nodules, measuring 1-1.5 cm in diameter. So we decided to perform a side-to-side ileo-transverso-anastomosis. Biopsies from the peritoneal nodules were taken.

Histological examination revealed a high-grade nonHodgkin's B-cell lymphoma. To confirm the diagnosis, additional immunohistochemical staining analysis of the peritoneal lesions was performed. We used the following markers for immunohistochemical staining: CD 20+ (Fig. 1), AE1/AE3 (negative, exclude poorly differentiated carcinoma) (Fig. 2), CD 3 (negative on the tumoral cells - positive internal control) (Fig. 3), and Ki67 (present in 90% of tumoral cells).

### Discussion

Due to the high proportion of lymphoid tissue, the ileo-

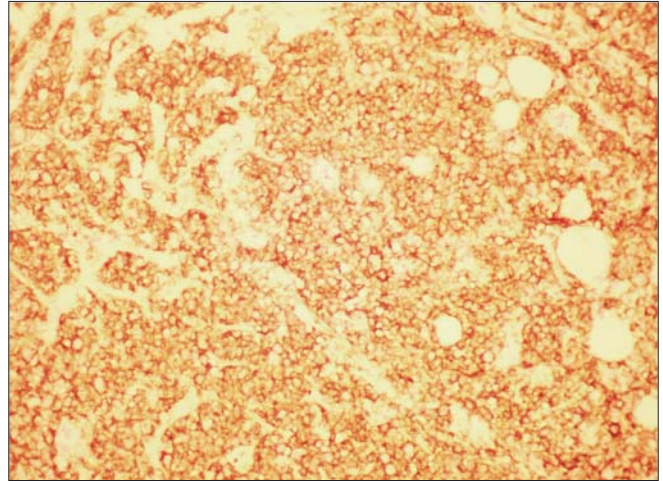


Figure 1. CD20- diffuse positive - 200X

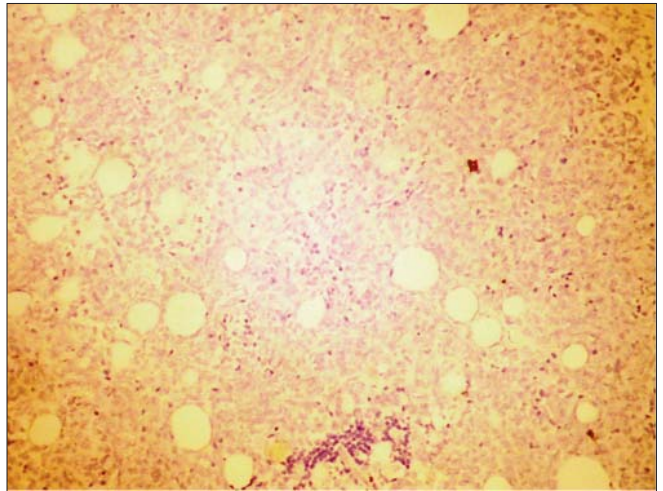


Figure 2. AE1/AE3-negative, excluding poorly differentiated carcinoma - 200X

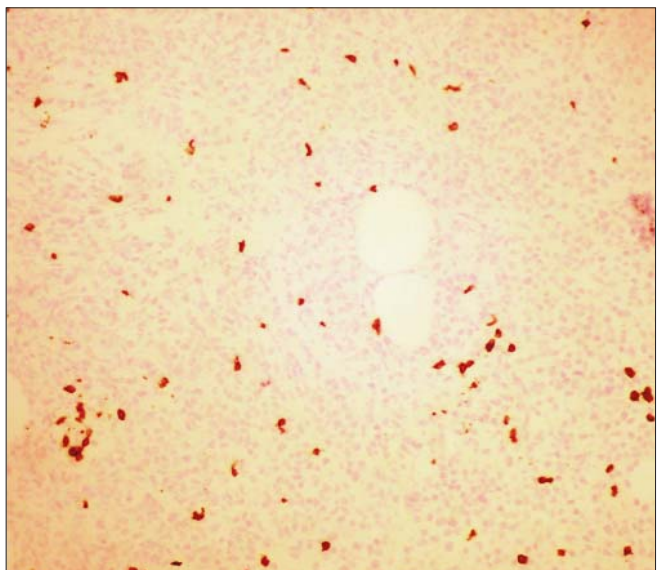


Figure 3. CD3-negative tumor cells (marks few peritumoral T cells) - 200x

cecal region is the most commonly involved site in primary intestinal lymphomas (8, 9). Non-Hodgkin's B-cell lymphoma is the most common subtype of primary lymphoma of the small intestine, and these patients have been found to have a poor outcomes compared to those with lymphoma in other regions of the GI tract (3).

Several studies have shown that surgical resection performed to control the disease locally, to prevent bleeding and/or due to perforation can rarely eliminate the disease when used alone (10-14). Despite this, a surgical resection should always be attempted for localized tumors. On the other hand, the management of extensive GI lymphoma remains a controversy. This lymphoma is commonly diagnosed at an advanced stage, and surgical treatment is only suitable for 30-40% of such patients (3). As a consequence, radiotherapy and adjuvant chemotherapy are essential therapeutic approaches. In case of localized gastric lymphomas radiotherapy is preferred to surgery, but in intestinal lymphomas a combination of surgery and chemotherapy was proven to be superior to any other treatment combination (15).

Regarding the anatomical site, previous studies have shown that ileocecal lymphomas frequently require emergent surgical intervention. Fifty-four percent of ileocecal lymphomas require immediate surgery, while 30% of non-ileocecal lymphomas present with complications (4, 16-19). In our case it was hard to say if it was an ileal or a cecal lymphoma, because this neoplasia includes the area from the distal ileum to the cecum, so it was difficult to precisely designate the primary site of the tumor. Thus, the designation of this region differs among studies, some consider it a part of the small intestine while others a part of the large intestine (20). Regional lymph node involvement is considered as a bad prognosis.

## Conclusion

In conclusion, we describe the diagnosis of adult ileocecal obstruction due to B-cell non-Hodgkin lymphoma with detailed histopathological images of this specific case. Obstruction due to B-cell non-Hodgkin lymphoma must be considered in the differential diagnosis of patients with abdominal pain and vomiting. Work-up must include plain abdominal X-ray, ultrasound and CT scan of the abdomen and PET/CT in special cases. Our patient developed a complete bowel obstruction so a CT scan wasn't necessary, otherwise it could be helpful to determine the cause of the obstruction.

## References

- Campo E, Swerdlow SH, Harris NL, Pileri S, Stein H, Jaffe ES. The 2008 WHO classification of lymphoid neoplasms and beyond: evolving concepts and practical applications. *Blood*. 2011;117(19):5019-32.
- Howell JM, Auer-Grzesiak I, Zhang J, Andrews CN, Stewart D, Urbanski SJ. Increasing incidence rates, distribution and histological characteristics of primary gastrointestinal non-Hodgkin lymphoma in a North American population. *Canadian journal of gastroenterology = Journal canadien de gastroenterologie*. 2012;26(7):452-6.
- Chen JH, Ho CL, Chen YC, Chao TY, Kao WY. Clinicopathological analysis and prognostic factors of 11 patients with primary non-Hodgkin lymphoma of the small intestine in a single institute. *Oncology letters*. 2014;8(2):876-80.
- Koch P, del Valle F, Berdel WE, Willich NA, Reers B, Hiddemann W, et al. Primary gastrointestinal non-Hodgkin's lymphoma: I. Anatomic and histologic distribution, clinical features, and survival data of 371 patients registered in the German Multicenter Study GIT NHL 01/92. *Journal of clinical oncology : official journal of the American Society of Clinical Oncology*. 2001;19(18):3861-73.
- Zinzani PL, Magagnoli M, Pagliani G, Bendandi M, Gherlinzoni F, Merla E, et al. Primary intestinal lymphoma: clinical and therapeutic features of 32 patients. *Haematologica*. 1997;82(3):305-8.
- Xu XQ, Hong T, Li BL, Liu W. Ileo-ileal intussusception caused by diffuse large B-cell lymphoma of the ileum. *World journal of gastroenterology : WJG*. 2013;19(45):8449-52.
- Lee BI, Choi H, Choi KY, Byeon JS, Jang HJ, Eun CS, et al. Clinical characteristics of small bowel tumors diagnosed by double-balloon endoscopy: KASID multi-center study. *Digestive diseases and sciences*. 2011;56(10):2920-7.
- Azar T, Berger DL. Adult intussusception. *Annals of surgery*. 1997;226(2):134-8.
- Bairey O RR, Shoilberg O. Non Hodgkins lymphoma of colon. *IMAJ*. 2006;8:832-6.
- Al-Mondhiry H. Primary lymphomas of the small intestine: east-west contrast. *American journal of hematology*. 1986;22(1):89-105.
- DiSario JA, Burt RW, Vargas H, McWhorter WP. Small bowel cancer: epidemiological and clinical characteristics from a population-based registry. *The American journal of gastroenterology*. 1994;89(5):699-701.
- Rackner VL, Thirlby RC, Ryan JA, Jr. Role of surgery in multimodality therapy for gastrointestinal lymphoma. *American journal of surgery*. 1991;161(5):570-5.
- Salles G, Herbrecht R, Tilly H, Berger F, Brousse N, Gisselbrecht C, et al. Aggressive primary gastrointestinal lymphomas: review of 91 patients treated with the LNH-84 regimen. A study of the Groupe d'Etude des Lymphomes Agressifs. *The American journal of medicine*. 1991;90(1):77-84.
- Shepherd FA, Evans WK, Kutas G, Yau JC, Dang P, Scott JG, et al. Chemotherapy following surgery for stages IE and IIE non-Hodgkin's lymphoma of the gastrointestinal tract. *Journal of clinical oncology : official journal of the American Society of Clinical Oncology*. 1988;6(2):253-60.
- Jayabackthan L, Murgi SB, Graham S, Kini RG. A rare case of primary lymphoma of the caecum presenting as intussusception. *Journal of laboratory physicians*. 2013;5(2):118-20.
- Gurney KA, Cartwright RA, Gilman EA. Descriptive epidemiology of gastrointestinal non-Hodgkin's lymphoma in a population-based registry. *British journal of cancer*. 1999;79(11-12):1929-34.
- Liang R, Todd D, Chan TK, Chiu E, Lie A, Kwong YL, et al. Prognostic factors for primary gastrointestinal lymphoma. *Hematological oncology*. 1995;13(3):153-63.
- Radaszkiewicz T, Dragosics B, Bauer P. Gastrointestinal malignant lymphomas of the mucosa-associated lymphoid tissue: factors relevant to prognosis. *Gastroenterology*. 1992;102(5):1628-38.
- Turowski GA, Basson MD. Primary malignant lymphoma of the intestine. *American journal of surgery*. 1995;169(4):433-41.
- Li B, Shi YK, He XH, Zou SM, Zhou SY, Dong M, et al. Primary non-Hodgkin lymphomas in the small and large intestine: clinicopathological characteristics and management of 40 patients. *International journal of hematology*. 2008;87(4):375-81.