

Subtotal Hysterectomy with Single Port Access Laparoscopy: Gadget or Progress?

Carole Abo¹, Horace Roman^{1,2}

¹Department of Gynecology and Obstetrics, Rouen University Hospital, Rouen, France

²Research Group 4308 « Spermatogenesis and Gamete Quality », Institute for Research and Innovation in Biomedicine, Normandie Université, Rouen, France; IFRMP23, Reproductive Biology Laboratory, Rouen University Hospital, Rouen, France

Rezumat

Histerectomia subtotală prin single port: progres sau gadget?

Context: Punctele forte ale laparoscopiei în comparație cu laparotomia sunt spitalizarea mai scurtă, reducerea durerii postoperatorii și aderențelor, precum și aspectul estetic al cicatricilor. Începând cu anul 2008, laparoscopia single port (SPAL) a fost folosită în scopul de a oferi beneficii suplimentare estetice și o morbiditatea postoperatorie mai scăzută. Scopul acestui studiu a fost evaluarea histerectomiei subtotale prin SPAL și a beneficiilor și limitelor acestei tehnici.

Metode: Serie retrospectivă de 15 de femei operate între septembrie 2010 și februarie 2013, pentru o histerectomie subtotală prin SPAL pentru patologii benigne.

Rezultate: Din cele 15 proceduri, 12 au fost efectuate numai prin SPAL. Trei conversii la laparoscopie clasică au fost necesare pentru un uter foarte voluminos (1 caz) sau sindrom aderențial sever (2 cazuri). Complicațiile postoperatorii au fost o plagă a vezicii urinare, un hematom subombilical și a fragmentare transcervicală a unui uter purtător de un sarcom uterin de grad scăzut. Timpul operator mediu a fost de 85,4 minute (50-170). Spitalizarea medie a fost de 2 zile. Rata de satisfacție a pacienților la 16 luni de la operație a fost de 9.2/10.
Concluzie: Histerectomia subtotală prin SPAL este o tehnică elegantă și realizabilă. Reușita procedurii necesită selecție corectă a pacienților, căci poate fi influențată negativ de

obezitatea morbidă, antecedentele de chirurgie abdominală sau uterul foarte voluminos. Cu toate acestea, noi considerăm că SPAL reprezintă o etapă de progres în dezvoltarea chirurgiei laparoscopice.

Cuvinte cheie: laparoscopie cu acces unic, histerectomie subtotală, laparoscopie, ginecologie

Abstract

Background: The strengths of surgical laparoscopy compared to laparotomy include shorter hospitalization, reduction in post-operative pain and adhesions, and better cosmetic outcomes. Since 2008, Single Port Access Laparoscopy (SPAL) has been used in order to offer additional cosmetic benefits and to further reduce post-operative morbidity. The aim of this study was to assess the feasibility of a subtotal hysterectomy using SPAL technique, as well as the benefits and the limitations of this technique.

Methods: Retrospective series of 15 women managed between September 2010 and February 2013 at our university tertiary referral center by subtotal hysterectomy using SPAL technique for benign pathologies.

Results: Twelve of the 15 procedures were performed by SPAL alone. Three conversions to classic laparoscopy were required for a large uterus (1 case) or major pelvic adhesions (2 cases). Postoperative complications were a bladder injury, a sub-umbilical hematoma and transcervical fragmentation of a uterus with a low-grade sarcoma. Mean operative time was 85.4 minutes (50-170). Postoperative hospitalization was of 2 days in average. The rate of patient satisfaction at 16-month follow-up was 9.2 / 10.

Corresponding author:

Horace Roman, MD PhD
Department of Gynecology and Obstetrics
Rouen University Hospital, Rouen, France
Hôpital-Charles Nicolle, 1 rue de Germont
76031 Rouen, France
E-mail: horace.roman@gmail.com

Conclusion: Subtotal hysterectomy using SPAL technique is safe and feasible. Successful procedure requires accurate selection of patients taking into account main limitations, such as uterus weight, patient's BMI and abdominal surgical history. Notwithstanding, SPAL technique can be seen as technical progress.

Key words: single port access laparoscopy, subtotal hysterectomy, laparoscopy, gynecology

Introduction

For many years, surgeons and patients have agreed on the advantages of laparoscopy compared to laparotomy, for several gynecologic surgical indications. Indeed, the strengths of surgical laparoscopy include shorter hospitalization, reduction in post-operative pain, decrease in post-operative adhesions, and better cosmetic outcomes.

Since 2008, Single Port Access Laparoscopy (SPAL) has been used for different indications, in order to offer additional cosmetic benefits (1), (Fig. 1) and to further reduce post-operative morbidity (2).

At the end of 2008, we introduced SPAL in our practice, and more than 50 procedures have been performed over the past 4 years: ovarian cystectomies, deep infiltrating endometriosis surgery, subtotal and total hysterectomies, appendectomies, and ablation of endometriomas using PlasmaJet. In the meantime, the introduction of the lasso with monopolar current in laparoscopy has facilitated sectioning of the uterine isthmus and as a consequence subtotal hysterectomy by laparoscopy. Thus, our SPAL indications have progressively been limited to subtotal hysterectomies, with very similar operative durations and conditions to those of standard laparoscopy.

The aim of this study was to assess the feasibility of a subtotal hysterectomy using SPAL technique, as well as the benefits and the limitations of this technique in a series of 15 patients.

Material and Methods

We retrospectively analyzed a single center series of 15 patients managed at our university tertiary referral center between September 2010 and February 2013. Patients' age at time of intervention was between 38 and 55 years, and their BMI was between 18.4 and 36.5 (Table 1). The main surgical indications were pelvic pain and menometrorrhagia. The presumed diagnoses before intervention were uterine fibroids, adenomyosis, endometriosis, pelvic adhesions and hematosalpinx. We did not routinely perform uterine biopsies prior to surgery. In all 15 cases, the suggested intervention included a subtotal hysterectomy with SPAL. All 15 patients had been informed of the advantages and drawbacks of this technique and had given their consent. All 15 interventions were performed by the same surgeon who had more than 10 months experience in SPAL technique (ovarian cystectomies, appendectomies) on beginning the series.

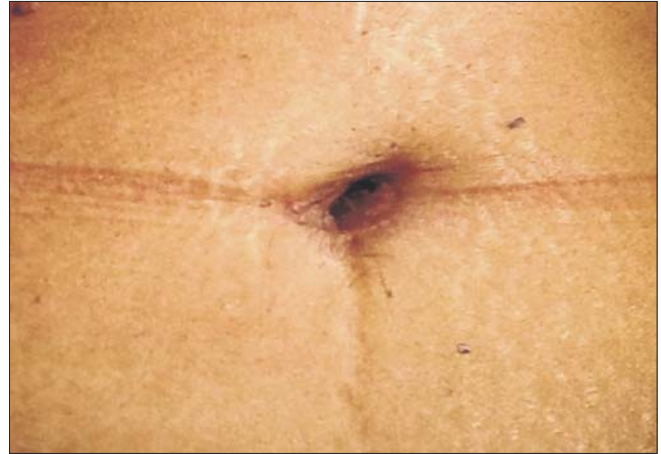

Figure 1. Umbilical scar after subtotal hysterectomy with SPAL

Surgical technique

The procedure is performed under general anesthesia by laparoscopic route with Single Port Access Laparoscopy. A transverse or longitudinal incision is made at the bottom of the umbilicus, approximately 3 cm in length. The technique is similar to that used for open laparoscopy, the only difference being the size of the incision which is twice longer. After opening the peritoneum, either the X-CONE system (KarlStorz, Tuttlingen, Germany) (Fig. 2) or the laparoendoscopic single site (LESS) device (Olympus, Hamburg, Germany) is placed. In the present series, the X-CONE system and the LESS system were used in 13 and 2 procedures respectively.

The patient is placed in the Trendelenburg position in order to facilitate backflow of the digestive tract that might disturb operative procedures. This is made easier by strictly following a no residue diet during the week prior to the intervention. A uterine manipulator using a vaginal valve like the Clermont Ferrand model (KarlStorz, Tuttlingen, Germany) is placed inside the uterus and handled by the second operative assistant positioned between the legs of the patient. The 5 mm diameter and 30° vision angle endoscope is introduced through the trocar orifice on the right hand side [on the side of the gynecology resident, (Fig. 2)], offering an intra-operative view of the slightly lateralized pelvis, from the left to the right of the patient (Fig. 3).

An atraumatic grasping forceps is used to expose the organs (usually the ovaries and the fallopian tubes) and is inserted through the trocar orifice located on the left hand side of the patient [on the side of the operator, (Fig. 4)]. In order to grasp the left adnexa, we prefer to use a dual curved grasper (Fig. 5A), which appears on the left hand side of the patient in the operating field. The handling of this surgical clamp by the left hand of the operator facilitates the fluidity of the operative gesture. To grasp the right adnexa, we deliberately use a monocurved grasper, which appears on the right hand side of the patient in the operating field (Fig. 5B).

The instruments used for tissue coagulation are straight

Table 1. Preoperative characteristics, surgical technique and indications

| Patient | Age (year) | Weight (kg) | BMI (kg/m2) | Surgical indication | Preoperative diagnosis | Surgery performed | Trocar used | Section of isthmus (monopolar scissors, lasso monopolar, etc.) | Morcellation (cervix, umbilicus) |
|---------|------------|-------------|-------------|---------------------|--|-------------------|-------------|--|----------------------------------|
| 1 | 50 | 56 | 21.3 | PP | UF | SH | X-cone | ML | TU |
| 2 | 52 | 53 | 21.5 | PP | UF | SH | X-cone | ML | TC |
| 3 | 47 | 43 | 18.4 | MM | UF | SH | X-cone | ML | TC |
| 4 | 43 | 65 | 22 | PP, M | UF | SH | X-cone | ML | TC |
| 5 | 51 | 90 | 36.5 | Veinous thrombosis | UF | SH | Less | ML | TU |
| 6 | 39 | 84 | 29.1 | PP,MM | UF | SH | X-cone | ML | TC |
| 7 | 42 | 52 | 20.8 | PP | UF | SH | X-cone | ML | TC |
| 8 | 53 | 56 | 25.2 | PP, MM | UF | SH | X-cone | ML | TC |
| 9 | 38 | 67 | 22.6 | PP | UF | SH | Less | ML | TC |
| 10 | 49 | 69 | 27.6 | M | A | SH | X-cone | ML | TC |
| 11 | 54 | 64 | 25 | MM | UF, A | SH + BA | X-cone | ML | TC |
| 12 | 45 | 79 | 27.3 | PP | UF, A, endometriosis, right hemato-salpinx | SH + BA | X-cone | ML | TU |
| 13 | 40 | 70 | 26.3 | PP, M | UF, endometriosis, adhesions | SH | X-cone | ML | TU |
| 14 | 48 | 72 | 28.8 | PP | UF | SH | X-cone | ML | Suprapubic |
| 15 | 43 | 60 | 23.7 | PP, MM | A | SH | X-cone | ML | TC |

PP: Pelvic Pain; MM: MenoMetrorrhagia; M: Metrorrhagia; UF: uterine fibroids; A: Adenomyosis; SH: Subtotal Hysterectomy; SH+BA: Subtotal Hysterectomy and Bilateral Adnexectomy; ML: Monopolar Loop; TU: Transumbilical; TC: Transcervical

standard laparoscopy forceps. Coagulation is achieved with a bipolar forceps, an ultrasonic scalpel or a thermofusion grasper. These straight instruments are always inserted through the central trocar orifice and handled by the right hand of the operator.

The surgical technique performed is identical to that used in classic laparoscopy. In the case of an interadnexal hysterectomy, we perform coagulation and section of the round ligaments, opening of the broad ligament, and sectioning of the utero-ovarian ligament and fallopian tubes. When bilateral adnexectomy is performed, we carry out opening of the broad ligament, followed by section of the infundibulo-pelvic ligaments. The vascular uterine pedicle is identified and coagulated at the level

of the isthmus. When the uterus is larger than 300-500g, we perform coagulation of the uterine artery at its origin before dissecting it at the level of the isthmus, where access is considerably hampered by the uterine body (3).

In order to section the uterine isthmus, we use a monopolar lasso type Supraloop (Karl Storz, Tuttlingen, Germany) regulated at a power of 120 W. The gesture is simple and generates a very limited quantity of smoke. After sectioning of the isthmus and ablation of the uterine body, uterine pedicle coagulation is performed easily.

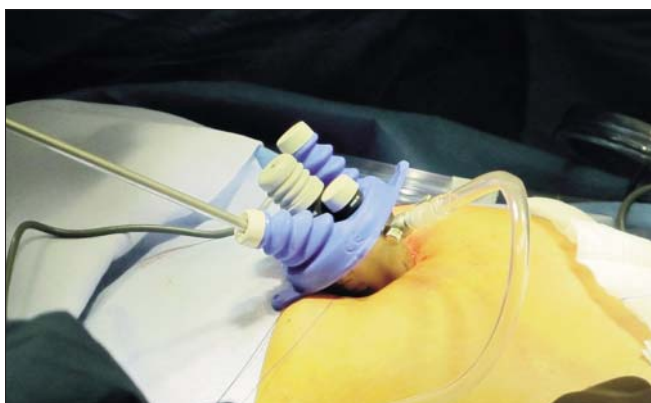

Figure 2. X-CONE system, camera located on the right hand side of the patient

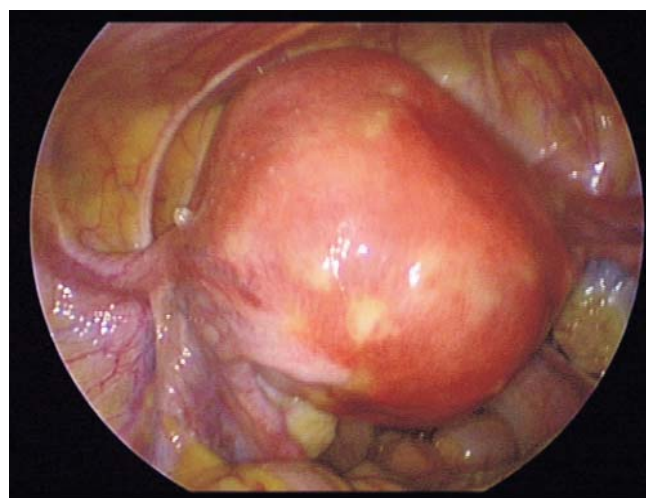


Figure 3. Intraoperative view of the pelvis prior to SPAL intervention

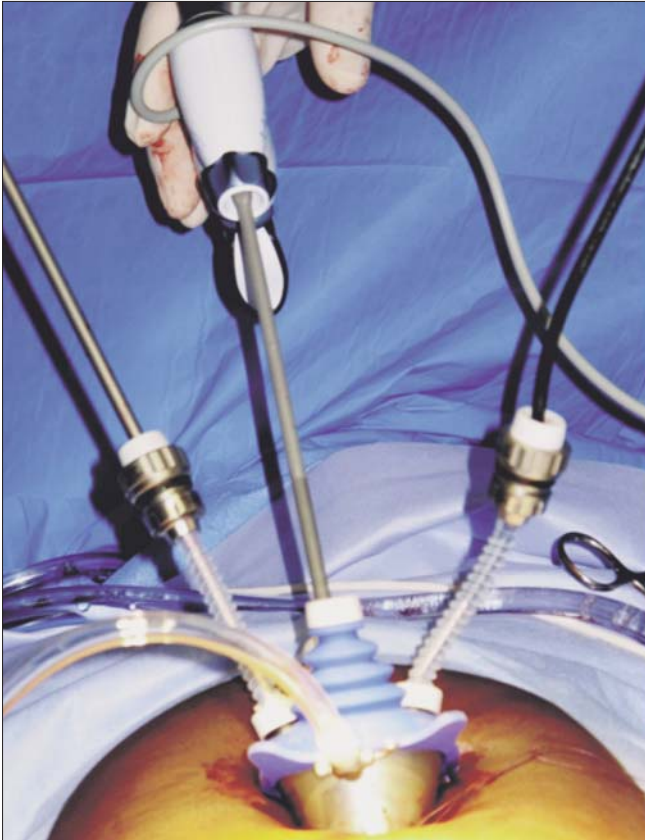


Figure 4. X-CONE system: camera on the right, thermofusion instrument in the middle, dual curve grasper on the left

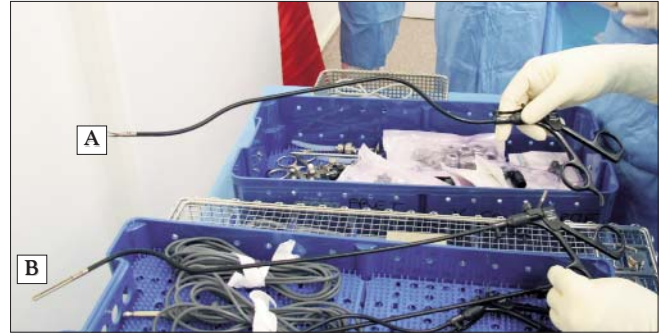

Figure 5. (A): dual curved grasper, (B): monocurved grasper

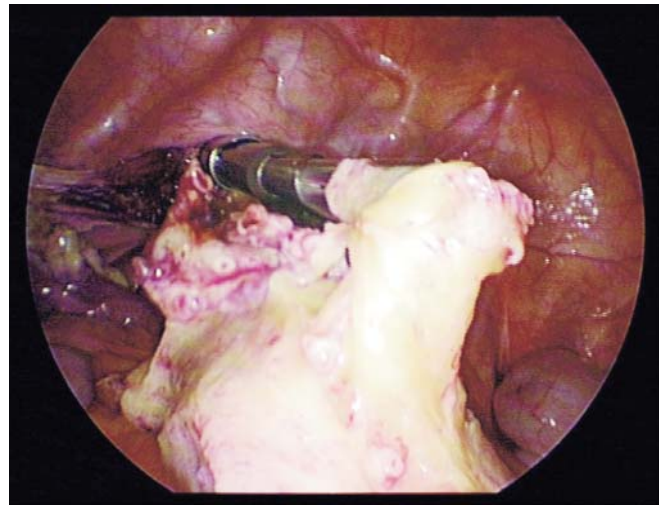


Figure 6. Transcervical morcellation

To perform morcellation, we use a morcellator introduced by transcervical route. The surgeon is positioned between the patient's legs and performs morcellation with endoscopic control. This operative step may be laborious due to movement reversal, given that the endoscope continues through the umbilicus and offers a caudal view (Fig. 6). In our series, there was one case of a small uterus for which we performed morcellation by transumbilical route after ablation of the trocar, but the sheath was left in place. After retrieval of myometrium pieces dispersed in the pelvis, we performed an abdominal wash with Ringer Lactate. A 16 fr drain may be left in place in the pouch of Douglas and externalized through the cervix. It was attached to the patient's leg by adhesive tape and removed by simple traction the day after surgery.

Patient satisfaction was assessed by telephone. The global rate of satisfaction was scored between 0 and 10 and included postoperative results, notably postoperative pain and cosmetic results.

Statistical analysis was performed using Stata 9.0 software (Stat Corporation, Lakeway Drive, TX, USA). We calculated the mean and median values as well as range for continuous variables, and percentages for qualitative variables.

Results

In our series, 12 of the 15 interventions were completely

performed with SPAL technique with an average operating time of 108 minutes (Table 2). In three cases, the intervention was switched to standard laparoscopy with four trocars because of the existence of a large uterus (500g), expanded in longitudinal direction and masking the access to the origin of the uterine arteries or because of severe postoperative pelvic adhesions (2 cases). In one case, an additional suprapubic incision of 12 mm was necessary for morcellation of the uterus. No difference was observed between the X-cone system and the LESS system regarding the feasibility of the procedure.

The incision was closed in two planes: an X stitch with a slow absorption stitch on the aponeurosis of the abdominal vertical muscle and separate stitches on the skin with non absorbable stitches.

In regards to intraoperative incidents, a bladder injury occurred during incision of the uterine isthmus. The peritoneum of the vesico-uterine pouch had not been opened, as is usual practice during a subtotal hysterectomy, and a fold of the bladder dome was caught in the monopolar loop. Repair was performed by a stitch of the bladder in one plane and maintenance of the bladder catheter for 8 days.

Another intraoperative incident concerned the transcervical morcellation of a uterus with a low grade sarcoma in a 36-year-old patient with repeat fundic myoma, and a history of

myomectomy performed by the same operator 6 years before. Upon diagnosis of sarcoma based on the fragments analyzed, a second laparoscopy enabled a trachelectomy, with a bilateral adnexectomy and multiple peritoneal biopsies. Three years after surgery, the patient had completely recovered, but was still under biannual medical supervision with annual thoracic-abdominal-pelvic CT scans.

Three immediate postoperative complications were observed. A 40 mm diameter hematoma from the preperitoneal sub-umbilical space appeared after the intervention and was responsible for the persistence of significant localized pain for 2 months. Two incisional hernias of 2 to 3 cm in diameter were observed at the site of the umbilical single port access during the postoperative visit about two months after surgery. One patient had surgical repair by open mesh repair. The second patient did not require surgical repair, because the hernia was not responsible for any complaint. One patient presented with postoperative anemia (hemoglobin level at 9.2g/dL), which was managed by administration of oral iron medication. Another patient had wound infection characterized by inflammation of the skin around the scar and a yellow fluid without abscess which was managed by local treatment. Hospitalization length averaged 3 ± 2 days. After a mean follow-up of 15 ± 8 months, patient satisfaction rate was 9.2 ± 1 .

Discussion

In this study, we have presented 15 cases of subtotal hysterectomy by SPAL; 12 of which were completely managed by SPAL technique. The remaining three cases underwent standard laparoscopy and consequent introduction of additional trocars. In hindsight, these three cases can be explained by specific situations and constituted contraindications for SPAL. This could suggest that SPAL technique requires strict patient selection during the preoperative appointment. The success of SPAL technique is mainly based on the accurate pre-operative assessment of the patient.

SPAL technique is relatively new. It offers certain advantages such as cosmetic results (1,4,5), a supposed reduction in postoperative pain (2,6) and prevention of oblique muscle hematoma thanks to single port access.

Nevertheless, there are drawbacks to SPAL technique that probably restrict its wide spread application. SPAL clearly requires a learning curve, which increases with the complexity of the procedure (7). The instruments that are used are right-angled and insertion through one single orifice restricts their movements and requires repetitive operations of layout (8). Moreover, it is almost impossible to use more than two operative instruments (three including the endoscope), which could represent a backward step for surgeons, who are used to working with three operative instruments.

These difficulties can be bypassed with the help of the da Vinci robot (Intuitive Surgical Inc, Sunnyvale, United States) (8,9). Indeed, the robot facilitates SPAL by avoiding conflict between the instruments (10,11) used during standard laparoscopy. Inversion of laterality is corrected by equal inversion of the controls at the robot console level. It is then

possible to use three instruments at the same time. This gains time and improves surgeons' dexterity (6,10,12). In addition, the use of right-angled instruments and 3D vision enables increased preoperative ergonomics.

Existing data on SPAL support the cosmetic benefits of this technique. Indeed, SPAL is based on a single umbilical incision and existing studies clearly demonstrate the significant cosmetic advantage of SPAL compared to standard laparoscopy (1,4,5). Moreover, SPAL technique seems as safe as standard laparoscopy and does not represent any additional post-operative risks (1,13,14). Nonetheless, in our short series, the complication rate (3/15) seems high compared to subtotal hysterectomy by standard laparoscopy. We observed a particularly high rate of umbilical hernia (2/15 i.e. 13.3% versus 1% by laparoscopy) (15,16) even if a Vicryl 0 loop suture of the aponeurosis was systematically and carefully performed.

The study by Gun Yoon et al (17) reported a series of 7 patients having undergone subtotal hysterectomy for benign disease, whose characteristics were comparable to those of our patients. Mean operative time was higher than that recorded in our series: 157 min vs. 108 min. No postoperative hernia was observed, although their follow-up was only 1 month. Park et al (18) reported a series of 200 patients managed by SPAL (11 of whom underwent subtotal hysterectomy), with mean operative time averaging 180 min. They reported one rectovaginal fistula.

Notwithstanding, the question remains as to the interest of SPAL regarding post-operative pain (19). Not all authors agree that SPAL reduces post-operative pain. The randomized trial by Fagotti et al, and the study by Chen et al showed a significantly low consumption of analgesics for patients operated with SPAL technique (6,20). However, studies by Teoh et al and Hoyer et al described similar or even increased post-operative pain after an intervention with SPAL (4,21). This could be explained by longer operating time (22,23) for SPAL with patients mainly reporting scapular pain. By improving surgeons' training and by limiting the technical constraints of SPAL, both operating duration and post-operative pain could be lowered (24).

Our series only involved patients who had subtotal hysterectomy. We think that SPAL could be used more widely since it enables a relatively frequent and standardized intervention that cannot be done by alternative route, in our case vaginal accessibility. Our experience has progressively led us to subtotal hysterectomy, since total laparoscopic hysterectomy, accessible by SPAL (small or medium size uterus, without adhesions), remains easily accessible by vaginal route. Moreover, subtotal hysterectomy can present advantages compared to total hysterectomy, as it reduces preoperative and post-operative bleeding, and affords quicker recovery related to lack of vaginal scar (25,26).

There are also possible consequences even if they have not been proved yet regarding pelvic statics and sexuality. Hysterectomy can have an impact on pelvic floor stability, sexuality, prolapse or urinary function. In this context, subtotal hysterectomy may have some advantages. As regards sexuality, a few studies including those by Ellström et al (27) and by Kilkku

Table 2. Postoperative outcomes

| | Operative time (min) | Estimated blood loss (mL) | Early complications | Discharge (days) | Late complications | Follow-up (months) | Pathology diagnosis | Patient satisfaction (0-10) | Uterus weight (g) | Additional information |
|----|----------------------|---------------------------|------------------------------------|------------------|--------------------|--------------------|----------------------|-----------------------------|-------------------|--|
| 1 | 80 | 50 | Bladder catheterization for 8 days | 2 | 0 | 8 | Myoma | 10 | 500 | Conversion to conventional laparoscopy |
| 2 | 170 | 150 | 0 | 8 | Umbilical hernia | 16 | Myoma | 8 | 400 | Bladder wound |
| 3 | 50 | 50 | 0 | 1 | Umbilical hernia | 13 | Myoma | 6 | 150 | |
| 4 | 90 | 50 | 0 | 3 | 0 | 15 | Myoma | 10 | 130 | |
| 5 | 110 | 100 | 0 | 3 | 0 | 28 | Myoma | 10 | 100 | |
| 6 | 80 | 50 | 0 | 2 | 0 | 23 | Myoma | 9 | 265 | |
| 7 | 140 | 100 | 0 | 3 | 0 | 2 | Myoma | 10 | 400 | Cure of umbilical hernia |
| 8 | 130 | 100 | 0 | 2 | 0 | 17 | Myoma | 10 | 350 | |
| 9 | 75 | 50 | 0 | 1 | 0 | 11 | Low grade sarcoma | 10 | 111 | Benign myoma in 2005 |
| 10 | 50 | 50 | 0 | 2 | 0 | 24 | Adenomyosis | 10 | 114 | |
| 11 | 80 | 50 | 0 | 2 | 0 | 8 | Adenomyosis | 8 | 70 | |
| 12 | 230 | 250 | Anemia | 3 | 0 | 23 | Adenomyosis, myoma | 10 | 500 | Conversion to conventional laparoscopy |
| 13 | 160 | 400 | 0 | 5 | 0 | 17 | Endometriosis, myoma | 10 | 110 | Conversion to conventional laparoscopy |
| 14 | 120 | 100 | Scar infection | 4 | 0 | 14 | Myoma | 8,5 | 550 | Morcellation by a supra-pubic incision |
| 15 | 50 | 50 | 0 | 2 | 0 | 3 | Endometrial atrophy | 8 | 71 | |

et al (28,29), have shown better preservation of sexual activity after subtotal hysterectomy; less dyspareunia. Regarding urinary function, we observed a significant reduction in urinary incontinence symptoms after subtotal hysterectomy compared to total hysterectomy (25.1% vs. 7.4%) (30,31) for comparable groups of women. Notwithstanding, additional randomized studies are necessary in order to confirm those results.

Conclusion

In our experience, subtotal hysterectomy using SPAL technique is safe and feasible since 12 of the 15 procedures were performed by SPAL alone. SPAL has gained a specific place in the armamentarium of gynecologic surgeons and may be considered as technical progress. We are convinced of the success of SPAL when preceded by rigorous patient selection.

Acknowledgments

The authors are grateful to Nikki Sabourin-Gibbs, Rouen University Hospital, for writing assistance and review of the manuscript in English.

Conflict of interest

The authors declare no conflict of interest related to the submitted work.

References

1. Song Taejong, Cho Juhee, Kim Tae-Joong, et al. Cosmetic out-

comes of laparoendoscopic single-site hysterectomy compared with multi-port surgery: randomized controlled trial. *J Minim Invasive Gynecol.* 2013;20(4):460-7.

2. Fagotti Anna, Bottoni Carolina, Vizzielli Giuseppe, et al. Postoperative pain after conventional laparoscopy and laparoendoscopic single site surgery (LESS) for benign adnexal disease: a randomized trial. *Fertil Steril.* 2011;96(1): 255-9.e2.

3. Roman Horace, Zanati Joel, Friederich Ludovic, Resch Benoit, Lena Eric, Marpeau Loic. Laparoscopic hysterectomy of large uteri with uterine artery coagulation at its origin. *JSL J Soc Laparoendosc Surg Soc Laparoendosc Surg.* 2008;12(1):25-9.

4. Teoh Anthony Yuen Bun, Chiu Philip Wai Yan, Wong Tiffany Cho Lam, et al. A double-blinded randomized controlled trial of laparoendoscopic single-site access versus conventional 3-port appendectomy. *Ann Surg.* 2012;256(6):909-14.

5. Sasaki Akira, Ogawa Masaaki, Tono Chihiro, Obara Shin, Hosoi Nobuyuki, Wakabayashi Go. Single-port versus multi-port laparoscopic cholecystectomy: a prospective randomized clinical trial. *Surg Laparosc Endosc Percutan Tech.* 2012; 22(5):396-9.

6. Fagotti A, Corrado G, Fanfani F, et al. Robotic single-site hysterectomy (RSS-H) vs. laparoendoscopic single-site hysterectomy (LESS-H) in early endometrial cancer: a double-institution case-control study. *Gynecol Oncol.* 2013;130(1):219-23.

7. Tay Chee Wei, Shen Liang, Hartman Mikael, Iyer Shridhar Ganpathi, Madhavan Krishnakumar, Chang Stephen Kin Yong. SILC for SILC: Single Institution Learning Curve for Single-Incision Laparoscopic Cholecystectomy. *Minim Invasive Surg.* 2013;2013:381628.

8. Tang Benjie, Hou Sichuan, Cuschieri Sir Alfred. Ergonomics of and technologies for single-port laparoscopic surgery. *Minim Invasive Ther Allied Technol MITAT Off J Soc Minim Invasive Ther.* 2012;21(1):46-54.

9. Autorino Riccardo, Kaouk Jihad H, Stolzenburg Jens-Uwe, et al. Current status and future directions of robotic single-site surgery: a systematic review. *Eur Urol.* 2013;63(2):266-80.

10. Joseph Rohan A, Goh Alvin C, Cuevas Sebastian P, et al. "Chopstick" surgery: a novel technique improves surgeon performance and eliminates arm collision in robotic single-incision laparoscopic surgery. *Surg Endosc*. 2010;24(6):1331–5.
11. Kaouk Jihad H, Goel Raj K, Haber Georges-Pascal, Crouzet Sebastien, Stein Robert J. Robotic single-port transumbilical surgery in humans: initial report. *BJU Int*. 2009;103(3):366–9.
12. Pathiraja Pubudu, Tozzi Roberto. Advances in gynaecological oncology surgery. *Best Pract Res Clin Obstet Gynaecol*. 2013;27(3):415–20.
13. Li M, Han Y, Feng YC. Single-port laparoscopic hysterectomy versus conventional laparoscopic hysterectomy: a prospective randomized trial. *J Int Med Res*. 2012;40(2):701–8.
14. Jung Yong Wook, Lee Maria, Yim Ga Won, et al. A randomized prospective study of single-port and four-port approaches for hysterectomy in terms of postoperative pain. *Surg Endosc*. 2011; 25(8):2462–9.
15. Montz FJ, Holschneider CH, Munro MG. Incisional hernia following laparoscopy: a survey of the American Association of Gynecologic Laparoscopists. *Obstet Gynecol*. 1994;84(5): 881–4.
16. Boike GM, Miller CE, Spirtos NM, et al. Incisional bowel herniations after operative laparoscopy: a series of nineteen cases and review of the literature. *Am J Obstet Gynecol*. 1995;172(6):1726–31; discussion 1731–3.
17. Yoon Gun, Kim Tae-Joong, Lee Yoo-Young, et al. Single-port access subtotal hysterectomy with transcervical morcellation: a pilot study. *J Minim Invasive Gynecol*. 2010;17(1):78–81.
18. Park Hwang Shin, Kim Tae-Joong, Song Taejong, et al. Single-port access (SPA) laparoscopic surgery in gynecology: a surgeon's experience with an initial 200 cases. *Eur J Obstet Gynecol Reprod Biol*. 2011;154(1):81–4.
19. Rabischong B, Compan C, Savary D, et al. (Laparoendoscopic single-site surgery in gynecology: the situation in 2013). *J Gynécologie Obstétrique Biol Reprod*. 2013;42(5):445–57.
20. Chen Yi-Jen, Wang Peng-Hui, Ocampo Elizabeth Joan, Twu Nae-Fang, Yen Ming-Shyen, Chao Kuan-Chong. Single-port compared with conventional laparoscopic-assisted vaginal hysterectomy: a randomized controlled trial. *Obstet Gynecol*. 2011;117(4):906–12.
21. Hoyer-Sørensen Christian, Vistad Ingvild, Ballard Karen. Is single-port laparoscopy for benign adnexal disease less painful than conventional laparoscopy? A single-center randomized controlled trial. *Fertil Steril*. 2012;98(4):973–9.
22. Fanfani Francesco, Fagotti Anna, Gagliardi Maria Lucia, et al. Minilaparoscopic versus single-port total hysterectomy: a randomized trial. *J Minim Invasive Gynecol*. 2013;20(2):192–7.
23. Angioni Stefano, Pontis Alessandro, Pisanu Adolfo, Mereu Liliana, Roman Horace. Single-port Access Subtotal Laparoscopic Hysterectomy: A Prospective Case-Control Study. *J Minim Invasive Gynecol*. 2015;22(5):807–12.
24. Fader Amanda Nickles, Rojas-Espaillet Luis, Ibeanu Okechukwu, Grumbine Francis C, Escobar Pedro F. Laparoendoscopic single-site surgery (LESS) in gynecology: a multi-institutional evaluation. *Am J Obstet Gynecol*. 2010;203(5):501.e1–6.
25. Iftikhar Razia. The outcome of subtotal abdominal hysterectomy. *J Coll Physicians Surg--Pak JCPSP*. 2005;15(10):594–6.
26. Thakar Raneey, Ayers Susan, Clarkson Peter, Stanton Stuart, Manyonda Isaac. Outcomes after total versus subtotal abdominal hysterectomy. *N Engl J Med*. 2002;347(17): 1318–25.
27. Ellström Engh Marie A, Jerhamre Karin, Junsokog Karin. A randomized trial comparing changes in sexual health and psychological well-being after subtotal and total hysterectomies. *Acta Obstet Gynecol Scand*. 2010;89(1):65–70.
28. Kilkku P. Supravaginal uterine amputation vs. hysterectomy. Effects on coital frequency and dyspareunia. *Acta Obstet Gynecol Scand*. 1983;62(2):141–5.
29. Kilkku P, Grönroos M, Hirvonen T, Rauramo L. Supravaginal uterine amputation vs. hysterectomy. Effects on libido and orgasm. *Acta Obstet Gynecol Scand*. 1983;62(2):147–52.
30. Kilkku P. Supravaginal uterine amputation versus hysterectomy with reference to subjective bladder symptoms and incontinence. *Acta Obstet Gynecol Scand*. 1985;64(5):375–9.
31. Gimbel Helga, Zebbe Vibeke, Andersen Birthe Margrethe, Filtenborg Thomas, Gluud Christian, Tabor Ann. Randomised controlled trial of total compared with subtotal hysterectomy with one-year follow up results. *BJOG Int J Obstet Gynaecol*. 2003;110(12):1088–98.