

Retromuscular Approach in Ventral Hernia Repair - Endoscopic Rives-Stoppa Procedure

Victor Gheorghe Radu

Department of Surgery, Life Memorial Hospital, Bucharest, Romania

Corresponding author:

Victor Gheorghe Radu, MD
Department of Surgery
Life Memorial Hospital,
Bucharest, Romania
E-mail: dr.victor.radu@gmail.com

Abbreviations:

eTEP - extended total extra-peritoneal approach;
TEP - total extraperitoneal;
MIS - minimally invasive surgery;
IPOM - intraperitoneal onlay mesh;
TAR - transversus abdominis release;

Rezumat

Procedeu Rives-Stoppa prin abord endoscopic – cura chirurgicală a herniilor ventrale prin abord retromuscular

Introducere: În 1993 Leblanc a adăugat în gama operațiilor laparoscopice repararea herniilor ventrale. Procedului i-au fost aduse îmbunătățiri semnificative ca urmare a unor profunde schimbări de paradigmă privind restaurarea arhitecturii și funcționalității peretelui abdominal. Plasarea protezei în spațiul retromuscular – inițial o provocare în chirurgia laparoscopică, este acum o tehnică bine codificată.

Metodă: Abordul TEP cunoscut în cura herniei inghinale, este extins cranial în teaca dreptului abdominal. Traversarea liniei albe spre teaca dreptului abdominal controlateral, rămânând în afara cavității peritoneale, permite disecția retromusculară, reducerea herniei, refacerea liniei albe și plasarea unei proteze de polipropilenă înapoia dreptilor abdominali.

Rezultate: În intervalul iunie 2016 – decembrie 2017 am aplicat procedeul la 63 de pacienți cu hernia ventral primare sau incizionale cu suprafața mediană de 60 cm² (6 - 300). Pentru închiderea defectului și refacerea liniei albe a fost necesar efectuarea TAR la 19 cazuri. Spitalizarea mediană a fost de 1 zi (1 – 9) iar urmărirea pacienților s-a efectuat la 2 luni, 6 luni, 1 an. Până în prezent a fost înregistrat 1 caz cu durere cronică și nici un caz de recidivă.

Concluzie: Combinând avantajele operației Rives-Stoppa cu avantajele operațiilor minim invazive, abordul endoscopic retromuscular tinde să ocupe un loc primordial în cura herniilor ventrale.

Cuvinte cheie: abord endoscopic TEP, repararea herniei ventrale retromusculare

Received: 21.11.2018

Accepted: 15.01.2019

Abstract

Introduction: In 1993 Leblanc published his laparoscopic technique in ventral hernia repair. The procedure has been improved due to deeply change of the paradigm in abdominal wall reconstruction. Placing the mesh into the retrorectus space was initially a big challenge but now the Rives-Stoppa procedure by endoscopic approach – extended total extra-peritoneal approach (eTEP) become a well known technique.

Method: The total extraperitoneal (TEP) approach used in inguinal hernia repair, is extended cranially into the rectus sheath. Crossover the midline toward the contralateral retrorectus space, being outside the peritoneal cavity, allows bilateral retrorectus dissection, reducing the hernia, restoring the linea alba and placing a polypropylene mesh under the rectus muscles.

Results: I applied this technique between 2016 June – 2017 December in 63 cases in ventral (primary or incisional) hernia repair having median area 60 sqcm (6 – 300). To close the defect and restore linea alba it was necessary to perform TAR in 19 cases. Median hospitalisation was 1day (1 – 9). Follow up at 2, 6, 12 months: 1 case with chronic pain and no recurrences until now.

Conclusions: Combining the advantages of the Rives-Stoppa procedure with the the advantages of minimally invasive surgery (MIS), the eTEP approach tends to occupy an important place in ventral hernia repair.

Key words: eTEP, ventral hernia retromuscular repair

Introduction

Knowing the high incidence of the incisional hernia (over 10%) and that it involves a previous surgery, we can say that incisional hernia is the most frequent iatrogenic disease.

Laparoscopic ventral hernia repair was described 25 years ago by Karl Leblanc (1).

His surgery implies adhesiolysis, reducing the hernia and covering the defect using a mesh fixed by unresorbable tackers intraperitoneal onlay mesh (IPOM).

Since then this procedure has been upgraded; the most important upgrade was changing the bridging concept with augmentation. That means closure the defect by approximation of the edges using transfascial sutures and place an IPOM mesh as augmentation of the sutured abdominal wall.

This new technique, known as “IPOM plus”, was introduced by J.F. Kukleta and represents a huge step to the “abdominal wall reconstruction” as a concept, restoring the abdominal wall functionality, decreasing the rate of recurrences and others complications (postoperative seroma, bulging etc)(2).

Of course, suturing the defect involves a

positive parietal tension, which should not be over than “physiological tension”. I highlight that “tension free” concept is proper to inguinal hernia repair or in ventral hernia repair when the aim is not restoration of the functionality of abdominal wall but only reducing the herniated viscera and their intraabdominal contention (3).

Rives-Stoppa technique is the gold standard in open ventral hernia repair. Respecting Rives-Stoppa principle Marc Miserez published the first MIS TEP ventral hernia repair (4); he was followed successfully by Wolfgang Reinpold with his EMILOS technique (Endoscopic Mini/Less Open Sublay) (5).

The limit of these procedures is the width of the defect; it is clear that a defect larger than 10 cm [W3 in EHS classification (6)], couldn't be sutured without some additional surgical gesture specifically to abdominal wall reconstruction, as component separation.

Combining the Jorge Daes's technique - eTEP approach (enhanced view total extra-peritoneal approach) (7) with transversus abdominis release (TAR) principles describes by Yuri Novitsky (8), Igor Belyansky has succeeded the first endoscopic Rives-Stoppa

procedure (eTEP approach): restoration of linea alba and placing a large polypropylene mesh into the retrorectus space (sublay)(9).

Method

Surgical Technique Description

The key stages are:

1. Developing the retrorectus space (left or right, it depends where the defect is located: in the lower part or in the upper part of the abdomen).
2. Crossover the midline staying extraperitoneal and opening the controplateral posterior rectus sheath.
3. Dissection of the entire retrorectus space left and right, connected after crossing the midline and incising the posterior rectus sheaths on their medial edge, and reducing the hernia.
4. Closure the posterior fascial layer defect.
5. Closure the anterior fascial layer defect (restoring linea alba).
6. Mesh placement into the retrorectus space.
7. Exuflation.

1. Developing the retrorectus space (Fig. 1)

We can do that using a balloon trocar or an optic trocar which is inserted into the

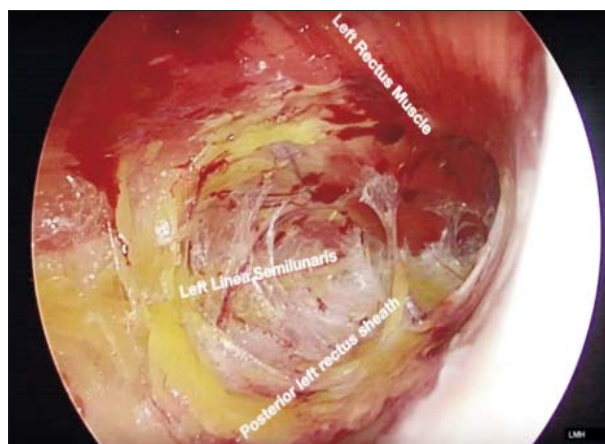


Figure 1. Development of the retrorectus space

rectus sheath under the muscle. After dissecting the retrorectus space we inflate CO₂ in this room, and then, we insert the ports just medially to the semilunaris line.

Important! Introducing the ports laterally to the semilunaris line (outside to the rectus sheath) means penetration of the (uninflated) peritonealcavity and major risk to injure the viscera!

Depending of the location of the defect, we will start on the left if the defect is inferiorly and on the right if the defect is upper the umbilicus (*Fig. 2*).

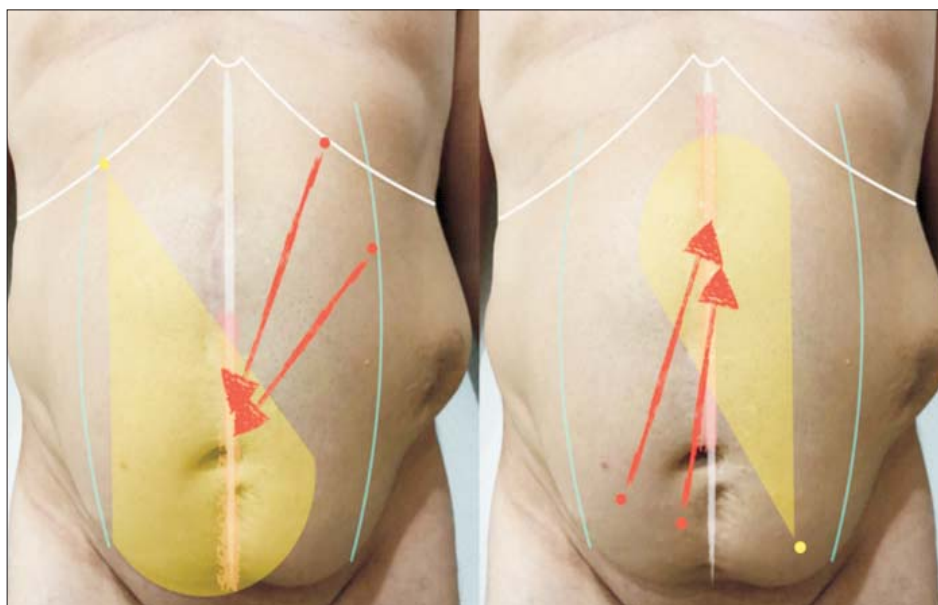


Figure 2. Port placement

2. Crossover the midline staying extraperitoneal and opening the contralateral posterior rectus sheath

Crossing the midline to the contralateral retrorectus space is the second step of the operation and it must be totally extraperitoneal (TEP), anterior to the falciform ligament, when we start from the left to the right (the defect is in the lower abdomen) and respectively anterior to the umbilical ligament, when the crossing start from the right to the left, inferiorly to the umbilicus (the defect is supraumbilical) (*Fig. 3*).

3. The incision of the posterior sheaths on their medial edges creates

The incision of the posterior sheaths on their medial edges conducts to a common large retro-muscular space (under the rectus muscles left and right) linked by the preperitoneal bridge represented by the falciform ligament and/or umbilical ligament. The retrorectus dissection is limited laterally by the semilunar lines, where the neurovascular bundles pass through posterior sheath to the rectus muscles (*Fig. 4*).

4. Closure the posterior fascial layer defect

This posterior layer (the left and the right posterior rectus sheath and the peritoneal bridge between them – the sac, the falciform ligament, the umbilical ligament) is not a layer of resistance. Its integrity is necessary to have a barrier between the mesh and the viscera (*Fig. 5*).

5. Restoration of the linea alba

Restoration of the linea alba is done by suturing on the midline the anterior sheaths of the rectus muscles. This step is performed using a barbed 0 suture, unresorbable. This suture is possible if we reduce the pressure of insufflation to 5-6 mmHg when we pull the stitch (*Fig. 6*). If the width of the defect is larger than 7 – 8 cm, probably it will be impossible to approximate the edges of the defect. One of the big advantage of this procedure is that the surgeon can adapt his attitude to an unexpected intraoperative situation – the

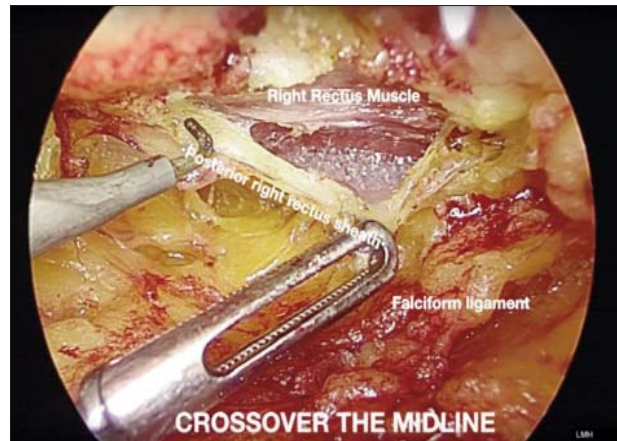


Figure 3. Cross the midline anteriorly to the falciform ligament

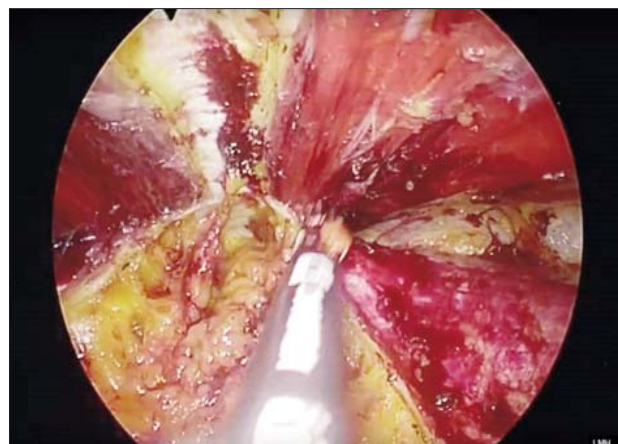


Figure 4. Retrorectus dissection

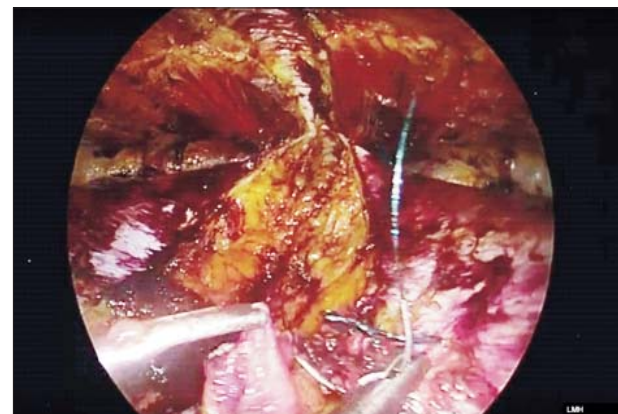


Figure 5. Closure of the defect in the posterior layer

dissection could be enlarged laterally to the semilunar lines, doing TAR.

Incision of the posterior lamella of internal

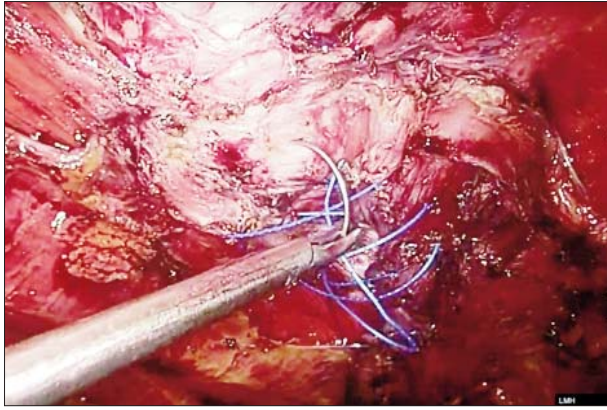


Figure 6. Restoration of the linea alba

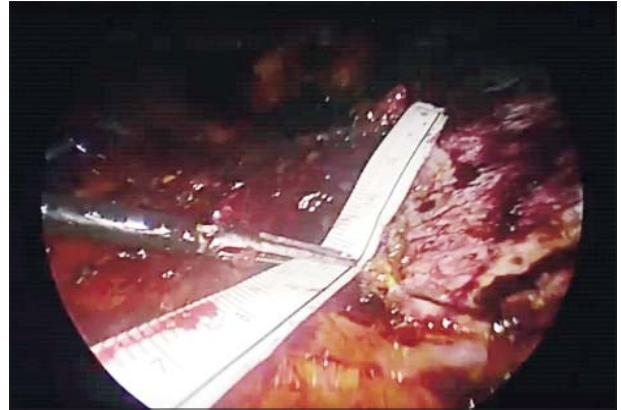


Figure 7. Measurement of the prosthesis area

oblique fascia 1 cm medially to the semilunaris line, will discover the transversus abdominis (TA) muscle.

Transection of the TA and posterior component separation which can be done laterally up to the psoas muscle, allows medial mobilisation of the musculo-fascial edges; in this way can be closed the large defects, width > 15 – 20 cm (10).

6. Mesh placement into the retrorectus space

The mesh placement into the retrorectus space will be done after measurement of the entire area which will be covered by the mesh (Fig. 7).

Important! The surface covered by the mesh is not the surface of the defect; it is the entire dissected area.

The mesh has to be well flat on the posterior layer (Fig. 8).

I used to fix the mesh with –CN glue. One of the principle of the operation is minimizing mesh fixation without compromising the results (11).

Now we consider that the fixation is not necessary, except the situation of suprapubic defect, when the mesh has to be fixed on the Cooper ligaments.

7. Exuflation

Slow exuflation, under direct vision, allows maintaining the mesh in a correct position.

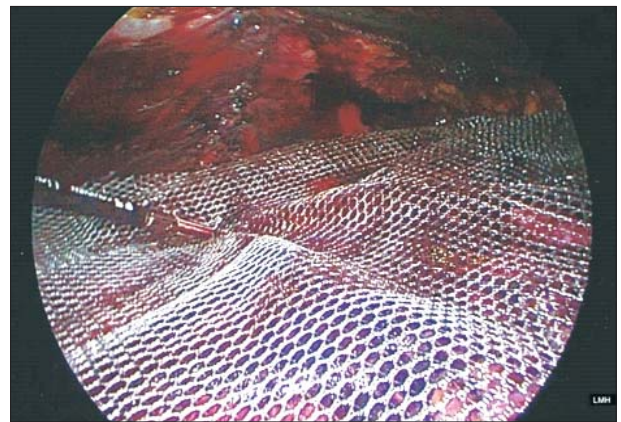


Figure 8. Mesh placement

Results. Conclusions

- Knowing the anatomy is a must. During the dissection it is important to recognise and avoid injury of the neuro- and vascular elements (inferior epigastric pedicles, intercostal neurovascular bundles) and fascial structures, as linea semilunaris. Preservation of neurovascular supply leads to maintenance of native rectus function and thus a more robust and functional repair (12). Also injury of the semilunaris line causes an irreversible destabilisation of the abdominal wall.
- Restoration of linea alba (the “central tendon of the abdomen”) remains the goal of abdominal wall reconstruction; it

improve isokinetic and isometric function of the abdominal wall and ultimately quality of life (11).

- Mesh placement outside of abdominal cavity represents a huge advantage, avoiding the contact between the mesh and the viscera (with the all late consecutives complications) and, on the other hand, reducing the cost (quite high cost of dual meshes and fixation devices).
- The early results of this procedure were published in Surgical Endoscopy (14) and show the superiority then “traditional” laparoscopic approach (IPOM) regarding pain, recovery, recurrence, cost.
- My personal experience is 63 cases in the last 18 months. The median hospitalisation was 1day (1 – 9); the follow up was at 2 months, 6 months, 12 months (at this time we recommend also a CT scan) and 1 case claimed chronic pain. Until now no one has recurrence.

Conflict of Interest: none

References

1. LeBlanc K, Allain Brent W Jr. Laparoscopic repair of ventral wall abdominal hernia - the 3rd Edition: Prevention & Management.” (Online). Available: http://laparoscopy.blogs.com/prevention_manage-ment_3/2010/10/laparoscopic-repair-of-ventral-wall-abdominal-hernia.html. (Accessed: 02-Sep-2017).
2. Bittner R, Bingener-Casey J, Dietz U, Fabian M, Ferzli GS, Fortelny RH, et al. Guidelines for laparoscopic treatment of ventral and incisional abdominal wall hernias (International Endohernia Society (IEHS)-part 1. Surg Endosc. 2014;28(1):2-29. Epub 2013 Oct 11.
3. Rosen MJ. Atlas of abdominal wall reconstruction. Elsevier, 2012.
4. Miserez M, Penninckx F. Endoscopic totally preperitoneal ventral hernia repair. Surg Endosc. 2002;16(8):1207-13. Epub 2002 Apr 9.
5. Schwarz J, Reinhold W, Bittner R. Endoscopic mini/less open sublay technique (EMILOS)-a new technique for ventral hernia repair. Langenbecks Arch Surg. 2017;402(1):173-180.
6. Muysoms FE, Miserez M, Berrevoet F, Campanelli G, Champault GG, Chelala E, et al. Classification of primary and incisional abdominal wall hernias. Hernia. 2009;13(4):407-14.
7. Daes J. The enhanced view-totally extraperitoneal technique for repair of inguinal hernia. Surg Endosc. 2012;26(4):1187-9. Epub 2011 Oct 25.
8. Novitsky YW, Elliott HL, Orenstein SB, Rosen MJ. Transversus abdominis muscle release: a novel approach to posterior component separation during complex abdominal wall reconstruction. Am J Surg. 2012;204(5):709-16.
9. Belyansky I, Zahir HR, Park A. Laparoscopic Transversus Abdominis Release, a Novel Minimally Invasive Approach to Complex Abdominal Wall Reconstruction. Surg Innov. 2016; 23(2): 134-41. Epub 2015 Nov 24.
10. Oprea V, Radu VG, Moga D. Transversus Abdominis Muscle Release (TAR) for Large Incisional Hernia Repair. Chirurgia (Bucur). 2016;111(6):535-540.
11. Zahir HR, Belyansky I. Evidence-Based Optimal Fixation During Laparoscopic Hernia Repair: Sutures, Tacks, and Glues. In Hernia Surgery, Cham: Springer International Publishing; 2016. p. 287–295.
12. Novitsky YW. Hernia surgery: current principles. Springer.
13. Criss CN, Petro CC, Krpata DM, Seafiler CM, Lai N, Fiutem J, et al. Functional abdominal wall reconstruction improves core physiology and quality-of-life. Surgery. 2014;156(1):176-82.
14. Belyansky I, Daes J, Radu VG, Balasubramanian R, Reza Zahir H, Weltz AS, et al. A novel approach using the enhanced-view totally extraperitoneal (eTEP) technique for laparoscopic retromuscular hernia repair. Surg Endosc. 2018;32(3):1525-32. Epub 2017 Sep 15.