

## The Role of Esophageal Stenting in the Management of Anastomotic Leaks after Esophageal and Esophago-Gastric Cancer Resections. Literature Review

Cristian Gelu Rosianu<sup>1</sup>, Petre Hoara<sup>2,3</sup>, Alkadour Abdullah<sup>2,3</sup>, Florin Achim<sup>2,3</sup>, Rodica Birla<sup>2,3</sup>, Silviu Constantinoiu<sup>2,3</sup>

<sup>1</sup>Department of Gastroenterology, St. Mary Clinical Hospital, Bucharest, Romania

<sup>2</sup>General Surgery Department, Carol Davila University of Medicine and Pharmacy, Bucharest, Romania

<sup>3</sup>Department of General and Esophageal Surgery, Center of Excellence in Esophageal Surgery, St. Mary Clinical Hospital, Bucharest, Romania

### \*Corresponding author:

Rodica Daniela Birla, MD  
Carol Davila University of Medicine  
and Pharmacy Bucharest, Romania  
General Surgery Department  
9 Constructorilor Bd, G1 Ap18  
Bucharest 060502, Romania  
E-mail: [birlarodica@yahoo.com](mailto:birlarodica@yahoo.com)  
ORCID ID : 0000-0002-8799-4524

### Rezumat

*Rolul stentării endoscopice în managementul fistulelor anastomotice după rezecțiile esofagiene pentru neoplasm esofagian și de joncțiune eso-gastrică*

**Scop:** Fistulele de anastomoză post neoplasm esofagian operat, rămân o provocare atât pentru medicul chirurg cât și pentru medicul gastroenterolog. Scopul studiului este de a evidenția rolul stentării esofagiene în cadrul managementului fistulei post-esofagectomie pentru afecțiuni maligne.

**Materiale și Metode:** Am trecut în revistă literatura disponibilă despre tratamentul endoscopic al fistulelor de anastomoză esofagiană, în special articolele despre stentarea endoscopică în managementul acestei complicații. Bazele de date Pubmed și ClinicalKey au fost căutate folosind cuvinte cheie cum ar fi fistulele de anastomoză esofagiană, stenturile metalice auto-expandibile total acoperite, neoplasmul esofagian. Literatura relevantă a fost revizuită și inclusă în articol.

**Rezultate și Concluzii:** Montarea de stenturi autoexpandabile în fistulele de anastomoză esofagiană, reprezintă o metodă eficientă de tratament atât pentru închiderea fistulei cât și în controlul sepsisului. Morbiditatea și mortalitatea asociate acestei metode de tratament pot fi importante.

**Cuvinte cheie:** fistula esofagiană, neoplasm esofagian, stent metalic esofagian

Received: 14.02.2022

Accepted: 05.04.2022

## Abstract

**Introduction:** Anastomotic fistulas after surgery for esophageal cancer, remain a challenge for both the surgeon and the gastroenterologist. The aim of the study is to highlight the role of esophageal stenting in the management of leaks after esophagectomy for malignancies.

**Materials and Methods:** We reviewed the available literature on the endoscopic treatment of esophageal anastomotic leaks, especially articles on endoscopic stenting in the management of this complication. Pubmed and ClinicalKey databases were searched using keywords such as esophageal anastomotic leaks, fully covered self-expanding metal stents, esophageal neoplasm. The relevant literature has been reviewed and included in the article.

**Results and Conclusions:** The insertion of self-expanding stents in the fistulas of the esophageal anastomosis, represents an efficient method of treatment both for the closure of the fistula and in the control of sepsis. The morbidity and mortality associated with this method of treatment may be significant.

**Key words:** esophageal fistula, esophageal neoplasm, esophageal metal stent

## Introduction

The most common methods used for esophageal resection for malignancies are the McKeown and Ivor Lewis techniques, with a high morbidity and mortality rate due to the complexity of the procedure.

Thus, the most frequent postoperative complications encountered following these surgical techniques are pulmonary complications (18.7%), cardiac arrhythmias (14.1%), anastomotic fistula (14.1%), vocal cord paralysis (9.4%), stenosis of the gastric tube (4.7%) and acute renal failure (4.7%) (1).

Esophageal anastomosis fistulas continue to be an important postoperative complication among patients requiring surgical procedures for esophageal and eso-gastric junction cancer (2).

Prompt diagnosis, early closure of the fistula and treatment of sepsis are the key in the management of this postoperative complication (3).

Over the last decade, self-expanding metal stents have shown promising results in the temporary or permanent closure of fistulas. The use of endoscopic methods to close these postoperative parietal defects, which appeared after the surgical resection of certain segments of the digestive tract affected by

neoplastic diseases, has proven effective in some studies. As a result, endoscopic stenting at the level of the esophageal anastomosis can lead to successful control of the infectious process generated by the fistula together with obtaining a stable clinical status of the patient, allowing oral intake and closure of the fistula (4).

Esophageal anastomotic fistulas cause high morbidity, prolong the hospitalization time of patients, even leading to their death in some cases (5).

Recently, a great progress has been made regarding the surgical methods, intraoperative fluid administration and preoperative care.

In the case of esophageal stenting, for anastomotic leak, some studies in the literature indicate an efficiency of closing the fistula of 81% (6).

### *Methods for Preventing Fistulas of Esophageal Anastomosis*

The use of prophylactic interventions to reduce the impact and / or incidence of anastomotic fistulas is essential. These prevention methods include (7):

- Ischemic preconditioning of the gastric tube;

- Intraoperative evaluation of gastric tube vascular supply to determine the site of future anastomosis;
- Evaluation of the anastomotic partner (stomach, jejunum or colon);
- Consolidation of the anastomosis with the omental pedicle;
- Intraoperative placement of a perianastomotic drainage tube.

The Consensus Group on Esophagectomy Complications (ECCG) has developed a classification that includes the following types of fistulas and their management according to their type (8):

- Type I- anastomotic fistulas that require conservative management;
- Type II - anastomotic fistulas that require interventional therapy, but not surgery (radiological drainage, endoscopic stenting, etc.);
- Type III - anastomotic fistulas that require surgery.

#### *Indications for Endoscopic Stenting for Esophageal Anastomosis Fistulas*

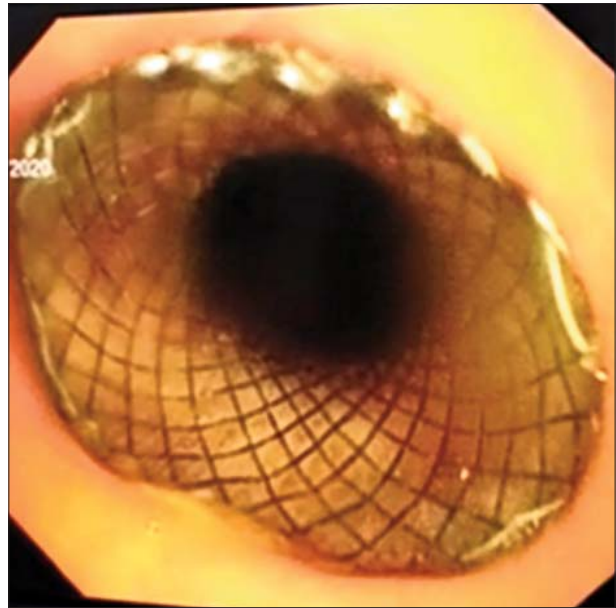
The most common used methods of endoscopic treatment, depending on the size of the fistula, are: fibrin glue injection, clipping, stenting, or vacuum therapy (9).

Esophageal stenting is one of the most effective endoluminal therapy techniques, used to treat anastomotic leaks (Figs. 1, 2).

In the literature there are studies in which some criteria have been proposed for the placement of stents in fistulas of esophageal anastomosis: the anastomotic defect should be less than 70% of the circumference, the absence of ischemic lesions or necrosis at the level of the anastomotic partners and the presence of perianastomotic drainage (10).

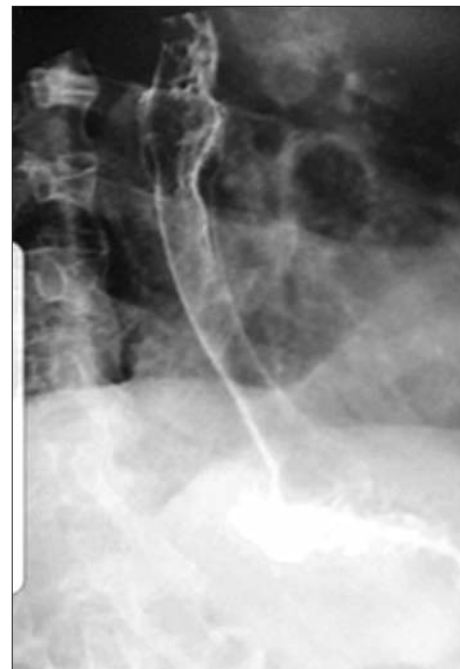According to studies in the literature, most esophageal anastomotic leaks appear between the 3<sup>rd</sup> and 5<sup>th</sup> postoperative day and endoscopic management of the fistula is the most widely method used for treatment (11).

In the case of esophageal fistulas with anastomosis performed at the cervical level, stenting is possible when the edge of the



**Figure 1.** Endoscopic aspect of a fully covered esophageal stent, used for the treatment of an eso-gastric anastomotic leak (Surgical archive of "Sf. Maria" Clinical Hospital, Bucharest)

proximal end of the stent can be placed at least 2 cm distal from the upper esophageal sphincter.



**Figure 2.** Contrast study showing fully covered esophageal stent used for sealing an eso-gastric anastomotic leak (Surgical archive of "Sf. Maria" Clinical Hospital, Bucharest)

According to the literature, the average period of maintaining an expandable stent, mounted for the fistula of esophageal anastomosis, is between 6 and 8 weeks (12).

In addition to the endoscopic insertion of the esophageal stent to prevent sepsis, there are complementary therapeutic methods that promote healing, such as the gastric / duodenal feeding tube, proper drainage of the infected collection, and antibiotics (13).

The classification of esophageal fistulas in surgical and gastroenterological practice, are the following:

- Cervical esophageal fistula;
- Thoracic esophageal fistula;
- Fistula in the distal esophagus.

The insertion of an esophageal stent for postoperative esophageal anastomotic leak, should be performed as soon as possible after the diagnosis of fistula.

In literature studies, the diameters of esophageal stents vary between 20 mm and 36 mm, with the most used types being with a diameter of 20 mm and 28 mm (14).

Fully covered esophageal stents are preferred: the majority of Nitinol alloy.

According to a study performed on a group of patients with esophageal anastomotic fistula, the main contraindications in the use of endoscopic stents are: complete dehiscence of esophageal anastomosis, eso-bronchial and eso-tracheal fistula (15).

In another study, the contraindications for mounting self-expanding esophageal stents in fistulas of esophageal anastomosis are: severe coagulation disorders, severe cardio-pulmonary disorders and acute surgical abdomen (16).

The factors that contribute to the success of self-expanding esophageal stent are: defect size, fistula etiology, time between diagnosis of the complication and stent placement and, last but not least, the severity of sepsis .

The use of self-expanding esophageal stents, for the management of esophageal anastomotic fistulas, is a method with proven efficiency and with a low rate of major complications (17).

### *Complications of Esophageal Stenting in Anastomosis Fistulas*

The main complications in esophageal stenting according to the latest literature data are: retrosternal pain, pharyngeal sensation, aspiration pneumonia, stent migration, esophageal perforation and digestive hemorrhage 1%. In the case of self-expanding esophageal stents, mounted in the cervical esophagus, the risk of complications is higher than in the case of stenting of the middle or lower esophagus (18).

According to other studies in the literature, the migration of stent inserted for esophageal anastomotic fistula varies between 10-35% (19,20,21).

To prevent stent migration, it is recommended to mount a larger caliber stent, secure the proximal end of the stent with metal clips or endoscopic esophageal suture (22)

According to the literature, severe complications after esophageal stenting can lead to mortality in 10% of the cases. Associated complications after esophageal stenting that may cause this increased mortality are: esophageal perforation, gastrointestinal bleeding, or stent migration, that causes digestive occlusion (23,24,25)

### **Conclusions**

Anastomotic fistulas after esophagectomy for esophageal/eso-gastric cancer are linked to increased morbidity and even mortality.

Regardless of the factors leading to fistula, or the patient's clinical condition, the therapeutic management of such cases consists of: resuscitation if necessary, broad-spectrum antimicrobial therapy, drainage of the infected collections and control of the source, in order to seal the fistula that led to those septic complications.

The benefits of esophageal stenting in the management of anastomotic leaks, include sealing the fistula and allowing oral nutrition, leading to definitive healing.

## Conflict of Interest

The authors declare no conflicts of interests.

## References

- D'Cunha J, Rueth NM, Groth SS, Maddaus MA, Andrade RS. Esophageal stents for anastomotic leaks and perforations. *J Thorac Cardiovasc Surg.* 2011;142(1):39-46.e1
- Van Halsema EE, Kappelle WFW, Weusten BLAM, Lindeboom R, van Berge Henegouwen MI, Fockens P, et al. Stent placement for benign esophageal leaks, perforations, and fistulae: a clinical prediction rule for successful leakage control. *Endoscopy.* 2018;50(2):98-108.
- Nguyen NT, Rudersdorf PD, Smith BR, Reavis K, Nguyen XM, Stamos MJ. Management of gastrointestinal leaks after minimally invasive esophagectomy: conventional treatments vs. endoscopic stenting. *J Gastrointest Surg.* 2011; 15(11):1952-60.
- Dasari BV, Neely D, Kennedy A, Spence G, Rice P, Mackle E, et al. The role of esophageal stents in the management of esophageal anastomotic leaks and benign esophageal perforations. *Ann Surg.* 2014;259(5):852-60.
- Famiglietti A, Lazar JF, Henderson H, Hamm M, Malouf S, Margolis M, et al. Management of anastomotic leaks after esophagectomy and gastric pull-up. *J Thorac Dis.* 2020;12(3):1022-1030.
- Hindy P, Hong J, Lam-Tsai Y, Gress F. A comprehensive review of esophageal stents. *Gastroenterol Hepatol (N Y).* 2012;8(8):526-34.
- Salminen P, Gullichsen R, Laine S. Use of self-expandable metal stents for the treatment of esophageal perforations and anastomotic leaks. *Surg Endosc.* 2009;23(7):1526-30.
- Yuan Y, Duranceau A, Ferraro P, Martin J, Liberman M. Vascular conditioning of the stomach before esophageal reconstruction by gastric interposition. *Dis Esophagus.* 2012;25(8):740-9.
- Lee S, Ahn JY, Jung HY, Lee JH, Choi KS, Kim DH, et al. Clinical Outcomes of Postoperative Upper Gastrointestinal Leakage According to Treatment Modality. *Dig Dis Sci.* 2016;61(2):523-32.
- Zisis C, Guillain A, Heyries L, Lienne P, D'Journo X B, Doddoli C, et al. Stent placement in the management of oesophageal leaks. *Eur J Cardiothorac Surg.* 2008;33(3):451-6.
- Kähler G. Anastomotic Leakage after Upper Gastrointestinal Surgery: Endoscopic Treatment. *Visc Med.* 2017;33(3):202-206.
- Low DE, Alderson D, Ceconello I, Chang AC, Darling GE, D'Journo XB, et al. International Consensus on Standardization of Data Collection for Complications Associated With Esophagectomy: Esophagectomy Complications Consensus Group (ECCG) *Ann Surg.* 2015;262:286-294.
- El Hajj II, Imperiale TF, Rex DK, Ballard D, Kesler KA, Birdas TJ, et al. Treatment of esophageal leaks, fistulae, and perforations with temporary stents: evaluation of efficacy, adverse events, and factors associated with successful outcomes. *Gastrointest Endosc.* 2014;79(4):589-98.
- Kucukay F, Okten RS, Parlak E, Disibeyaz S, Ozogul Y, Bostanci EB, et al. Self-expanding covered metallic stent treatment of esophagojejunostomy fistulas. *Abdom Imaging.* 2013;38(2):244-8.
- Smith EA, Daly SC, Smith B, Hinojosa M, Nguyen NT. The Role of Endoscopic Stent in Management of Postesophagectomy Leaks. *The American Surgeon.* 2020;86(10):1411-1417.
- Bor R, Fábrián A, Bálint A, Farkas K, Szűcs M, Milassin Á, et al. Endoscopic management of complications of self-expandable metal stents for treatment of malignant esophageal stenosis and tracheoesophageal fistulas. *Therap Adv Gastroenterol.* 2017;10(8):599-607.
- Pinto E R, Pereira P, Ribeiro A, Moutinho-Ribeiro A, Lopes S, Macedo G. Self-expanding metal stents in postoperative esophageal leaks. *Rev Esp Enferm Dig.* 2016;108(3):133-7
- Wang MQ, Sze DY, Wang ZP, Wang ZQ, Gao YA, Dake MD. Delayed complications after esophageal stent placement for treatment of malignant esophageal obstructions and esophagorespiratory fistulas. *J Vasc Interv Radiol.* 2001;12(4):465-74.
- Lorentz T, Fok M, Wong J. Anastomotic leakage after resection and bypass for esophageal cancer: Lessons learned from the past. *World J Surg.* 1989;13:472-477.
- Schaheen L, Blackmon SH, Nason KS. Optimal approach to the management of intrathoracic esophageal leak following esophagectomy: a systematic review. *Am J Surg.* 2014;208(4):536-43.
- Barkley C, Orringer MB, Iannettoni MD, Yee J. Challenges in reversing esophageal discontinuity operations. *Ann Thorac Surg.* 2003;76(4):989-94
- Bohle W, Louris I, Schaudt A, Koeninger J, Zoller WG. Predictors for Treatment Failure of Self-Expandable Metal Stents for Anastomotic Leak after Gastro-Esophageal Resection. *J Gastrointest Liver Dis.* 2020;29(2): 145-149.
- van Boeckel PG, Dua KS, Weusten BL, Schmits RJ, Surapaneni N, Timmer R, et al. Fully covered self-expandable metal stents (SEMS), partially covered SEMS and self-expandable plastic stents for the treatment of benign esophageal ruptures and anastomotic leaks. *BMC Gastroenterol.* 2012;12:19.
- Hoepfner J, Kulemann B, Seifert G, Marjanovic G, Fischer A, Hopt UT, et al. Covered self-expanding stent treatment for anastomotic leakage: outcomes in esophagogastric and esophagojejunal anastomoses. *Surg Endosc.* 2014; 28(5):1703-11.
- Feith M, Gillen S, Schuster T, Theisen J, Friess H, Gertler R. Healing occurs in most patients that receive endoscopic stents for anastomotic leakage; dislocation remains a problem. *Clin Gastroenterol Hepatol.* 2011;9(3):202-10.