

Robotic Surgery a Step Forward in Standardization of Hysterectomy in Patients with Deep Infiltrating Endometriosis

Elvira Bratilă^{1,2*}, Diana Comandașu^{1,2}, Cătălin Coroleucă², Andrei Manu², Petre Bratilă³

¹Department of Obstetrics Gynecology, "Carol Davila" University of Medicine and Pharmacy, Bucharest, Romania

²Department of Obstetrics Gynecology, "Prof. Dr. Panait Sirbu" Clinical Obstetrics and Gynecology Hospital, Bucharest, Romania

³Department of Obstetrics Gynecology, Euroclinic Hospital, Bucharest, Romania

*Corresponding author:

Professor Elvira Bratilă
Department of Obstetrics Gynecology
"Carol Davila" University of Medicine
and Pharmacy, Bucharest, Romania
Department of Obstetrics Gynecology
"Prof. Dr. Panait Sirbu" Clinical
Obstetrics and Gynecology Hospital
Bucharest, Romania
E-mail: elvirabarbulea@gmail.com

Rezumat

Chirurgia robotică, un pas înainte în standardizarea histerectomiei la pacientele cu endometrioză profund infiltrativă

Introducere: Histerectomia în cazurile cu endometrioză infiltrativă profundă (DIE) reprezintă o provocare chirurgicală reprezentată de lipsa standardizării, provocând dificultăți tehnice sau rezecție incompletă a leziunilor de endometrioză profundă. *Scop:* Acest articol încearcă să utilizeze conceptul de compartiment virtual lateral și antero-posterior în standardizarea histerectomiei robotice (RH) în cazurile de endometrioză profundă cu leziuni parametriale conform clasificării ENZIAN.

Material și metodă: Am colectat date de la 81 de paciente la care s-a efectuat histerectomie totală și excizie "en bloc" a leziunilor de endometrioză profundă pe cale robotică.

Rezultate: Intervenția a fost realizată prin tehnica histerectomiei retroperitoneale, standardizarea acesteia în funcție de clasificarea ENZIAN fiind descrisă pas cu pas. Histerectomia robotică realizată a inclus întotdeauna îndepărtarea en bloc a uterului, anexelor, parametrului posterior și anterior, la nivelul căruia au fost găsite leziuni de endometrioză profundă și treimea superioară a vaginului cu toate leziunile de endometrioză profundă de la nivelul mucoasei vaginale.

Discuție: Histerectomia și disecția parametrială trebuie făcute în funcție de dimensiunea și localizarea nodulului de endometrioză profundă. Scopul histerectomiei pentru DIE este de a elibera uterul și țesutul endometriotoc fără complicații intra sau post-operatorii.

Concluzie: Histerectomia "en-bloc" împreună cu noduli endometriotici, în care rezecția parametrială este adaptată în funcție

Received: 10.01.2023
Accepted: 25.02.2023

de leziuni, este o metodă optimă, deoarece pierderile de sânge, timpul operator și complicațiile intraoperatorii sunt reduse comparativ cu alte metode.

Cuvinte cheie: chirurgie robotică, endometrioză infiltrativă profundă, scor ENZIAN, histerectomie robotică

Abstract

Introduction: Hysterectomy in cases with deep infiltrating endometriosis (DIE) poses a particular challenge represented by the lack of standardization, causing technical difficulties or incomplete resection of the deep endometriosis lesions. Aim: This article attempts to use the concept of lateral and antero-posterior virtual compartments in the standardization of robotic hysterectomy (RH) in cases of deep parametrial lesions according to ENZIAN classification.

Material and method: We collected data from 81 patients who underwent total hysterectomy and en bloc excision of the endometriotic lesions by robotic surgery.

Results: Excision was realized by the technique of retroperitoneal hysterectomy, its standardization depending on the ENZIAN classification being described step by step. Tailored robotic hysterectomy always included the en-block removal of uterus, adnexa, and posterior and anterior parametria, which included endometriotic lesions and the upper one-third of the vagina with all endometriotic lesions of posterior and lateral vaginal mucosa.

Discussion: The hysterectomy and parametrial dissection must be done according to the size and location of the endometriotic nodule. The goal of hysterectomy for DIE is to release the uterus and the endometriotic tissue without risks of complication.

Conclusion: "En-bloc" hysterectomy together with endometriotic nodules, where the parametrial resection is tailored according to the lesions, is an optimum method, because the blood loss, operative time, and intraoperative complications are reduced comparing with other methods.

Key words: robotic surgery, deep infiltrating endometriosis, ENZIAN score, tailored robotic hysterectomy

Introduction

One of the most frequent indicated procedures in gynaecological surgery is represented by hysterectomy (1). This procedure can be achieved through abdominal approach (laparotomy) or by minimally invasive techniques (vaginal approach, laparoscopy or robotic surgery) (2). The gold standard for the treatment of DIE is represented by minimally invasive surgery.

Hysterectomy can be offered as a treatment option in selected cases of DIE for patients in which other treatments did not show any significant improvement in symptoms and

when family planning is completed (3,4). We must take into account that many of these patients will exhibit parametrial lesions that require a nerve-sparing surgical approach in order to preserve the important pelvic structures.

The benefits of using robotic surgery can be seen in complex cases of deep infiltrating endometriosis that require ureterolysis, identification of the uterine artery in lateral parametrium and nerve-sparing resection in the posterior compartment (with preservation of the hypogastric and splanchnic nerves) (5). The extent of the lesions have to mapped at the beginning of the intervention in order

to remove all the endometriotic tissue thus creating the need for the development of the avascular spaces, identification and preservation of the pelvic autonomous structures (inferior mesenteric plexus and superior hypogastric plexus), parametrectomy (lateral or posterior), colectomy or bowel resection.

One of the unsolved aspects of hysterectomy in cases with deep endometriosis (DIE) is represented by the lack of standardization. The consequences of the lack of standardization can cause difficulties in the hysterectomy technique or to perform a hysterectomy without improvement of symptoms such as pelvic-abdominal pain and dysmenorrhea (6). Hysterectomy can be associated with perioperative risk, however in the literature there have been studies that describe a four fold increase of complications in patients with deep infiltrating endometriosis (7,8). A good understanding of the evolution of symptoms over time after the radical treatment for DIE and close follow-up is needed in order to offer the patient a tailored solution in relation to the lesions that are present.

Robotic surgery was introduced in the armamentarium of the gynaecologic surgery in order to overcome some of drawbacks of laparoscopy and has benefits regarding ergonomics, inspection of deep pelvis with three-dimensional vision as well as improved dexterity due to instrument articulation (9).

In this article, we attempted to use the concept of lateral and antero-posterior virtual compartments in order to standardize robotic hysterectomy in cases of deep parametrial lesions according to ENZIAN classification (10). Standardization of 'en bloc' resection of the deep endometriosis, including also the uterus, is based on the anatomy of the supporting system of the pelvic organs and its virtual avascular compartments between the supporting system. The aim of the study is to present the surgical technique used in relation to anatomical site of the endometriotic lesions and to assess the long-term effects on the rate of dysmenorrhea, dyspareunia and chronic pelvic pain.

Materials and Methods

We collected data for patients who underwent nonconservative robotic surgery for deep infiltrating endometriosis during the years 2017 through 2019 at the Endomedicare Academy in Monza Hospital. Because of the descriptive approach of this study, Institutional Review Board approval was not requested. All patients included in the study were informed and signed the informed consent to be included in the study and they all gave their informed consent for surgery consisting of robotic radical en bloc hysterectomy and colorectal resection and removal of all macroscopic lesions, after being informed about the risk of postoperative dysuria and protective colostomy. Criteria for inclusion in the study were (1) endometriosis that involved the rectovaginal or vesicouterine septum, parametria, rectosigmoid (2) symptomatic recurrences after conservative surgical procedures and medical treatment with continuous estrogen-progestins and progestogens, (3) no desire for obtaining a pregnancy, and (4) symptomatic endometriosis (dysmenorrhea, dyspareunia, pelvic pain).

All patients included in this study completed a questionnaire regarding preoperative endometriosis symptoms and quality of life (SF-36 Questionnaire) and 24 months postoperative symptoms in order to evaluate the impact of symptoms on life before and after robotic hysterectomy with excision of the endometriotic lesions. Quality of life assessment in patients with deep endometriosis is an integral part of both preoperative and postoperative assessment, in order to objectify the benefit of surgery.

The data was evaluated on an intention-to-treat basis and the SPSS v26 and Microsoft Excel was used. Standard deviation is quoted for our histograms. To assess the comparisons between preoperative and postoperative scores the Student t test and Pearson correlation was performed for continuous data. For all comparisons, a $p < 0.05$ was considered to define statistical significance.

81 patients underwent robotic hysterectomy

(RH) and en bloc excision of the endometriotic. This was prospective descriptive study in order to present the steps of robotic hysterectomy (RH) in cases of deep parametrial lesions according to ENZIAN classification. All patients underwent pelvis ultrasonography and some of them magnetic resonance imaging (MRI) before surgery. All patients had multiple pelvic locations of endometriosis. All patients were operated on under general anesthesia in dorsolithotomy position. All patients were operated using the DaVinci Xi platform by the same surgical team.

We used for dissection the three from four virtually lateral compartments formed between the anterior, lateral, and posterior parametrium. “En-bloc” excision with hysterectomy of deep endometriosis lesions was done after development of avascular compartments represented by medial paravesical space and medial and/or lateral pararectal spaces. Identification of these spaces during the surgery depends on the location of deep endometriosis: into the parametrium, rectovaginal septum or rectosigmoid. Dissection in these virtual and avascular spaces decreases blood loss and allows us to identify the anatomical structures. Similar dissection is required in patients with gynaecologic malignancies; that is why the anatomical study of oncological cases were used to assess these spaces for dissection. Intraoperative observation and histopathology analysis of the excised tissue was compared with perioperative magnetic resonance imaging. Histopathological confirmation of the excised lesions was confirmed in all cases.

Technique standardisation of retroperitoneal hysterectomy was done according with the localisation of DIE in hysterectomised patients:

1. parametrial lesion (B);
2. rectosigmoidian lesions (C);
3. rectovaginal septum lesion (A) and rectosigmoidian lesion (C);
4. parametrial lesion (B) and rectosigmoidian lesion (C);
5. rectovaginal septum lesion (A), parametrial lesion (B), and rectosigmoidian lesion (C).

Regarding the surgical aspect of the hysterectomy, we used for dissection the three from four virtually lateral compartments formed between the anterior, lateral, and posterior parametrium. “En-bloc” excision with hysterectomy of deep endometriosis lesions was done after development of avascular compartments represented by medial paravesical space and medial and/or lateral pararectal spaces. Identification of these spaces during the surgery depends on the location of deep endometriosis: into the parametrium, rectovaginal septum or rectosigmoid. Dissection in these virtual and avascular spaces decreases blood loss and allows us to identify the anatomical structures. Similar dissection is required in patients with gynaecologic malignancies; that is why the anatomical study of oncological cases were used to assess these spaces for dissection.

Results

Mean age of the patients, as shown in *Table 1*, was 44.075 years (range 38-52 years). Mean body mass index (BMI) was 21.75 kg/m² (range 18.2-25.2 kg/m²). Mean operating time of the gynecological part of the operation (all but the bowel resection) is 96 minutes (\pm 18.18) while the mean operating time for the general surgery is 104.95 minutes (\pm 34.3).

The ENZIAN-Score is an instrument to classify the deep infiltrating endometriosis where the retroperitoneal part of the severe

Table 1. Characteristics of the patients. Data are given as mean \pm SD

Age (years)	44.075 \pm 4.1
BMI	21.75 \pm 2.12
Urban	72 (88.88%)
Rural	9 (11.11%)
Dysmenorrhea	80 (100%)
Deep dyspareunia	68 (83.9%)
Pelvic pain	59 (72.83%)
Mean operating time – gynecological part (min)	96 \pm 18.18
Mean operating time – general surgery part (min)	104.95 \pm 34.3
Mean blood loss (mL)	138.48 \pm 64.22
Mean hospital stay (days)	3.62 (\pm 1.18)
Follow up time (months)	24

endometriosis is focused on. In analogy to an oncological staging four different stages are pronounced. The localization and the expansion of the endometriosis nodule was

indicated to different subgroups as shown in the Fig. 1. Distribution of DIE lesions according to ENZIAN classification is shown in Table 2. Most of the endometriotic lesions

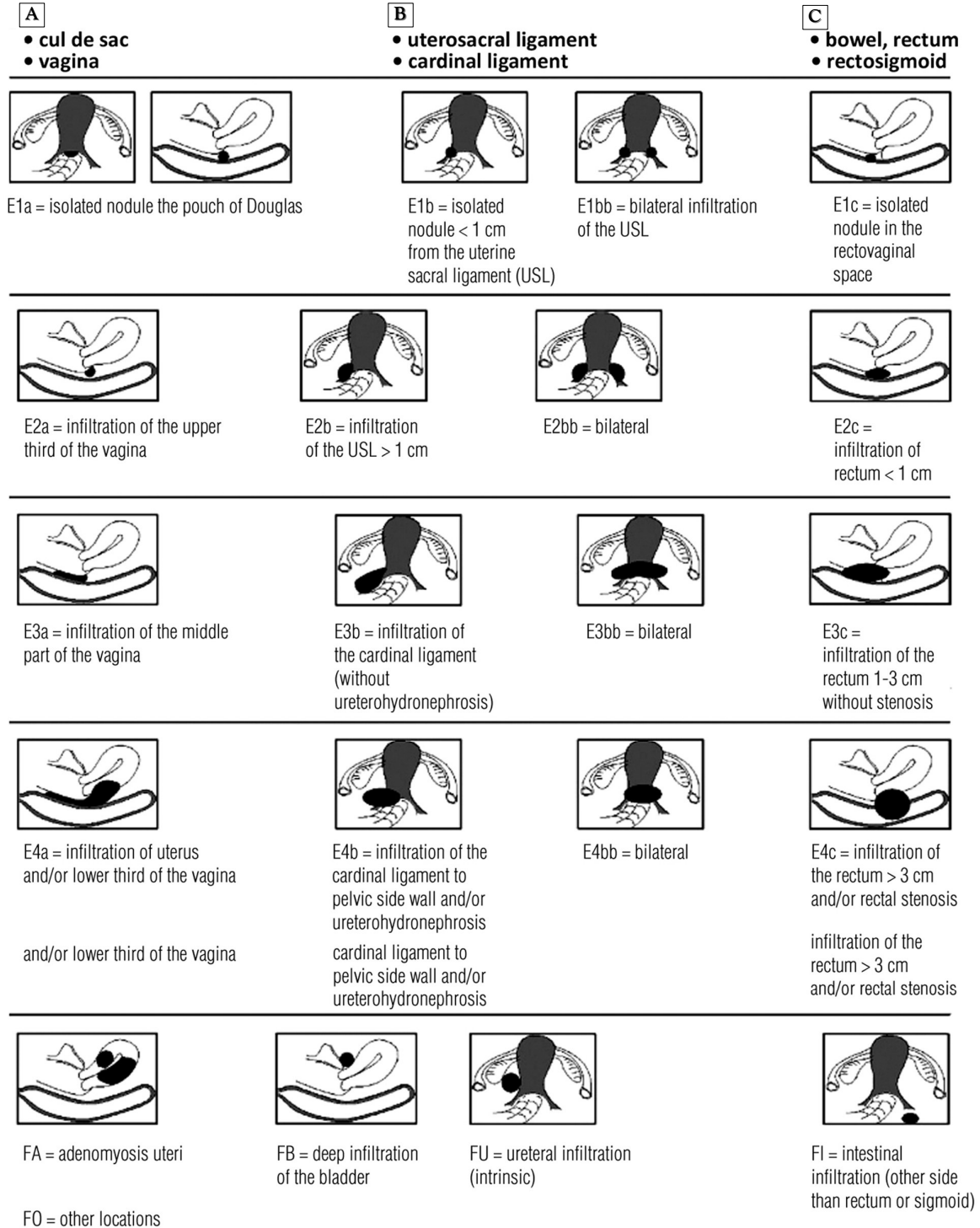


Figure 1. ENZIAN score (Tuttles F, 2005)

Table 2. Endometriotic lesions excised according to ENZIAN score

Location of DIE	ENZIAN classification	Number of lesions
Parametrial lesion - lateral or posterior parametrium	1B	26
	2B	42
	3B	12
Rectovaginal septum	1A	3
	2A	3
Rectosigmoidian lesions	1C	7
	2C	6
	3C	5
Bladder nodule	FB	3

(51.85%) where parametrial and uterosacral ligament nodules that were 1 to 3 cm in size. Three of the 29 patients (3.7 %) undergone a partial cystectomy. Eleven (13.58 %) of them had a bowel resection and seven had rectal shaving.

In all hysterectomy is realized by the technique of retroperitoneal hysterectomy. Tailored robotic hysterectomy always included the en-block removal of uterus, adnexa, and posterior and anterior parametria, which included endometriotic lesions and the upper one-third of the vagina with all endometriotic lesions of posterior and lateral vaginal mucosa. The first step of the operation was the transection of round and infundibulopelvic

ligaments that was followed by the dissection of the ureters, which was accomplished in craniocaudal direction towards the anterior parametrium, where the fascial ureteral tunnel was identified and opened with multiple bites. During this step, care was taken to include the peritoneum from which all visible endometriotic lesions were to be removed. Uterine vessels were severed at the cross-point of the ureter. The cleavage planes between the rectum and the endometriotic lesions of the Douglas pouch and rectovaginal septum were identified and dissected, which allowed the skeletonization and transection of the posterior parametria, usually the most challenging step of the operation. The posterior parametria were cut as close to the rectum as possible, and the healthy connective adipose rectovaginal tissue was reached caudally, so as

to ensure the removal of all endometriotic lesions. Finally, cardinal ligaments and the paravaginal tissue were transected until the level of posterior ablation. Partial cystectomy was performed in cases with infiltrating bladder lesions. A segmental laparoscopic bowel resection with end-to-end anastomosis was performed by a general surgeon in cases with rectosigmoid endometriosis. Rectal shaving was done in all patients with C1 intestinal nodules.

Parametrial lesions (ENZIAN B) can be located in lateral and/or posterior parametrium. Resection of the lateral parametrium DIE was done by delimitation of lateral parametrium starting dorsally from the lateral para-rectal space and then anteriorly developing the medial para-vesical space and delineating the anterior parametrium from the lateral parametrium. Entering in the compartment of the lateral pararectal space and medial paravesical space delimitates the entire lateral para-metrial DIE.

Endometriotic lesions located in posterior parametrium (utero-sacral ligaments) was excised after development of the medial pararectal spaces (*Fig. 2*). Development of medial and/or lateral pararectal spaces allows the operator to perform ureterolysis with identification of the ureter and umbilical arteries.

In order to prepare the resection of rectosigmoidian nodule (ENZIAN C) the medial pararectal space (Okabayashy) would be developed (*Fig. 3*).

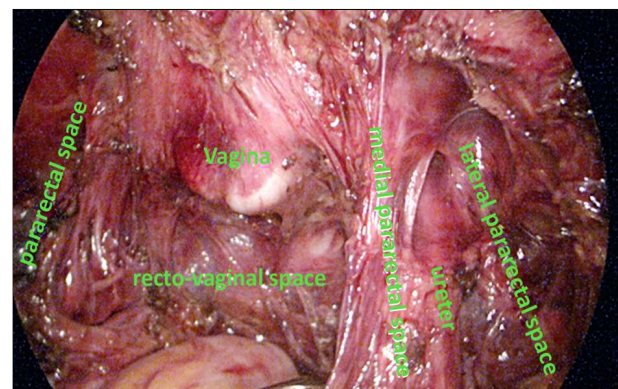


Figure 2. Dissection of the lateral and medial pararectal and rectovaginal space for B and C lesions.

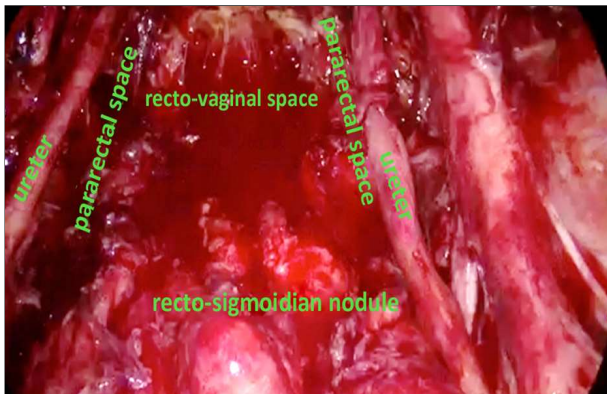


Figure 3. Dissection of medial pararectal and recto-vaginal space for C lesion

In deep endometriosis lesions located on rectovaginal septum (ENZIAN A) for complete resection “en bloc” with hysterectomy specimen, medial pararectal space (Okabayashy) would be developed. In cases of A or C endometriotic lesion dissection of rectovaginal spaces would be done deeply starting from medial to lateral, and from caudal to cranial direction.

The lesions located in the lateral and posterior para-metrium (B) associated with recto-sigmoidian lesion (C) need for excision development of lateral and medial pararectal spaces, ureterolysis, followed by recto-vaginal space dissection (*Fig. 3*).

Standardised Technique

Standardization of retroperitoneal hysterectomy depending on the ENZIAN score (*Fig. 4 to Fig. 8*) is described step by step as it follows:

B endometriotic lesions (Fig. 4)

1. Transection of the round ligament.
2. Identification and dissection of the lateral and/or medial pararectal space.
3. Ureterolysis.
4. Development of medial paravesical space.
5. Dissection of the vesicovaginal space.
6. Ligation of the superior vascular pedicle of the uterus.
7. Ligation of the uterine artery.
8. Colpotomy.

9. ‘En-bloc’ resection of the parametrial endometriosis nodule along with the uterus.

C endometriotic lesions (Fig. 5)

1. Transection of the round ligament.
2. Identification and dissection of the medial (Okabayashy) pararectal spaces.
3. Dissection of the rectovaginal space.
4. Ligation of the superior vascular pedicle of the uterus.
5. Ligation of the uterine artery.
6. Colpotomy.
7. Excision of the uterus.
8. Resection of the recto-sigmoidian endometriosis nodule.
 - C1 – rectal shaving.
 - C2, C3 – discoidal resection or recto-sigmoidian resection with end-to-end anastomosis.

A and C endometriotic lesions (Fig. 6)

1. Transection of the round ligament
2. Identification and dissection of the medial pararectal spaces.
3. Bilateral identification of the ureter.
4. Dissection of the rectovaginal space.
5. Ligation of the superior vascular pedicle of the uterus.
6. Ligation of the uterine artery.
7. Transection of the posterior vaginal wall in a manner that will include the entire vaginal lesion.
8. Excision of the uterus.
9. Resection of the recto-sigmoidian endometriosis nodule.
 - C1 – rectal shaving.
 - C2, C3 – discoidal resection or recto-sigmoidian resection with end-to-end anastomosis.

B and C endometriotic lesions (Fig. 7)

1. Transection of the round ligament.
2. Identification and dissection of the medial (Okabayashy) and lateral (Lazko) pararectal spaces.
3. Ureterolysis.
4. Development of medial paravesical space.

ENZIAN 2012

Classification of Deep Infiltrating Endometriosis (according to the Endometriosis Research Foundation SEF)

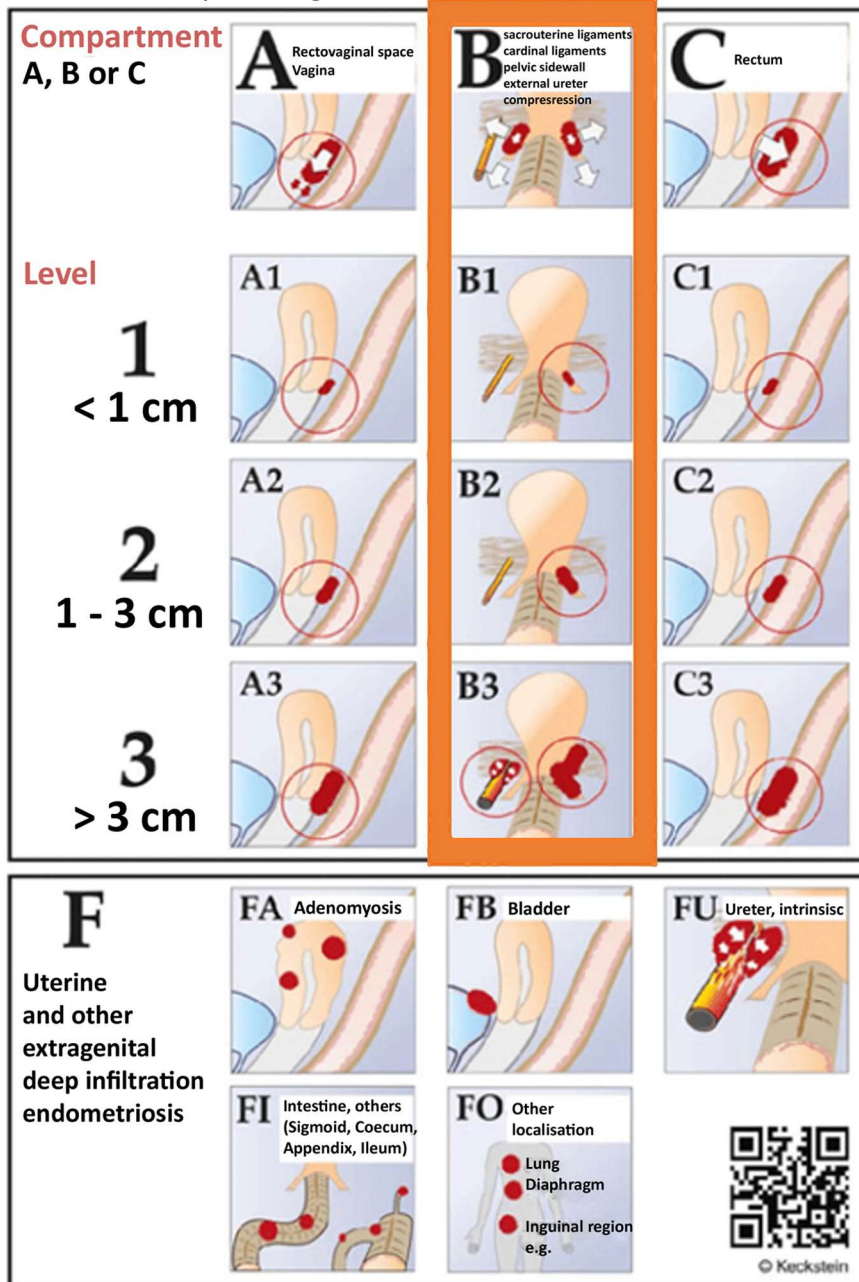


Figure 4. ENZIAN score. B lesions highlighted (Keckstein, 2012)

5. Dissection of the vesicovaginal space.
6. Dissection of the rectovaginal space.
7. Ligation of the superior vascular pedicle of the uterus.
8. Dissection and ligation of the uterine artery.
9. Colpotomy.
10. En-bloc' resection of the uterus along with nodules of the lateral parametrium and/or uterosacral ligaments.
11. Resection of the recto-sigmoidian endometriosis nodule.
 - C1 – rectal shaving.
 - C2, C3 – discoidal resection or recto-

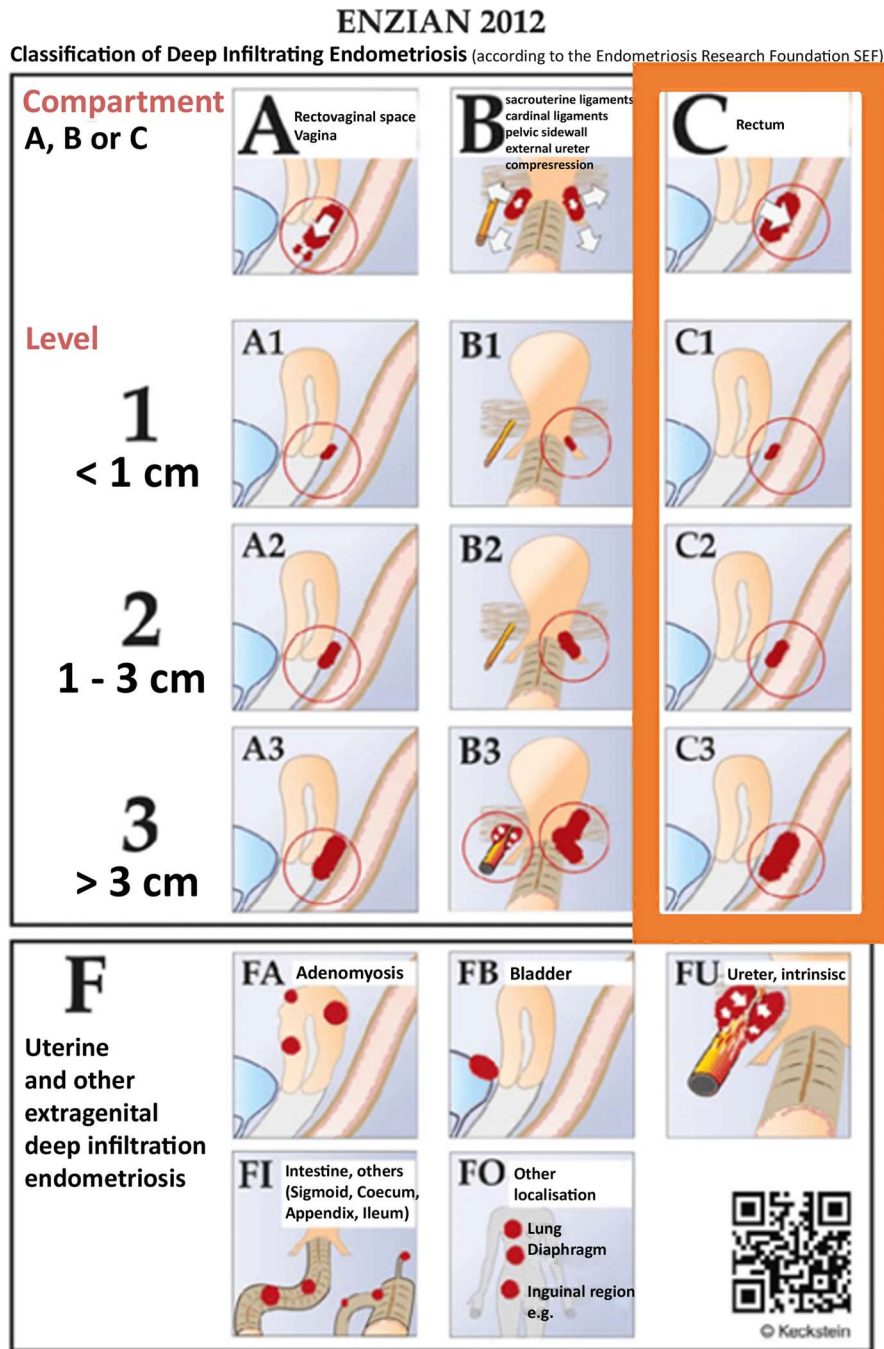


Figure 5. ENZIAN score. C lesions highlighted (Keckstein, 2012)

sigmoidian resection with end-to-end anastomosis.

A, B and C endometriotic lesions (Fig. 8)

1. Transection of the round ligament.
2. Identification and dissection of the medial

(Okabayashy) and lateral (Lazko) para-rectal spaces.

3. The identification of the umbilical arteries bilaterally and the ureter bilaterally - ureterolysis with the delimitation of the endometriosis nodule that must be excised.

ENZIAN 2012

Classification of Deep Infiltrating Endometriosis (according to the Endometriosis Research Foundation SEF)

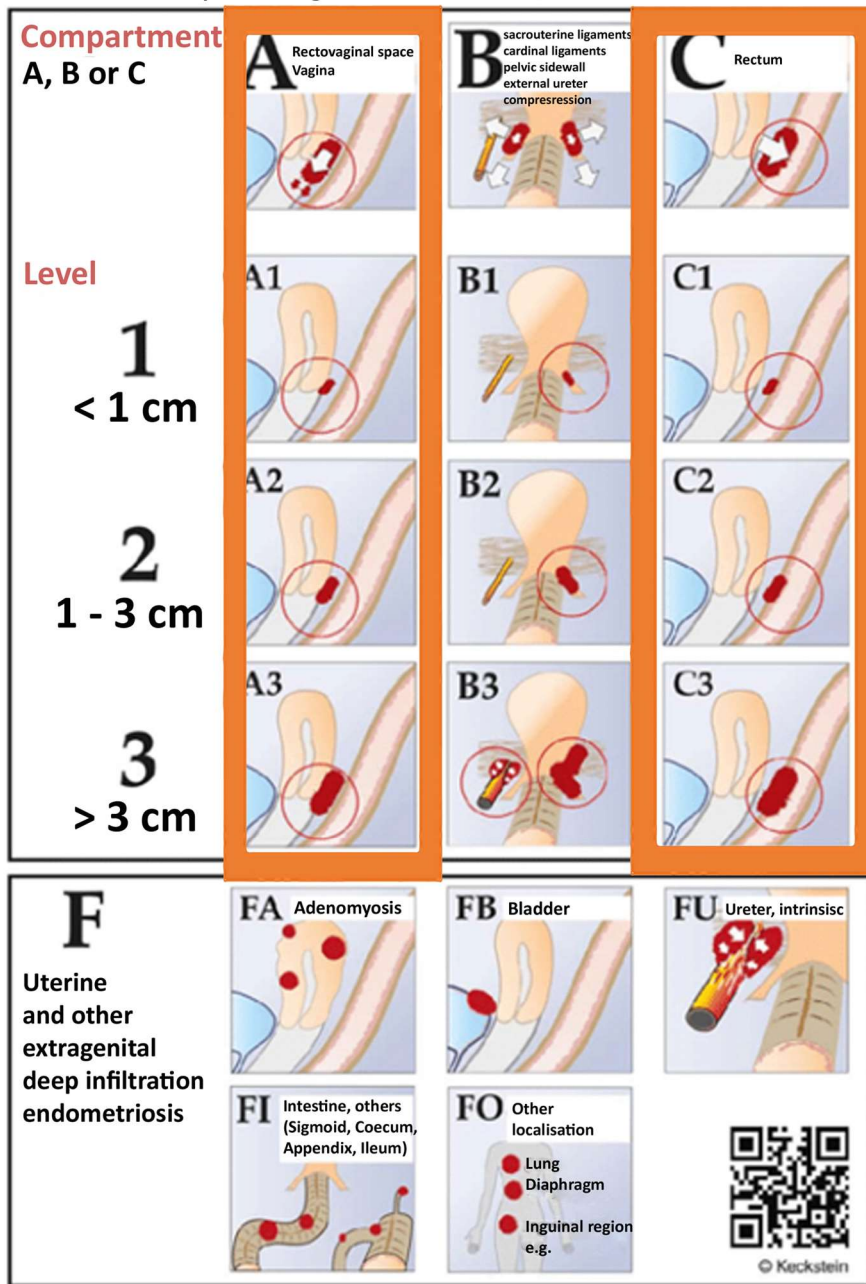


Figure 6. ENZIAN score. A and C lesions highlighted (Keckstein, 2012)

4. Dissection of the vesicovaginal space.
5. Ligation of the superior vascular pedicle of the uterus.
6. Dissection and ligation of the uterine artery.
7. Dissection of the rectovaginal space.
8. Resection of the posterior vaginal wall in a manner that will include the entire vaginal lesion.
9. Excision of the uterus.
10. Segmental resection of the recto-sigmoidian endometriosis nodules (2C or 3C).

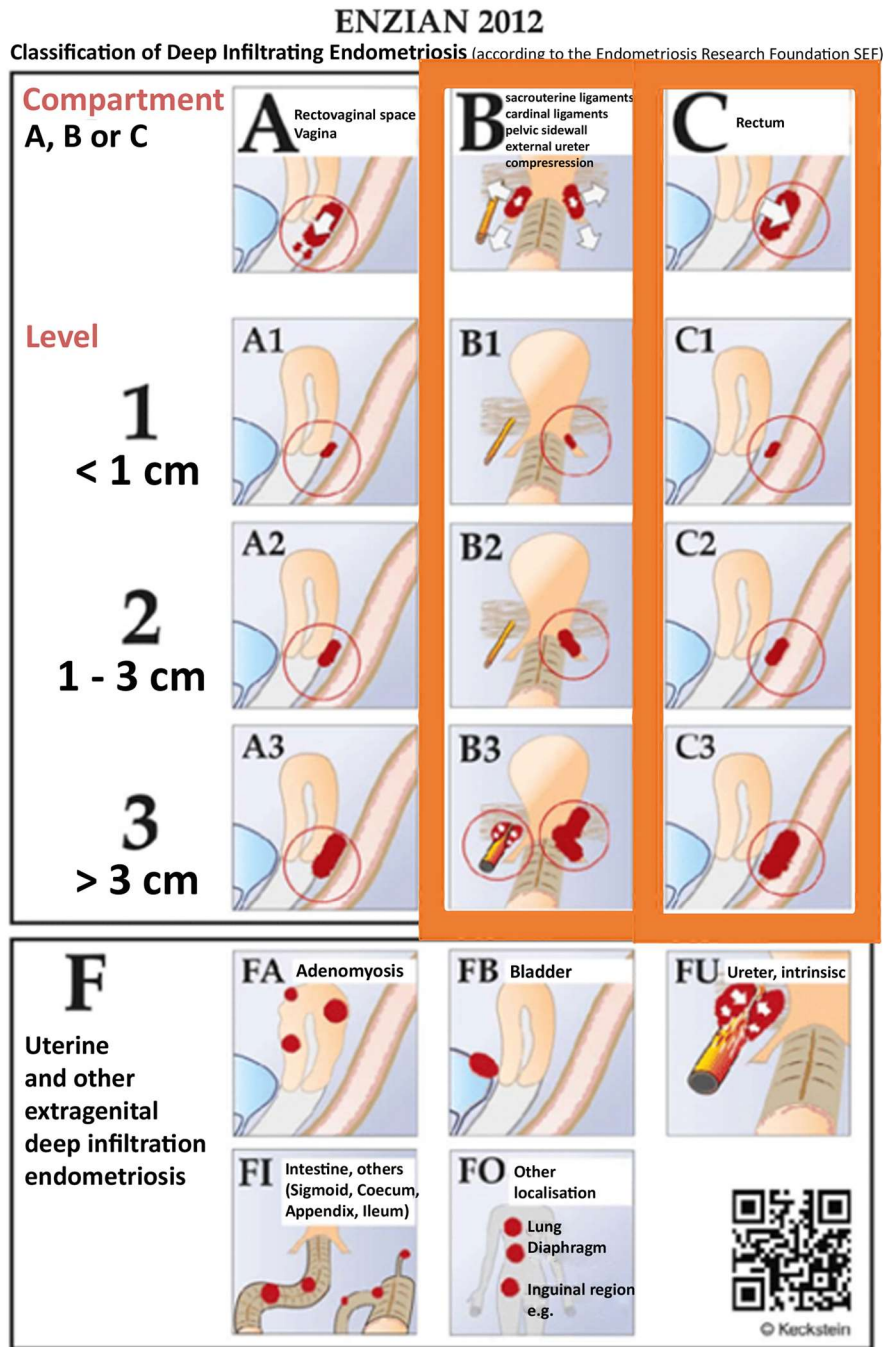


Figure 7. ENZIAN score. A, B and C lesions highlighted (Keckstein, 2012)

In 1C lesions, rectal shaving can be tried, leaving the remaining nodule on the part of the vagina that will be resected.

During follow-up evaluations, recurrence of pain symptoms that results from endometriosis never occurred, so there were no recurrences.

Combined clinical and ultrasound examination permitted the assessment of the recurrence during follow. Among patients who underwent robotic hysterectomy, no patient required a blood transfusion, and no women had voiding problems or other long-term complications. No

ENZIAN 2012

Classification of Deep Infiltrating Endometriosis (according to the Endometriosis Research Foundation SEF)

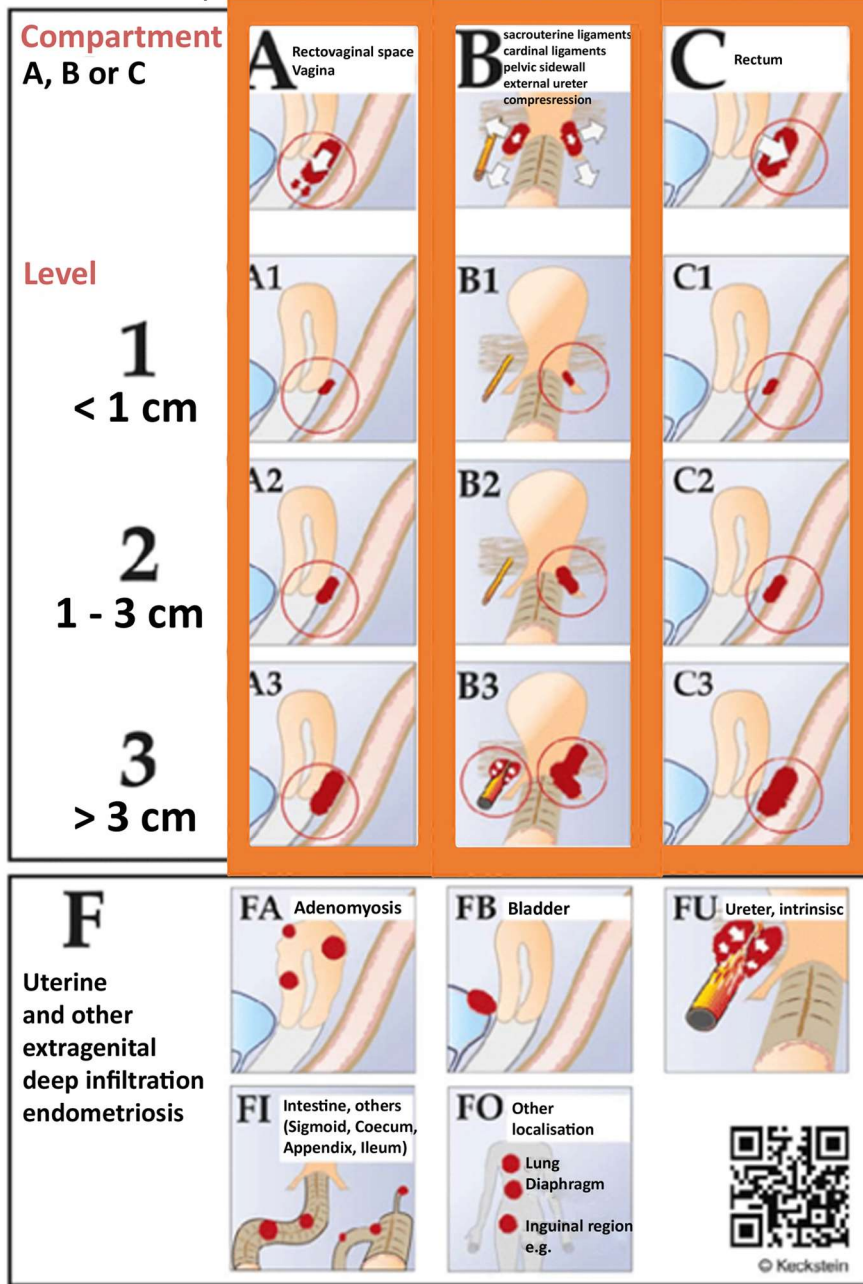


Figure 8. ENZIAN score. A, B and C lesions highlighted (Keckstein, 2012)

reoperation was necessary. Mean hospital stay was 3.62 days (\pm 1.18). The histopathologic exam confirmed in all cases that the excised nodules were endometriotic.

All patients presented preoperatively (Table 1) with dysmenorrhea (100%), 68

(83.9%) with dyspareunia and 59 (72.83%) with pelvic non menstrual pain. Regarding the pelvic non-menstrual pain 20 patients (71,4%) presented the aforementioned symptom. After 24 months after surgery, at the follow up, the number of patients who presented with

Table 3. Preoperative and postoperative comparison regarding pain symptoms.

	Pre-operative	24 months post operative	P value
Dysmenorrhea (mean±SD)	8.46 ± 1.16	2.08 ± 1.36	<0.001
Deep dyspareunia (mean±SD)	7.42 ± 1.07	2.22 ± 1.69	<0.001
Pelvic non menstrual pain (mean±SD)	6.87 ± 1.41	2.41 ± 1.59	<0.001

the symptoms described above was lower compared to preoperative numbers. Following surgery, there was a significant improvement ($p<0.05$) in dysmenorrhea, dyspareunia, chronic non-menstrual pelvic pain, as it can be observed in *Table 3*.

Discussion

Deep infiltrative endometriosis is the most challenging indication for hysterectomy, especially when it is recurrent. There are three options regarding hysterectomy in DIE: a) To excise the DIE lesion first, b) To perform hysterectomy first and subsequently address the nodule, and c) To remove the uterus and the disease 'en bloc' (11).

The hysterectomy alone doesn't solve the symptomatology of deep endometriosis, especially in premenopausal or postmenopausal HRT women (12,13).

The hysterectomy and parametrial dissection must be done according to the size and location of the endometriotic nodule. The strategy must be adapted according to ENZIAN classification and the operative technique standardized for every case. The goal of hysterectomy for DIE is to release the uterus and the endometriotic tissue without risks of complication.

We consider 'en-bloc' hysterectomy together with endometriotic nodule the best method. The blood loss, operative time, and intra-operative complications are reduced comparing with other methods. 'En-bloc' hysterectomy together with endometriotic nodule is a retrograde retroperitoneal hysterectomy where the dissection and parametrial resection is tailored depending on the location of deep endometriosis lesions.

In the pelvis there are four lateral virtually

compartments bilaterally and four virtually compartments on the antero-posterior axis (14). In endometriosis surgery we usually use three laterals virtual compartments - except for the lateral paravesical space which is a space of lymphadenectomy. We can consider paravesical and pararectal spaces as compartments of the same anatomic region rather than fascial spaces. Antero-posterior virtual compartments used more frequently are the vesico-vaginal and rectovaginal spaces. Presacral space is used in segmental recto-sigmoidian resection and retropubic space in some cases with large vesical nodules.

There are two hot points of dissection: parametrial development of anatomic spaces and rectovaginal dissection. Parametrial location of the endometriotic nodule poses the leading problems for radical excision and appropriate hysterectomy.

If the nodule is located in the lateral parametrium the development of paravesical and lateral pararectal space (Latzko) is necessary in order to facilitate the dissection. If the leading part of the nodule is located deep in the lateral parameter, the dissection will be done beginning from the medial pararectal space in order to identify the ureter and then continue in lateral pararectal space to delineate the entire lateral parametrial nodule. Unlike the uterosacral ligaments, the cardinal ligaments are structures difficult to define surgically due to their mesenteric structure. The only ligamentous part of cardinal ligaments is confused with that of the uterosacral and the lateral ligament of the rectum near their insertion on the cervix (15,16). Because the ligamentous part of the lateral parametrium is an anatomical part of the lateral ligament of the rectum, dissection of caudal located endometriotic lesion starts with dissection from

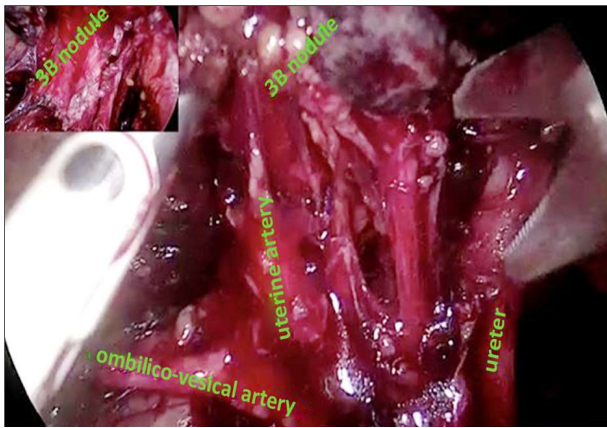


Figure 9. Parametrial nodule 3B - ligation of uterine artery at its origin

medial pararectal space into the lateral parametrium, under the level of the deep uterine vein.

The ureterolysis is necessary in all cases of parametrial involvement.

Depending on the size of the nodule, the uterine artery ligation at its origin is necessary for nodules larger than 3 cm (*Fig. 9*) and at the level of the ureter if the nodule is under 3 cm. In 3B lesions the dissection must respect a fine delimitation between the lateral parametrium and the bladder pillar, which doesn't require resection. Delimitation of the anterior parametrium from the lateral parametrium would be done anteriorly entering in medial paravesical spaces (17).

When addressing nodules located in posterior parametrium (utero-sacral ligaments), for nerve-sparing of the hypogastric and splanchnic nerves, the medial pararectal (Okabayashy) space requires to be developed (18,19). If the nodule belongs to the rectum, the dissection would be conducted from lateral to medial. Dissection and ligation of the uterine arteries first followed by rectovaginal dissection makes the approach easier because the dissection starts from lateral to medial and from caudal to cranial. These manoeuvres allow facilitating the hysterectomy by dissection of rectovaginal space.

The location of the endometriotic nodule in the bladder wall (FB) imposes firstly development of the medial paravesical space, dissec-

tion of the vesico-uterine space and then the excision of the nodule.

Pain recurrence may not relate to anatomic relapse of disease. Incomplete excision, ovarian conservation, and postoperative HRT are the most critical factors for postmenopausal recurrence of pain (20).

Most of the current guidelines state that the current gold standard for the treatment of endometriosis and rarely mention robotic surgery as a feasible alternative (21-27). In a recent meta-analysis published by Restaino et al published in 2020 mentioned no significant differences in perioperative outcomes regarding the comparison between laparoscopy and robotic surgery (28). Due to the fact that we have seen good results with robotic platform even in cases with stage IV ASRM and DIE we consider that this could be a step forward to extend the indications for robotic surgery. This could also represent the setting for further research into the field of endometriosis and robotic surgery.

The robotic platform offers a significant advantage in cases with deep infiltrating endometriosis. Enhanced visualisation of the endometriotic lesions is required in order to achieve complete excision and preserve the nerve structures. We must take into account the fact that the majority of patients that have an indication for hysterectomy associated with deep infiltrating endometriosis are in stage III and IV. This aspect is in accordance with data in the literature described by Bedaiwy et al which present a low intraoperative blood loss and a low perioperative complication rate (13).

Conclusion

The hysterectomy in patients with DIE has two goals: to remove the uterus and the complete excision of endometriotic tissue without major complications. The strategy may be individualized for each case and can be standardized taking into account the ENZIAN classification. The necessity to standardize the hysterectomy in DIE results from the need to solve without major complications various anatomical situations

generated by different localizations of endometriosis nodules.

Conflicts of Interests

The authors declared no potential conflicts of interest.

References

- Aarts JW, Nieboer TE, Johnson N, Tavender E, Garry R, Mol BW, et al. Surgical approach to hysterectomy for benign gynaecological disease. *Cochrane Database Syst Rev*. 2015;2015(8):CD003677.
- Solnik MJ, Munro MG. Indications and alternatives to hysterectomy. *Clin Obstet Gynecol*. 2014;57(1):14-42.
- MacDonald SR, Klock SC, Milad MP. Long-term outcome of nonconservative surgery (hysterectomy) for endometriosis-associated pain in women <30 years old. *Am J Obstet Gynecol*. 1999;180(6 Pt 1):1360-3.
- Chalermchockchareonkit A, Tekasakul P, Chaisilwattana P, Sirimai K, Wahab N. Laparoscopic hysterectomy versus abdominal hysterectomy for severe pelvic endometriosis. *Int J Gynaecol Obstet*. 2012;116(2):109-11.
- Alboni C, Farulla A, Facchinetti F, Ercoli A. Robot-assisted nerve-sparing resection of bilateral parametrial deep infiltrating endometriosis. *J Minim Invasive Gynecol*. 2021;28(1):18-19.
- Namnoum AB, Hickman TN, Goodman SB, Gehlbach DL, Rock JA. Incidence of symptom recurrence after hysterectomy for endometriosis. *Fertil Steril*. 1995;64(5):898-902.
- Kiran A, Hilton P, Cromwell DA. The risk of ureteric injury associated with hysterectomy: a 10-year retrospective cohort study. *BJOG*. 2016;123(7):1184-91.
- Uccella S, Marconi N, Casarin J, Ceccaroni M, Boni L, Sturla D, et al. Impact of endometriosis on surgical outcomes and complications of total laparoscopic hysterectomy. *Arch Gynecol Obstet*. 2016;294(4):771-8.
- Truong M, Kim JH, Scheib S, Patzkowsky K. Advantages of robotics in benign gynecologic surgery. *Curr Opin Obstet Gynecol*. 2016;28(4):304-10.
- Tuttles F, Keckstein J, Ulrich U, Possover M, Schweppe KW, Wustlich M, et al. ENZIAN-score, a classification of deep infiltrating endometriosis. *Zentralbl Gynakol*. 2005;127(5):275-81. German
- Rizk B, Fischer AS, Lotfy HA, Turki R, Zahed HA, Malik R, et al. Recurrence of endometriosis after hysterectomy. *Facts Views Vis Obgyn*. 2014;6(4):219-27.
- Clayton RD, Hawe JA, Love JC, Wilkinson N, Garry R. Recurrent pain after hysterectomy and bilateral salpingo-oophorectomy for endometriosis: evaluation of laparoscopic excision of residual endometriosis. *Br J Obstet Gynaecol*. 1999;106(7):740-4.
- Sandström, A, Bixo, M, Johansson, M, Bäckström, T, Turkmen, S. Effect of hysterectomy on pain in women with endometriosis: a population-based registry study. *BJOG*. 2020;127(13):1628-1635.
- Yabuki Y, Sasaki H, Hatakeyama N, Murakami G. Discrepancies between classic anatomy and modern gynecologic surgery on pelvic connective tissue structure: Harmonization of those concepts by collaborative cadaver dissection. *Am J Obstet Gynecol*. 2005;193(1):7-15.
- Kato T, Murakami G, Yabuki Y. Does the cardinal ligament of the uterus contain a nerve that should be preserved in radical hysterectomy? *Anat Sci Int*. 2002;77(3):161-8.
- Fujii S, Takakura K, Matsumura N, Higuchi T, Yura S, Mandai M, et al. Anatomic identification and functional outcomes of the nerve sparing Okabayashi radical hysterectomy. *Gynecol Oncol*. 2007;107(1):4-13.
- Yabuki Y, Asamoto A, Hoshiba T, Nishimoto H, Nishikawa Y, Nakajima T. Radical hysterectomy: an anatomic evaluation of parametrial dissection. *Gynecol Oncol*. 2000;77(1):155-63.
- Nezhat C, Nguyen K, Ackroyd E, Roman RA, Rambhatla A, Nezhat A, et al. Nerve-Sparing Modified Radical Hysterectomy for Severe Endometriosis and Complex Pelvic Pathology. *Cureus*. 2020;12(8):e9882.
- Hopkins MP, Schnettler W. Anatomic identification and functional outcomes of the nerve sparing Okabayashi radical hysterectomy. *Gynecol Oncol*. 2007;107(1):2-3.
- Borghese B, Santulli P, Streuli I, Lafay-Pillet MC, de Ziegler D, Chapron C. Recurrence of pain after surgery for deeply infiltrating endometriosis: How does it happen? How to manage? *J Gynecol Obstet Biol Reprod (Paris)*. 2014;43(1):12-8.
- Ulrich U, Buchweitz O, Greb R, Keckstein J, von Leffern I, Oppelt P, et al. National German Guideline (S2k): Guideline for the Diagnosis and Treatment of Endometriosis: Long Version - AWMF Registry No. 015-045. *Geburtshilfe Frauenheilkd*. 2014;74(12):1104-1118.
- Corrections to: "SOGC Clinical Practice Gynaecology Committee. Endometriosis: diagnosis and management. SOGC Clinical Practice Guideline No. 244, July 2010. *J Obstet Gynaecol Can* 2010;32(Suppl): S1-S33.
- Practice bulletin no. 114: management of endometriosis. *Obstet Gynecol*. 2010;116(1):223-36.
- Practice Committee of the American Society for Reproductive M. Endometriosis and infertility: a committee opinion. *Fertil Steril*. 2012;98(3):591-8.
- Practice Committee of the American Society for Reproductive M. Treatment of pelvic pain associated with endometriosis: a committee opinion. *Fertil Steril*. 2014;101(4):927-35.
- Diagnosis and management of endometriosis: summary of NICE guidance. *BMJ*. 2017;358:j4227.
- Dunselman GA, Vermeulen N, Becker C, Calhaz-Jorge C, D'Hooghe T, De Bie B, et al. ESHRE guideline: management of women with endometriosis. *Hum Reprod*. 2014;29(3):400-12.
- Restaino S, Mereu L, Finelli A, Spina MR, Marini G, Catena U, et al. Robotic surgery vs laparoscopic surgery in patients with diagnosis of endometriosis: a systematic review and meta-analysis. *J Robot Surg*. 2020;14(5):687-694.